



## Case report

## Pyomyositis of the inner thigh muscles due to *Escherichia coli* in a young patient with severe aplastic anemia

Angel Masferrer-Pino<sup>a,\*</sup>, Jose Maria Cavanilles-Walker<sup>a</sup>, Alejandro Olive-Marques<sup>b</sup>

<sup>a</sup> Servicio de Cirugía Ortopédica y Traumatología, Hospital Universitari Germans Trias i Pujol, Badalona, Barcelona, Spain

<sup>b</sup> Servicio de Reumatología, Hospital Universitari Germans Trias i Pujol, Badalona, Barcelona, Spain

## ARTICLE INFO

## Article history:

Received 10 October 2012

Accepted 5 January 2013

Available online 3 April 2013

## Keywords:

Pyomyositis

*Escherichia coli*

Aplastic anemia

## ABSTRACT

Pyomyositis, an acute bacterial infection of skeletal muscle, is caused by *Staphylococcus aureus* or other gram-positive organisms in >90% of cases. A 19-year-old boy with severe idiopathic aplastic anemia presented a pyomyositis of inner thigh muscles due to *Escherichia coli* as a complication of his underlying disease. The diagnosis was established by means of soft tissue ultrasound, magnetic resonance imaging (MRI) and blood culture. Surgical debridement and antibiotic treatment were performed. Postoperative course was uneventful and pyomyositis was successfully resolved. Pyomyositis caused by *E. coli* is uncommon condition, and very few cases have been reported, most of them being severe immunodeficiency patients, but we should know the existence of this entity and its management.

© 2012 Elsevier España, S.L. All rights reserved.

### Piomiositis del muslo debida a *Escherichia coli* en un paciente joven con anemia aplásica

## RESUMEN

La piomiositis es una infección bacteriana aguda del músculo esquelético que es causada por *Staphylococcus aureus* u otros organismos gram positivos en >90% de los casos. Presentamos el caso de un hombre de 19 años de edad con anemia aplásica idiopática severa quien presentó una piomiositis de los músculos internos del muslo debido a *Escherichia coli* como una complicación de su enfermedad de base. El diagnóstico se estableció por medio de ultrasonidos de tejido blando, resonancia magnética (RM) y hemocultivo. Se llevaron a cabo desbridamiento quirúrgico y tratamiento antibiótico. El postoperatorio transcurrió sin complicaciones y la piomiositis se resolvió con éxito. La piomiositis causada por *E. coli* es una condición poco común, y muy pocos casos han sido reportados, la mayoría de ellos son pacientes con inmunodeficiencia grave, pero debemos conocer la existencia de esta entidad y su tratamiento.

© 2012 Elsevier España, S.L. Todos los derechos reservados.

## Palabras clave:

Piomiositis

*Escherichia coli*

Anemia aplásica

## Introduction

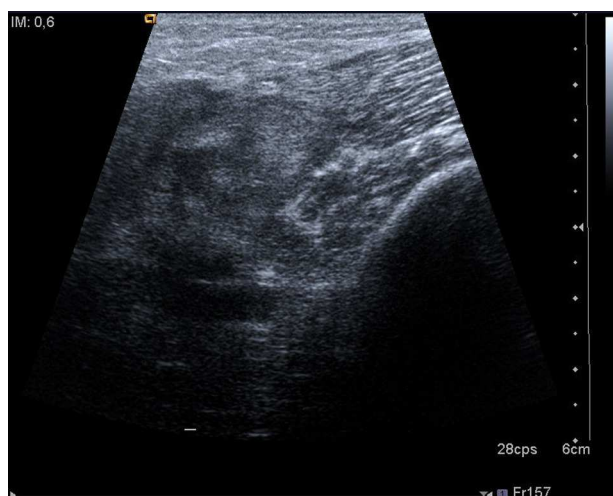
Pyomyositis is an acute bacterial infection of skeletal muscle that can affect the general population in tropical climates or immunocompromised patients in general. Although it can occur at any age, it is more common in tropical climates affecting children 5–9 years and young adults, and in temperate climates, adults between 20 and 40 years. By gender ratio is 2–3/1 in favor of males. Its incidence is increasing in Western countries, especially in patients with chronic debilitating diseases such as diabetes

mellitus, hematological diseases, connective and HIV infection. *Staphylococcus aureus* or other gram-positive organisms are the causative agents in more than 90% of cases. Pyomyositis due to *Escherichia coli* is an unusual condition.<sup>1,2</sup>

Pyomyositis usually begins with a very subtle clinical presentation thus being difficult to diagnose in early stages. The initial symptoms are diffuse crampy pain and tenderness on the involved area, usually followed by edema, low-grade fever and leukocytosis depending on the underlying disease the patient may have.<sup>2</sup> Nowadays, MRI is the most reliable study to make a diagnosis of pyomyositis.<sup>3</sup> First-line treatment consists of draining the abscess, if any, by surgery or percutaneous puncture guided by ultrasound or CT and intravenous antibiotic treatment.<sup>4</sup> Herein we present a case of pyomyositis induced by *E. coli*.

\* Corresponding author.

E-mail address: [angel.masferrer@gmail.com](mailto:angel.masferrer@gmail.com) (A. Masferrer-Pino).



**Fig. 1.** A soft tissue ultrasound revealed a dysfunctional muscle area in relation with the vastus medialis of quadriceps and the adductors muscles.

### Clinical observation

A 19 year-old boy with severe idiopathic aplastic anemia diagnosed when he was 7 (with history of bleeding and pulmonary infection, treated with transfusions and antibiotics respectively, and outstanding bone marrow transplant) was admitted to the pediatric department after he came to the emergency department of our hospital presenting fever and a painful, erithematous and indurated skin area located on the inner left thigh, of 48 h of evolution. The blood exam showed  $200 \times 10^9/l$  leukocytes and C-reactive protein of 390 mg/dL and axillary temperature was  $37.5^\circ\text{C}$ .

Empirical treatment with iv cefepime (6 g/d) and iv amikacin (15 mg/kg/d) was immediately started being changed four days later after blood cultures were positive for *E. coli*. According to the antibiogram, treatment was changed to cefuroxime (4.5 g/d) and amikacin (15 mg/kg/d) during three weeks.

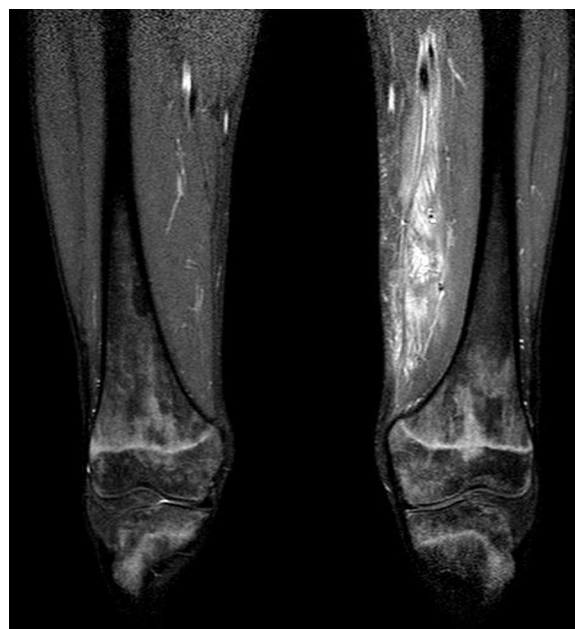After three days of treatment, the patient persisted with the same symptoms showing no improvement. A soft tissue ultrasound revealed a dysfunctional muscle area in relation with the vastus medialis of quadriceps and the adductors muscles compatible with pyomyositis (Fig. 1). A MRI study confirmed the diagnosis (Fig. 2). Consequently, our department was consulted in order to consider surgical debridement. Finally he was taken to surgery performing a complete debridement and drainage of the muscle injury. Samples were collected and sent for microbiological study, identifying an infection due to *E. coli* as the causative agent.

After i.v. antibiotic treatment for 3 weeks and surgical debridement, the patient recovered satisfactorily and there were no problems in the healing process or post-surgical infections around the surgical wound. Leucocytes rose to  $600 \times 10^9/l$  and C-reactive protein descended until 140 mg/dL. Nowadays, the episode of pyomyositis is totally resolved.

### Discussion

Up to the date, only 20 cases of *E. coli* pyomyositis have been reported, most of them involving patients with different causes of immunodeficiencies such as AIDS and other hematologic malignancies related or not with previous chemotherapy.<sup>5–16</sup> However, this one is only the second patient with idiopathic severe aplastic anemia reported presenting pyomyositis due to *E. coli*.

When pyomyositis occurs in immunocompromised patients, as in the case reported here, we may have doubts about the convenience of surgical debridement because of fear of well known



**Fig. 2.** The MRI study revealed the suspected pyomyositis.

complications described in this type of patients such as postoperative local infections or healing problems around the surgical wound.<sup>17–19</sup> However, an early diagnosis, surgical debridement with complete drainage of the purulent material, together with antibiotic therapy, eradicates the infection in most patients.<sup>20,21</sup>

Although an initial antibiotic therapy for pyomyositis should include a broad-spectrum agent with good *S. aureus* coverage (can be modified based on antibiogram), coverage of gram-negative as *E. coli*, is advised to be empirically included in the treatment of immunocompromised patients.<sup>2</sup>

We report a further case of pyomyositis due to *E. coli* in an immunocompromised patient, only the second one associated to severe idiopathic aplastic anemia.

### Conclusions

Pyomyositis caused by *E. coli* is uncommon condition, and very few cases have been reported, most of them being severe immunodeficiency patients, but we should know the existence of this entity and its management. Although the pyomyositis is rare in our country, should be included in the differential diagnosis of patients presenting with fever, muscle pain and loss of function, especially in relation to chronic debilitating diseases and in subjects performing intense muscular exercise.<sup>22</sup> Despite being a rare cause, we must include gram negative antibiotic for empirical therapy and surgical treatment, whenever possible, regardless of the fear of possible postoperative problems (infection and/or wound healing) when dealing with immunocompromised patients.

### Ethical disclosures

**Protection of human and animal subjects.** The authors declare that no experiments were performed on humans or animals for this investigation.

**Confidentiality of data.** The authors declare that they have followed the protocols of their work centre on the publication of patient data and that all the patients included in the study have received sufficient information and have given their informed consent in writing to participate in that study.

**Right to privacy and informed consent.** The authors have obtained the informed consent of the patients and/or subjects mentioned in the article. The author for correspondence is in possession of this document.

### Conflict of interest

The authors declare no conflict of interest.

### References

- Vigil KJ, Johnson JR, Johnston BD, Kontoyiannis DP, Mulanovich VE, Raad II, et al. *Escherichia coli* pyomyositis: an emerging infectious disease among patients with hematologic malignancies. *Clin Infect Dis*. 2010;50:374–80.
- Chiu SK, Chang FY. Pyomyositis caused by extended-spectrum beta-lactamase-producing *Escherichia coli* in a patient with acute myeloid leukemia. *Int J Infect Dis*. 2009;13:e85–7.
- Yuh WTC, Schreiber AE, Montgomery WJ, Ehara S. Magnetic resonance imaging of pyomyositis. *Skeletal Radiol*. 1988;17:190–3.
- Hossain A, Reis ED, Soundararajan K, Kerstein M, Hollier LH. Nontropical pyomyositis: analysis of eight patients in an urban center. *Am Surg*. 2000;66:1064–6.
- Hall RL, Callaghan JJ, Moloney E, Martinez S, Harrelson JM. Pyomyositis in a temperated climate presentation, diagnosis and treatment. *J Bone Joint Surg Am*. 1990;72:1240–4.
- Vilades C, Garcia-Queralt R, Rivas I, Vidal F, Richart C. Pyomyositis due to *Escherichia coli* in a patient infected by HIV. *Br J Rheumatol*. 1994;33:404–5.
- Barbot R, Morand C, Skopinski S, Albisson E, Portron Y, Coutant G. Pyomyositis of adductor muscles caused by *Escherichia coli* in an immunocompetent patient living in a temperate climat. *Rev Med Interne*. 2010;31:e9–12.
- Cone LA, Lamb RB, Graff-Radford A, Rudder J, Bach SA, Hirschberg JA, et al. Pyomyositis of the anterior tibial compartment. *Clin Infect Dis*. 1997;25:146–8.
- Tumeh SS, Butler GJ, Maguire JH, Nagel JS. Pyogenic myositis: CT evaluation. *J Comput Assist Tomogr*. 1988;12:1002–5.
- Jou IM, Chiu NT, Yang CY, Lai KA. Pyomyositis—with special reference to the comparison between extra—and intrapelvic muscle abscess. *Southeast Asian J Trop Med Public Health*. 1998;29:835–40.
- Brook I, Frazier E. Aerobic and anaerobic microbiology of pyomyositis. *Infect Dis Clin Pract*. 1999;8:252–6.
- Lortholary O, Jehl F, Petitjean O, Cohen P, Tarral E, Guillevin L. Polymicrobial pyomyositis and bacteremia in a patient with AIDS. *Clin Infect Dis*. 1994;19:552–3.
- Johnson JR, Gajewski A, Lesse AJ, Russo TA. Extraintestinal pathogenic *Escherichia coli* as a cause of invasive nonurinary infections. *J Clin Microbiol*. 2003;41:5798–802.
- Tavil B, Aksu T, Çulha V, Yarali N, Tunç B. Staphylococcal pyomyositis in a child with Fanconi aplastic anemia. *Pediatr Hematol Oncol*. 2011;28:447–50.
- Mitsuyasu R, Gale RP. Bacterial pyomyositis in a patient with aplastic anaemia. *Postgrad Med J*. 1980;56:61–2.
- Van Nielen D, Taggart JL. A case of pyomyositis due to *Escherichia coli* in a 14-year-old with aplastic anemia. *Clin Pediatr (Phila)*. 2012;51:288–90.
- Cherif H, Kronvall G, Bjorkholm M, Kalin M. Bacteraemia in hospitalized patients with malignant blood disorders: a retrospective study of causative agents and their resistance profiles during a 14-year period without antibacterial prophylaxis. *Hematol J*. 2003;4:420–6.
- Madani TA. Clinical infections and bloodstream isolates associated with fever in patients undergoing chemotherapy for acute myeloid leukemia. *Infection*. 2000;28:367–73.
- Apostolopoulou E, Raftopoulos V, Terzis K, Elefsiniotis I. Infection Probability Score, APACHE II and KARNOFSKY scoring systems as predictors of bloodstream infection onset in hematology–oncology patients. *BMC Infect Dis*. 2010;26:135.
- Bickels J, Ben-Sira L, Kessler A, Wientroub S. Primary pyomyositis. *J Bone Joint Surg Am*. 2002;84-A:2277–86.
- Crum NF. Bacterial pyomyositis in the United States. *Am J Med*. 2004;117:420–8.
- Rodas G, Pedret C, Pruna R, Til L, Garau J, Salmeron J. Apunts Med Esport. 2009;162:82–5.