




Sociedad Española
de Reumatología -
Colegio Mexicano
de Reumatología

Reumatología Clínica

www.reumatologiaclinica.org



Images in Clinical Rheumatology

Structural damage to the hip in systemic juvenile idiopathic arthritis: A case of regression with Anakinra



Daño estructural de la cadera en la artritis idiopática juvenil sistémica: un caso de regresión con Anakinra

Francisca Aguiar^{a,*}, Iva Brito^{a,b}

^a Rheumatology Department, Centro Hospitalar São João, Porto, Portugal

^b Faculty of Medicine of Porto University, Porto, Portugal

ARTICLE INFO

Article history:

Received 24 October 2015

Accepted 30 December 2015

Available online 9 February 2016

Clinical case

A 15 years old caucasian girl was diagnosed with systemic juvenile idiopathic arthritis (sJIA) by the age of four and was initially treated with nonsteroidal anti-inflammatory drugs and oral corticosteroids (prednisolone 1 mg/kg/day). Although there was some clinical improvement, the disease progressed with 1–2 articular and systemic exacerbations a year and, in the beginning of the year 2007, when she was 7 years old, she started weekly methotrexate (10 mg/m²).

Despite methotrexate treatment escalation (up to 25 mg/m²/week subcutaneously) the patient had persistent disease activity and developed severe left coxitis (Fig. 1) in the beginning of 2009, which did not respond to ultrasound guided joint injection with triamcinolone hexacetonide. Due to the persistence of arthritis and elevated inflammatory markers she was started on Anakinra (1 mg/kg/day) in July 2009.

Since then there has been sustained improvement with resolution of clinical symptoms, including complete imagiological regression of coxitis (Fig. 2), which allowed discontinuation of

methotrexate and corticosteroids. The patient is in clinical remission on medication with Anakinra 100 mg/day (2–2.5 mg/kg/day) since 2011.

Discussion

sJIA is an autoinflammatory rheumatologic disease that accounts for 5–10% of all patients classified as JIA.¹ Hip involvement in sJIA is relatively common and is a cause of significant functional impairment and a marker of poor prognosis.^{2,3} A significant number of patients with sJIA has persistent disease despite the treatments used.

Anakinra is a recombinant form of human IL-1 receptor antagonist (IL-1Ra) that is recommended as first line disease-modifying therapy in sJIA selected patients and in refractory disease.⁴ In this case, the authors report the therapeutic success with Anakinra in a patient with refractory systemic and articular disease, emphasizing the regression of structural damage of the hip joint, which is rarely reported in these cases.

* Corresponding author.

E-mail address: francisca.ra@hotmail.com (F. Aguiar).

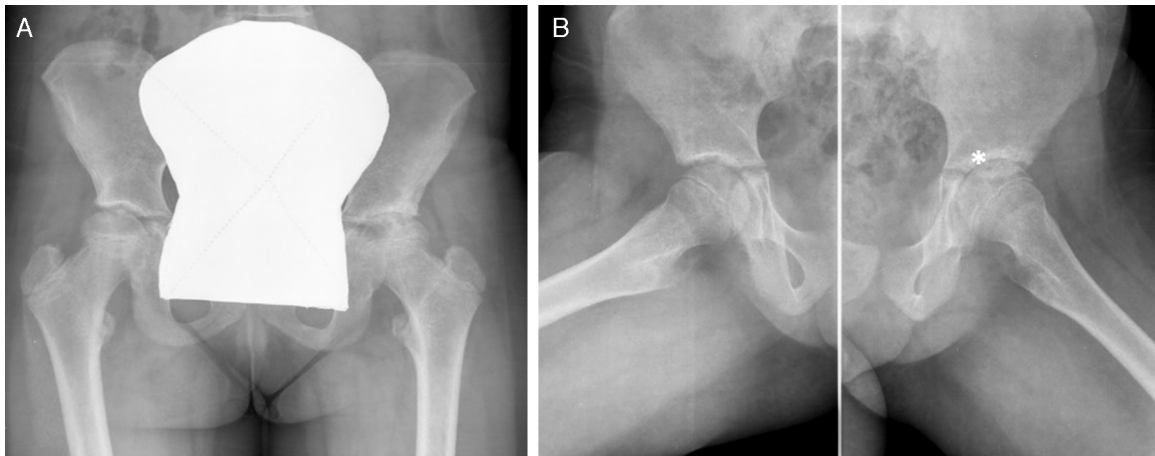


Fig. 1. Anteroposterior (Panel A) and frog-leg lateral (Panel B) radiographs of the pelvis showing left hip joint space narrowing, subchondral cysts of the left femoral head and acetabular sclerosis (*).

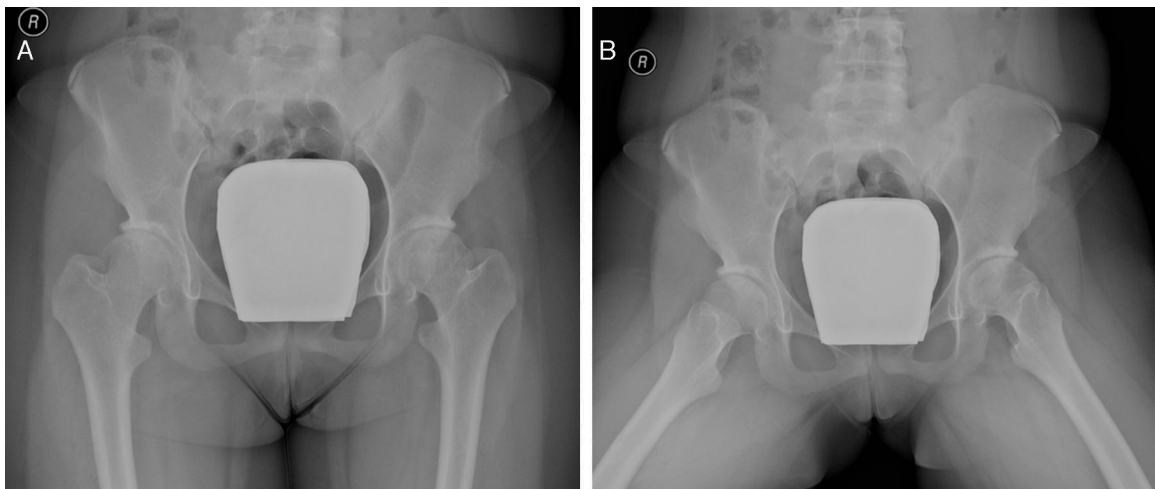


Fig. 2. Anteroposterior (Panel A) and frog-leg lateral (Panel B) radiographs of the pelvis showing normal left hip joint space with discrete acetabular sclerosis.

Conflict of interest

The authors declare that there are no conflicts of interest.

Ethical disclosures

Protection of human and animal subjects. The authors declare that no experiments were performed on humans or animals for this study.

Confidentiality of data. The authors declare that no patient data appear in this article.

Right to privacy and informed consent. The authors declare that no patient data appears in this article.

References

1. Gowdie PJ, Tse SM. Juvenile idiopathic arthritis. *Pediatr Clin N Am.* 2012;59:301–27.
2. Bekkering WP, ten Cate R, Suijlekom-Smit LW, Mul D, van der Velde EA, van den Ende CH. The relationship between impairments in joint function and disabilities in independent function in children with systemic juvenile idiopathic arthritis. *J Rheumatol.* 2001;28:1099–105.
3. Modesto C, Woo P, García-Consuegra J, Merino R, Gracia-Granero M, Arnal C, et al. Systemic onset juvenile chronic arthritis, polyarticular pattern and hip involvement as markers for a bad prognosis. *Clin Exp Rheumatol.* 2001;19:211–7.
4. Ringold S, Weiss PF, Beukelman T, Dewitt EM, Ilowite NT, Kimura Y, et al. Update of the 2011 American College of Rheumatology recommendations for the treatment of juvenile idiopathic arthritis: recommendations for the medical therapy of children with systemic juvenile idiopathic arthritis and tuberculosis screening among children receiving biologic medications. *Arthritis Rheum.* 2013;65:2499–512.