

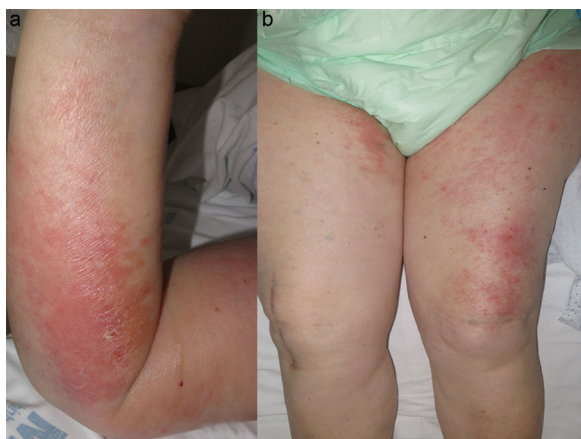Figura 1. a: Placa eritematoedematosa con vesiculoampollas en superficie en miembro superior derecho. b. Edema y placas eritematoedematosas en los muslos.

tosa y vesiculoampollosa, podrían ser la misma manifestación o solaparse. Tampoco la distribución indica una causa mecánica y existen casos similares con intenso edema sobre el que aparece el despegamiento^{5–7}.

La causa de la hipoalbuminemia del primer caso se debe al estado proinflamatorio de la enfermedad pulmonar intersticial y la DM aún no diagnosticada^{8,9}. Esta hipoalbuminemia podría ser causa de edema generalizado, pero no de placas eritematoedematosas y vesiculoampollosas.

La literatura muestra que la DM edematosa podría estar asociada a miopatía más grave y disfagia, dato que ocurre en nuestros pacientes^{1–3}. Asimismo, la DM vesiculoampollosa estaría fuertemente asociada a neoplasia y peor pronóstico^{6,10}. El edema extrafacial en DM, en cualquiera de sus variantes, debería alertar de una mayor gravedad y llevar a una búsqueda activa de neoplasia.

Bibliografía

- Milisenda JC, Doti PI, Prieto-González S, Grau JM. Dermatomyositis presenting with severe subcutaneous edema: Five additional cases and review of the literature. *Semin Arthritis Rheum.* 2014;44:228–33.
- Goussot R, Wettlé C, le Coz C, Cribier B, Lipsker D. Severe edematous dermatomyositis. *Ann Dermatol Venereol.* 2016;143:202–9.
- Chai Y, Bertorini TE, Li YD, Mitchell C, Guan H. Limb edema and anasarca associated with severe dermatomyositis: Report of four cases. *Neuromuscul Disord.* 2011;21:439–42.
- Jung KD, Kim PS, Park HY, Kim CR, Byun JY, Lee DY, et al. Dermatomyositis associated with generalized subcutaneous edema and Evans syndrome. *J Am Acad Dermatol.* 2012;66:144–7.
- Watanabe M, Natsuga K, Arita K, Abe R, Shimizu H. Generalized acute subcutaneous edema as a rare cutaneous manifestation of severe dermatomyositis. *J Eur Acad Dermatol Venereol.* 2016;30:e151–2.
- Mitsuya J, Hara H, Hattori A, Matsunaga A, Terui T. Vesicle formation in dermatomyositis associated with colon carcinoma. *Clin Exp Dermatol.* 2009;34:e221–2.
- Nishigori K, Yamamoto T, Yokozeki H. Vesiculo-bullous dermatomyositis: Report of three cases. *Dermatol Online J.* 2009;15:6.
- Bohan A, Peter JB. Polymyositis and dermatomyositis (first of two parts). *N Engl J Med.* 1975;292:344–7.
- Bohan A, Peter JB. Polymyositis and dermatomyositis (second of two parts). *N Engl J Med.* 1975;292:403–7.
- Kubo M, Sato S, Kitahara H, Tsuchida T, Tamaki K. Vesicle formation in dermatomyositis associated with gynecologic malignancies. *J Am Acad Dermatol.* 1996;34:391–4.

Belén Lozano-Masdemont^{a,*}, Ana Pulido-Pérez^a,
Verónica Parra-Blanco^b y José Antonio Avilés-Izquierdo^a

^a Servicio de Dermatología, Hospital General Universitario Gregorio Marañón, Madrid, España

^b Servicio de Anatomía Patológica, Hospital General Universitario Gregorio Marañón, Madrid, España

* Autor para correspondencia.

Correo electrónico: belenmasdemont@gmail.com
(B. Lozano-Masdemont).

<https://doi.org/10.1016/j.reuma.2017.09.003>
1699-258X/

© 2017 Elsevier España, S.L.U. y Sociedad Española de Reumatología y Colegio Mexicano de Reumatología. Todos los derechos reservados.

Rice Bodies in Tuberculous Tenosynovitis of Wrist



Cuerpos de arroz en la tenosinovitis tuberculosa de la muñeca

Dear Editor,

Rice body formation is an uncommon inflammatory process occurring in joints and tendon sheaths in systemic disorders.¹ Since their first description in 1895 in a patient with tuberculosis, these have been described in various rheumatic diseases including rheumatoid arthritis, juvenile idiopathic arthritis, and seronegative inflammatory arthritis, in infections with atypical mycobacteria, and in subacromial bursitis.^{2–5} Generally involving shoulder and knee joints, we describe here a rare case report of a patient with isolated wrist tenosynovitis with rice bodies on magnetic resonance imaging (MRI) who was diagnosed as tuberculosis based on results of microbiologic investigations.

A 50-year-old lady came with progressive pain and isolated swelling of the right wrist of 9 months duration. Physical examination revealed an oblong swelling on the volar aspect of wrist extending into the forearm. Attempted active flexion at the wrist was painful though passive range of movement was normal. Laboratory investigations showed raised erythrocyte sedimentation rate of 50 mm/h. Radiograph of the wrist was normal. MRI revealed well-defined fluid intensity collection along the flexor tendon sheath with presence of hypointense-layered lucencies within suggestive of tenosynovitis with rice bodies (Fig. 1A and B). The adjacent bone and soft tissues were normal. Fluid obtained by ultrasound-guided aspiration from the tenosynovial swelling was positive for Acid Fast Bacilli. Culture grew *Mycobacterium Tuberculosis* and hence, diagnosis of tuberculosis was reached. The patient did not have diabetes and was not on any immunosuppressive drugs. Serology for Human Immunodeficiency Virus (HIV) was non-reactive. The patient responded to six months of anti-tuberculous therapy with complete resolution of pain and swelling.

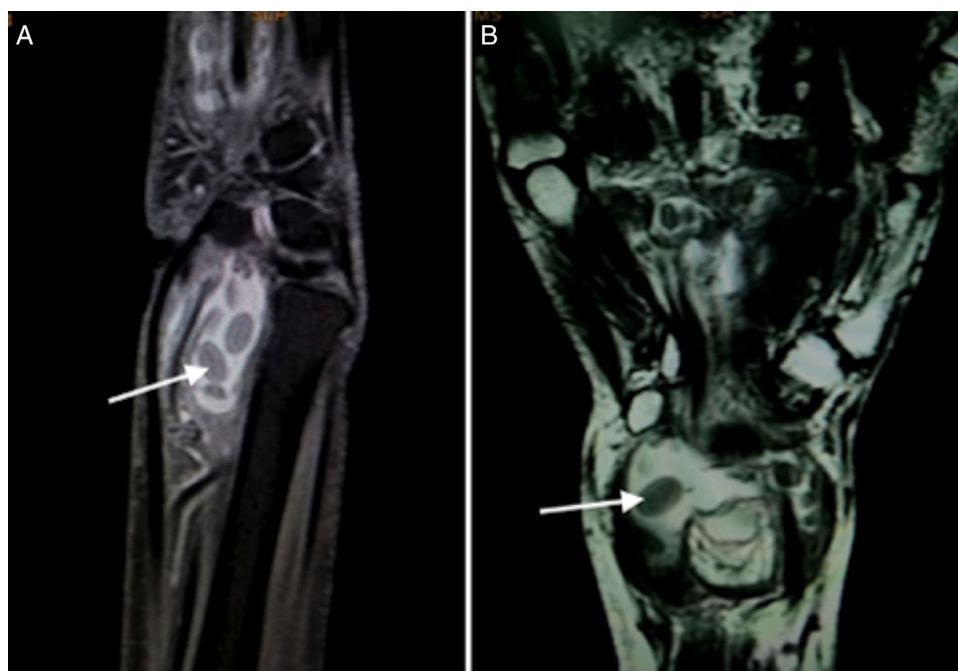


Fig. 1. (A) T2W FAT SAT sagittal image show a well defined fluid intensity collection seen along the flexor tendon sheath with presence of hypointense layered rice grain (white arrow) shaped within it suggestive of tenosynovitis with multiple loose bodies. (B) T2W Coronal images show well defined fluid intensity collection anterior to the wrist joint along the flexor tendon sheath suggestive of tenosynovitis. Multiple layered hypointense loose bodies like rice grain are seen within it (arrow).

Rice bodies are called so due to their resemblance to grains of polished white rice on gross examination. The pathogenesis of rice body formation is unclear, but is likely related to shedding of the infarcted synovial tissue into the joint.² These are formed by fibrin deposits on a nidus of sloughed synovium or inflamed tissue, as evidenced by rim of fibroblasts and inflammatory cells on a nidus of collagen. Types 1, 2 as well as small amounts of type 5 collagen have been demonstrated on histopathological sections.^{2,6,7} Rice bodies can be detected on both ultrasonography and MR imaging. Ultrasonography of tendon sheath may show low-level internal echoes or an apparent soft tissue mass, however, may fail to delineate individual rice bodies, particularly if these are too small.⁸ Therefore, MRI is considered the imaging modality of choice for rice bodies which appear iso- or hypointense to skeletal muscle on T1- and T2-weighted images.¹

Rice bodies are known to occur commonly in rheumatic conditions such as rheumatoid arthritis (RA), juvenile idiopathic arthritis, seronegative inflammatory arthritis, and also osteoarthritis.^{2–4,9} Pigmented villonodular synovitis (PVNS) and synovial osteochondromatosis form the primary differential diagnoses. In a patient with isolated tenosynovitis, infection is highly likely, and mycobacteria are most often implicated. Rice body formation has been seen with tenosynovitis due to *Mycobacterium tuberculosis*, and nontuberculous mycobacteria (NTM), including *Mycobacterium marinum*, *Mycobacterium kansasii*, rapid growing mycobacterium, *Mycobacterium avium* and *Mycobacterium intracellulare*.⁵ The laboratory should always be informed of the possibility of NTM, as these can be differentiated on culture. Treatment includes mycobacterial therapy and tenosynovectomy to avoid complications such as tendon rupture.¹⁰ However, rarely, as in our case, resolution has been reported with antitubercular therapy without any surgical treatment.¹¹

In a patient with early polyarthritis yet negative autoantibodies, rice body formation could be a salient marker to underlying RA. In established RA, it is important to know that these solid masses are treatable; as resolution has been described with intraarticular steroids and/or disease modifying anti-rheumatic drugs in most cases without sequelae. This can obviate a surgical procedure, which although initially successful, is associated with recurrence in one-third of patients. Half of those with recurrence require re-operation.¹² Lastly, rice bodies are rare in the wrist. If not identified and treated they can progress to compressive neuropathy and tendon ruptures.¹³

Bibliografía

1. Forse CL, Mucha BL, Lauren Zabala Santos M, Ongcapin EH. Rice body formation without rheumatic disease or tuberculosis infection: a case report and literature review. *Clin Rheumatol*. 2012;31:1753–6.
2. Cheung HS, Ryan LM, Kozin F, McCarty DJ. Synovial origins of rice bodies in joint fluid. *Arthritis Rheum*. 1980;23:72–6.
3. Popert AJ, Scott DL, Wainwright AC, Walton KW, Williamson N, Chapman JH. Frequency of occurrence, mode of development, and significance of rice bodies in rheumatoid joints. *Ann Rheum Dis*. 1982;41:109–17.
4. Subramaniam R, Tan JW, Chau CYP, Lee KT. Subacromial bursitis with giant rice bodies as initial presentation of rheumatoid arthritis. *J Clin Rheumatol*. 2012;18:352–5.
5. Chan HT, Tseng CC, Chen PY, Chao CM, Lai CC. Rice body – *Mycobacterium intracellulare* tenosynovitis. *QJM*. 2014;107:395.
6. Aşık M, Eralp L, Cetik O, Altinel L. Rice bodies of synovial origin in the knee joint. *Arthroscopy*. 2001;17:E19.
7. Druschel C, Funk JF, Kallinich T, Lieb A, Placzek RP. Development of rice bodies in 2 children younger than 3 years. *J Clin Rheumatol*. 2013;19:35–7.

8. Chau CLF, Griffith JF, Chan PT, Lui TH, Yu KS, Ngai WK. Rice-body formation in atypical mycobacterial tenosynovitis and bursitis: findings on sonography and MR imaging. *AJR Am J Roentgenol*. 2003;180:1455–9.
9. Bucki B, Lansaman J, Janson X, Billon-Galland MA, Marty C, Ruel M, et al. Osteoarthritis with rice bodies rich in calcium microcrystals 4 cases with ultrastructural study. *Rev Rhum Ed Fr*. 1994;61:415–20.
10. Ergun T, Lakadamyali H, Aydin O. Multiple rice body formation accompanying the chronic nonspecific tenosynovitis of flexor tendons of the wrist. *Radiat Med*. 2008;26:545–8.
11. Jain A, Rohilla R, Devgan A, Wadhvani J. Tubercular tenosynovitis of hand: a rare presentation. *J Orthop Case Rep*. 2016;6:69–72.
12. Wheen DJ, Tonkin MA, Green J, Bronkhorst M. Long-term results following digital flexor tenosynovectomy in rheumatoid arthritis. *J Hand Surg Am*. 1995;20:790–4.
13. Iyengar K, Manickavasagar T, Nadkarni J, Mansour P, Loh W. Bilateral recurrent wrist flexor tenosynovitis and rice body formation in a patient with seronegative rheumatoid arthritis: a case report and review of literature. *Int J Surg Case Rep*. 2011;2:208–11.

Latika Gupta^a, Vikas Gupta^{a,*}, Tushant Kumar^b

^a *Department of Clinical Immunology, Sanjay Gandhi Postgraduate Institute of Medical Sciences, Lucknow 226014, Uttar Pradesh, India*

^b *Department of Radiodiagnosis, Dr Ram Manohar Lohia Institute of Medical Sciences, Lucknow 226010, Uttar Pradesh, India*

* Corresponding author.

E-mail address: vikasgcapri@yahoo.co.in (V. Gupta).

<https://doi.org/10.1016/j.reuma.2017.08.003>
1699-258X/

© 2017 Elsevier España, S.L.U. and Sociedad Española de Reumatología y Colegio Mexicano de Reumatología. All rights reserved.