



Sociedad Española
de Reumatología -
Colegio Mexicano
de Reumatología

Reumatología Clínica

www.reumatologiaclinica.org



Images in Clinical Rheumatology

Acute calcific peri-arthritis in proximal interphalangeal joint: An unusual cause of acute finger pain



Periartritis calcificante aguda de la articulación interfalángica proximal: una causa inusual de dolor agudo en el dedo de la mano

Francisca Aguiar^{a,*}, Iva Brito^{a,b}

^a Rheumatology Department, Centro Hospitalar São João, Porto, Portugal

^b Faculty of Medicine of Porto University, Porto, Portugal

ARTICLE INFO

Article history:

Received 30 May 2017

Accepted 24 August 2017

Available online 10 October 2017

Clinical case

A 27-year-old right-hand-dominant female presented to the emergency department due to severe pain in the right third finger with associated swelling, that had developed five days previously. She denied any history of trauma, fever, systemic complaints or arthralgias at other joints. On examination, she showed redness, swelling, local heat and tenderness of the radial side of the proximal interphalangeal (PIP) joint of the right third finger. She had limited passive and active mobilization of the finger because of pain. No other abnormalities were noted.

The initial radiographs showed a well-circumscribed ovoid calcification adjacent to the radial and volar aspects of the PIP joint of the right third finger (Fig. 1). Laboratory investigation revealed normal leukocyte count, normal serum uric acid, calcium, phosphorus, alkaline phosphatase and parathyroid hormone levels, and a mildly elevated C-reactive protein at 10.3 mg/L (normal <3.0 mg/L). An ultrasound performed 3 day later demonstrated an ovoid heterogeneous calcific mass (Fig. 2).

The patient was managed conservatively with nonsteroidal anti-inflammatory drugs, ice compression and immobilization.

Three weeks later, the patient experienced complete resolution of swelling and pain and exhibited full range of motion. Follow-up radiographs after two months showed complete disappearance of the calcification (Fig. 3).

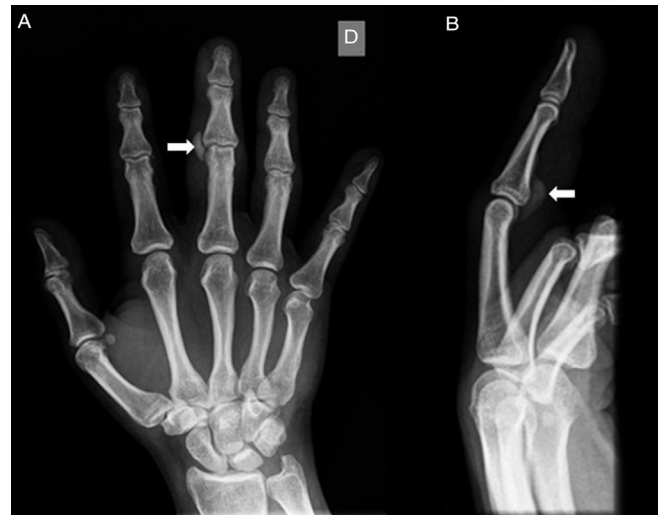

Fig. 1. Anteroposterior (Panel A) and lateral (Panel B) radiographs showing well-circumscribed calcification over the radial and volar aspect of the right third finger proximal interphalangeal joint (arrows).

Discussion

Acute calcific peri-arthritis is a form of hydroxyapatite deposition disease and is a rare cause of acute, severe periarticular pain in the hand.^{1,2} It occurs most frequently in the shoulder and wrist and

* Corresponding author.

E-mail address: francisca.ra@hotmail.com (F. Aguiar).

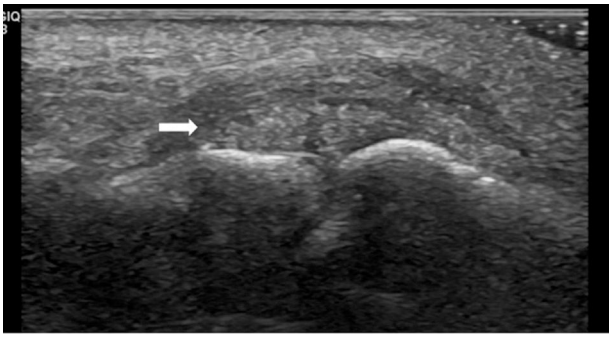


Fig. 2. Ultrasound longitudinal view demonstrating an ovoid heterogeneous mass with hyperechoic foci adjacent to proximal interphalangeal joint (arrow).

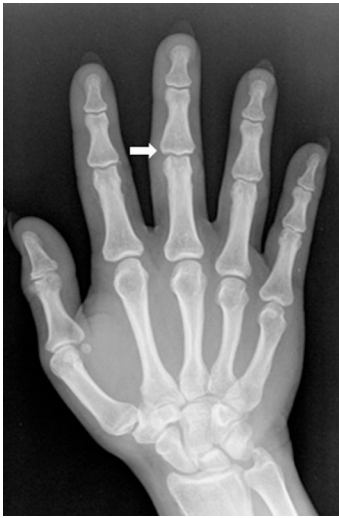

Fig. 3. Anteroposterior radiograph at 2 months follow-up demonstrating resolution of the calcified lesion (arrow).

patients are most commonly women with an average age of 45 years old (range 30–60), otherwise healthy.^{3,4}

The differential diagnosis is broad and includes infectious arthritis/tenosynovitis, gout, pseudogout, fracture and tumoral

conditions.^{2,4} Calcific peri-arthritis should be considered when faced with an acute painful finger, especially in the presence of calcification on radiographs or ultrasound. This would avoid unnecessary treatments such as antibiotics and surgery.^{2,3,5}

Ethical disclosures

Protection of human and animal subjects. The authors declare that no experiments were performed on humans or animals for this study.

Confidentiality of data. The authors declare that no patient data appear in this article.

Right to privacy and informed consent. The authors declare that no patient data appear in this article.

Conflict of interest

The authors declare that there are no conflicts of interest.

References

1. Touraine S, Wybier M, Sibille E, Genah I, Petrover D, Parlier-Cuau C, et al. Non-traumatic calcifications/ossifications of the bone surface and soft tissues of the wrist, hand and fingers: a diagnostic approach. *Diagn Interv Imaging.* 2014;95:1035–44.
2. Munjal A, Munjal P, Mahajan A. Diagnostic dilemma: acute calcific tendinitis of flexor digitorum profundus. *Hand (N Y).* 2013;8:352–3.
3. Moradi A, Kachooei AR, Mudgal CS. Acute calcium deposits in the hand and wrist. *J Hand Surg Am.* 2014;39:1854–7.
4. Dumas C, Vazirani RM, Clifford PD, Owens P. Acute calcific peri-arthritis of the hand and wrist: a series and review of the literature. *Emerg Radiol.* 2007;14:199–203.
5. Kim YS, Lee HM, Kim JP. Acute calcific tendinitis of the flexor digitorum superficialis of the finger: a case report. *Open J Orthop.* 2014;4:45–7.