



Sociedad Española  
de Reumatología -  
Colegio Mexicano  
de Reumatología

# Reumatología Clínica

www.reumatologiaclinica.org



Images in Clinical Rheumatology

## Post-infectious Digital Ischemia Successfully Treated with Iloprost in a Child



Isquemia digital postinfecciosa infantil tratada con éxito con iloprost

Teresa Martins-Rocha<sup>a,\*</sup>, José Pedro Matias<sup>b</sup>, Margarida Vicente Ferreira<sup>b</sup>, Bárbara Mota<sup>b</sup>, Iva Brito<sup>a,c</sup>

<sup>a</sup> Rheumatology Department, Centro Hospitalar de São João, Porto, Portugal

<sup>b</sup> Department of Pediatrics, Centro Hospitalar de São João, Porto, Portugal

<sup>c</sup> Rheumatology Department, Faculty de Medicine University of Porto (FMUP), Portugal

### ARTICLE INFO

#### Article history:

Received 16 April 2018

Accepted 29 May 2018

Available online 18 July 2018

We report a case of a 14-month-old girl, with no relevant pathological history, which presented additive bullous lesions on her hands and feet fingertips. She had no previous burn, trauma or other associated events. One week before, she was diagnosed with Acute Otitis Media and was treated with amoxicillin/clavulanic acid for 8 days. Later on, the fingertip lesions progressively evolved into necrotic lesions and, after two months of the initial presentation, she was observed at our hospital. Objectively, she was afebrile and presented digital plaques of dry necrosis, with edema and redness of the distal end of the affected fingers, without fluctuation or drainage of any content (Fig. 1). Peripheral arterial pulses were symmetric and no vascular or heart bruits were audible. As iloprost has been described to be safe and effective for the treatment of ischemic digits in children, intravenous iloprost (0.4 ng/kg/min for 5 days followed by 0.6 ng/kg/min) and acetylsalicylic acid were started.<sup>1-4</sup>

Concerning laboratory studies, she had CRP (50 mg/L) and ESR (60 mm/1st hour) elevation; negative serologies for EBV, Herpes simplex, CMV, parvovirus and *Mycoplasma pneumoniae*; negative antistreptolysin O titer and blood cultures. Pro-thrombotic and immunological studies (complement levels, rheumatoid factor, ANA, anti-ENA, anti-dsDNA, ANCA and antiphospholipid

antibodies) were unremarkable. Echocardiogram, chest and hands X-rays, and abdominal ultrasound were normal.

She completed 21 days of iloprost and gradually presented resolution of the fingertip lesions. Considering the previous infection and the diagnostic work-up, we considered the digital ischemia in a probable post-infectious context.

Digital ischemia is described in meningococcal infection, which can present extrameningeal involvement in up to 19% of patients.<sup>5</sup> Additionally, few cases were also reported with other infectious agents.<sup>1,6</sup> Among others, treatment with antiplatelet drugs, topical nitrates and sympathetic blockade is described.<sup>7</sup> Besides our report, favorable response to iloprost was documented in 4 children with post-infectious digital ischemia.<sup>1,4,8</sup>

#### Funding

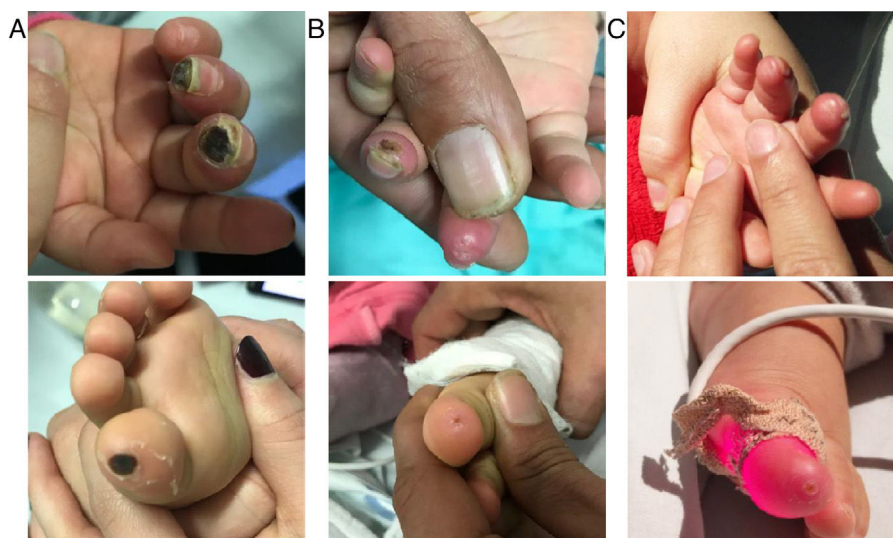
No specific funding was received from any bodies in the public, commercial or not-for-profit sectors to carry out the work described in this manuscript.

#### Conflicts of interest

The authors declare they have no conflicts of interest.

\* Corresponding author.

E-mail address: [teresa.asmr@gmail.com](mailto:teresa.asmr@gmail.com) (T. Martins-Rocha).



**Figure 1.** Ischemic lesions at the admission (A), at the 13th (B) and at the 21st day (C) of therapy with intravenous iloprost.

## References

- García Soler P, Milano Manso G, Camacho Alonso JM, Manuel Gonzalez J. [Iloprost for the treatment of digital ischaemia in pediatric septic shock]. *Med Clin (Barc)*. 2011;136:695–6.
- Shouval DS, Mukamel M, Zulian F, Amir J, Harel L. Iloprost treatment for refractory Raynaud's phenomenon in two infants. *Clin Exp Rheumatol*. 2008;26 3 Suppl 49: S105–7.
- Zulian F, Corona F, Gerloni V, Falcini F, Buoncompagni A, Scarazatti M, et al. Safety and efficacy of iloprost for the treatment of ischaemic digits in paediatric connective tissue diseases. *Rheumatology (Oxford)*. 2004;43: 229–33.
- Siddiqui K, Razak AR, Kneafsey B, Delanty N. Use of prostacyclin (iloprost) in digital vasculitis secondary to meningococcaemia. *J Neurol Neurosurg Psychiatry*. 2004;75:506.
- Kirsch EA, Barton RP, Kitchen L, Giroir BP. Pathophysiology, treatment and outcome of meningococemia: a review and recent experience. *Pediatr Infect Dis J*. 1996;15:967–78, quiz 79.
- Singh Y, Khan TR, Kushwaha KP. Spontaneous pneumothorax with symmetrical digital gangrene – a rare complication of chickenpox. *Indian J Pediatr*. 2013;80:706–7.
- Leclerc F, Leteurtre S, Cremer R, Fourier C, Sadik A. Do new strategies in meningococemia produce better outcomes? *Crit Care Med*. 2000;28 9 Suppl. S60–3.
- Seaton RA, Nathwani D, Dick J, Smith D. Acute meningococcaemia complicated by late onset gastrointestinal vasculitis. *J Infect*. 2000;41:190–1.