




Sociedad Española  
de Reumatología -  
Colegio Mexicano  
de Reumatología



## Images in Clinical Rheumatology

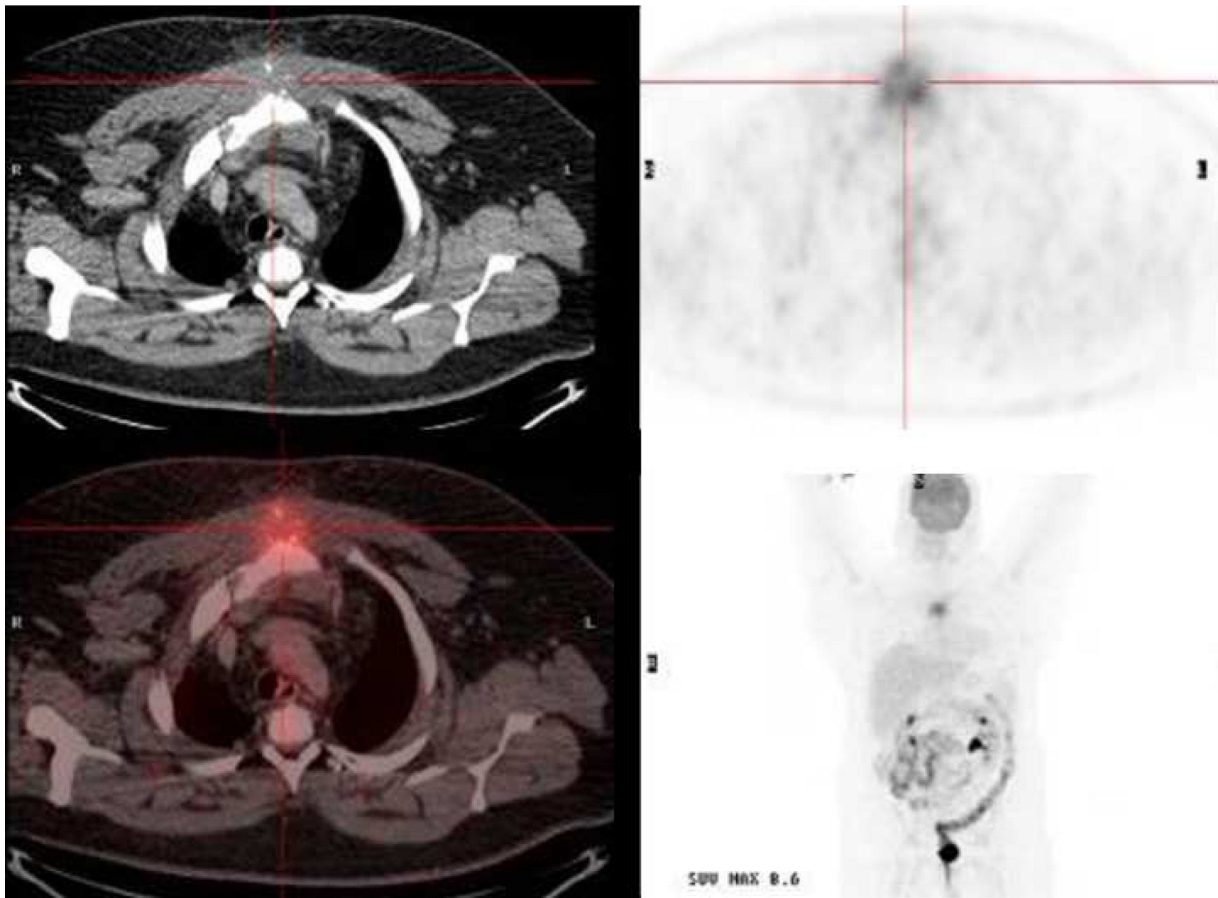
### Unusual presentation of IgG4-related disease

### Presentación inusual de la enfermedad relacionada con el IgG4

Jonathan Franco Vanegas<sup>a,\*</sup>, Martí Esteban i Fernández<sup>b</sup>, Jordi Robert Olalla<sup>b</sup>

<sup>a</sup> Department of Internal Medicine, Clinic Mi Tres Torres, Barcelona, Spain

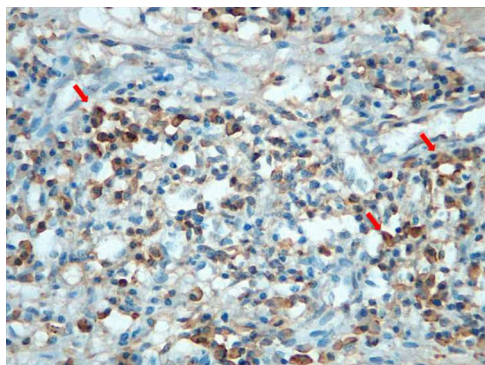
<sup>b</sup> Department of Internal Medicine, Hospital Universitario Dexeus, Barcelona, Spain



**Fig. 1.** Thoracic computed tomography scan shows destructive sternal bone lesion associated with a soft tissue mass (approximate size 96 mm × 71 mm × 53 mm) with a hypermetabolic lytic lesion at the manubrium-sternal junction, associated to a mass of perilesional soft tissues, and infiltration of the upper mediastinal fat with a SUV max value of 8.6.

\* Corresponding author.

E-mail address: [jhonatanfrancov@gmail.com](mailto:jhonatanfrancov@gmail.com) (J. Franco Vanegas).



**Fig. 2.** Biopsy of the sternal lesion with immunohistochemical staining for IgG4 shows IgG4 positive plasma cells (arrows).

A 45-years-old male patient came to the Emergency Room due to a chest pain of a month of evolution, the physical examination was normal. The patient has a history of metabolic syndrome. Cardiac pathology was ruled out. A thoracic computed tomography (CT) scan was performed, where an destructive sternal bone lesion associated with a soft tissue mass located in the upper third of the breastbone was observed (approximate size 96 mm × 71 mm × 53 mm) associated to a soft tissue mass located at the upper third of the breastbone were found, in addition to sug-

gestive of malignancy bilateral axillary mediastinal adenopathy's (Fig. 1).

A PET-CT was performed, where a hypermetabolic lytic lesion at the manubrium-sternal junction, associated to a mass of soft tissue, with infiltration of the upper mediastinal fat with a SUVmax value of 8.6 were found (Fig. 1)

A biopsy of the sternal lesion and the soft tissue mass were performed, whose appearance was highly suggestive of IgG4-related disease, because a positive immunohistochemical study for IgG4 plasma cells was clearly present (Fig. 2). Elevated IgG4 levels in peripheral blood were also found. Treatment with dexamethasone was initiated, and a complete clinical response was seen.

IgG4-related disease is an autoimmune systemic disorder that can affect virtually any organ, most often affecting the pancreas, lymph nodes, and salivary glands.<sup>1</sup> The lesions have their own histopathological characteristics, mainly infiltration of IgG4 positive plasma cells in the affected tissue; usually an increase of IgG4 serum levels of is also present.<sup>2,3</sup>

## References

1. Stone JH, Zen Y, Deshpande V. IgG4-related disease. *N Engl J Med.* 2012;366:539–51.
2. Kamisawa T, Zen Y, Pillai S, Stone JH. IgG4-related disease. *Lancet.* 2014;6736:1–12.
3. Khosroshahi A, Stone JH. A clinical overview of IgG4-related systemic disease. *Curr Opin Rheumatol.* 2011;23:57–66.