

## Images in clinical rheumatology

### Fracture and dislocation of the atlanto-axial joint after mild trauma in a patient with rheumatoid arthritis

Gracia María Ábalos Medina, <sup>a,\*</sup> Gonzalo Ruiz Villaverde, <sup>b</sup> María del Mar Castellano García, <sup>b</sup> and Enrique Raya Álvarez <sup>a</sup>

<sup>a</sup> Department of Rheumatology, Hospital Clínico San Cecilio, Granada, Spain

<sup>b</sup> Department of Radiodiagnostics, Hospital Virgen de las Nieves, Granada, Spain

#### Introduction

The importance of the present article lies in the fact that it deals with an infrequent complication in patients with rheumatoid arthritis, because most of the fractures that occur on the odontoid process are non-traumatic in origin. Dislocations of the atlantoaxial joint have an incidence that goes from 19% to 70%, according to the studies consulted. Normally, the space between the odontoid process, in its anterior border, and the posterior border of the anterior arch of the atlas is 2.5 mm, and remains constant in flexion and extension. When the transverse ligament is lax, this space increases in size. In rheumatoid arthritis, the anterior part of the odontoid process can be eroded in 14%–35% of cases and is usually related to dislocation.

#### Clinical case

A 70 year-old male was diagnosed with seropositive rheumatoid arthritis 6 years before and had undergone treatment with steroids, non-steroidal anti-inflammatory drugs (NSAID), and methotrexate 10 mg/week, with a good clinico-biologic progression. In addition he had baseline mental retardation, making the physical examination challenging. He did not present any other history of interest.

An emergency service brought the patient to the emergency department because he had suffered low-impact head trauma 12 days before after a casual fall, leading to intense occipital headache, which led the patient to hold his head. The patient was conscious and oriented with a Glasgow score of 15/15 and with no focal signs upon examination; a head computerized tomography (CT) was performed urgently, finding no images that were compatible with acute trauma injury.

In spite of having been administered analgesics, the patient continued presenting intense pain, forcing an exhaustive clinical

re-evaluation which manifested a marked instability of the cervical spine, without sensory-motor deficit; medical examination was difficult due to the patients mental condition. An x-ray was performed (Figure 1A) as well as a cervical spine CT (Figures 1B and C) which showed a type III odontoid fracture with important dislocation of C1–C2. The study was completed after a cervical magnetic resonance (MR) showed a fracture of C2 with the previously mentioned characteristics, erosion of the C1 transverse ligament, compatible with the baseline disease of the patient (rheumatoid arthritis), without any appreciable signs of spinal canal or cervical spinal cord compromise.

#### Diagnosis and progression

A type III odontoid process fracture with dislocation of C1–C2 in a patient with Rheumatoid Arthritis. Twelve days after the diagnosis was made, after being programmed by the department of neurosurgery, the patient underwent reduction and fixation of the joint using a halo-vest orthosis. The patient has shown a favorable progression; some generalized weakness is present due to prolonged bed rest but has been evaluated by the physical rehabilitation department and has started treatment.

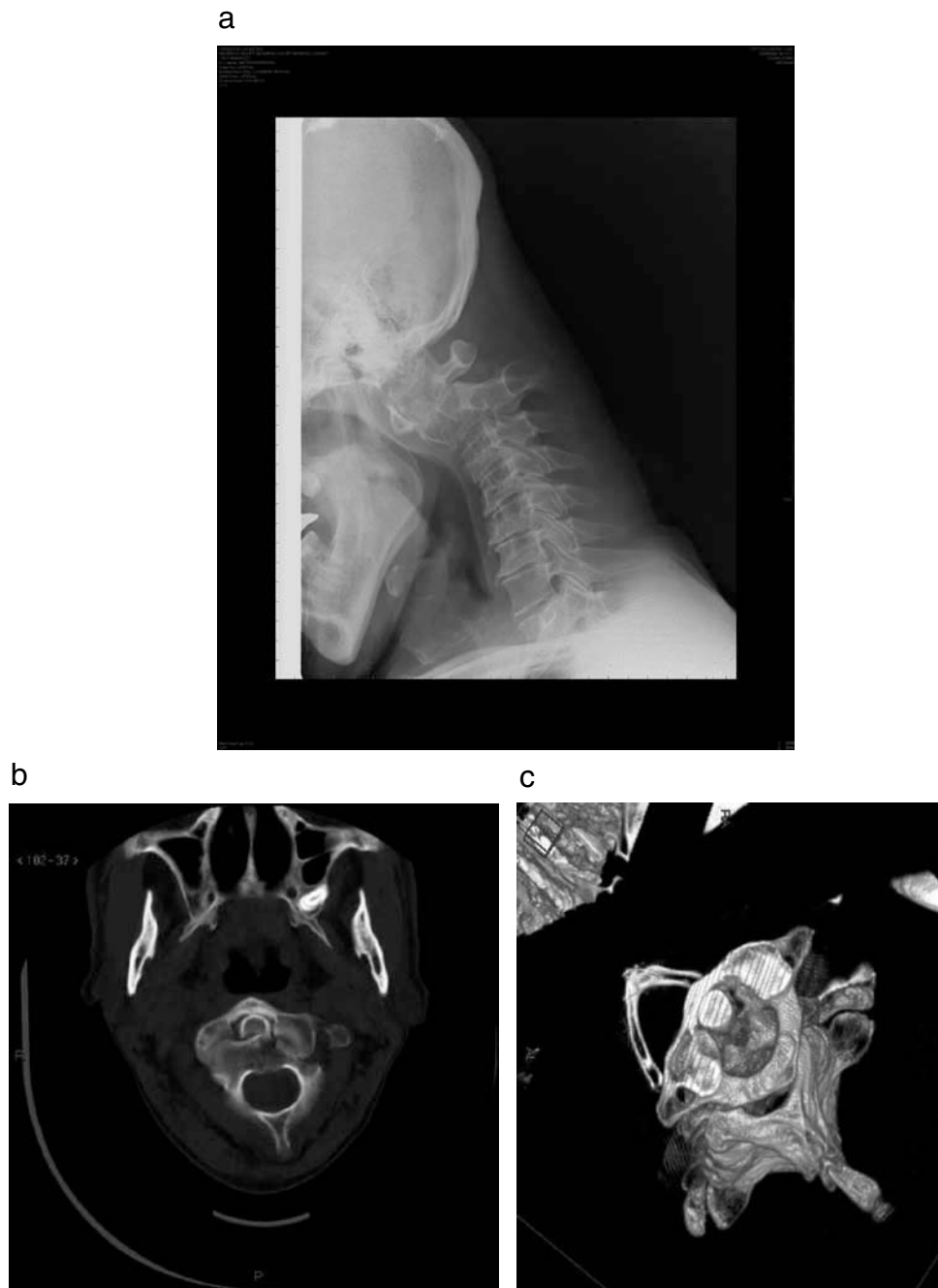
#### Discussion

The superior cervical spine can be affected in rheumatoid arthritis. Deviation and instability originate from the destruction of bone and the ligaments that support it, and is caused by synovial proliferation. The inflammatory alteration of the synovial atlantoaxial joints produce erosive changes in the odontoid process, as well as osteoporosis and loss of the insertion of the transverse ligament of the atlas. All of this leads to instability, which allows the anterior dislocation of the atlas over the axis.<sup>1</sup>

It has been determined that the degree of deterioration of the cervical spine is correlated with the duration and progression of rheumatoid arthritis.<sup>2</sup> Winfield et al<sup>3</sup> communicated that peripheral joint erosions and cervical dislocations coincide in severity and timing, and indicated that these 2 processes are firmly related with the activity of disease.

\* Corresponding author.

E-mail address: [graciabalosmed@hotmail.com](mailto:graciabalosmed@hotmail.com) (G.M. Ábalos Medina).



**Figure.** a: Cervical spine x-ray, lateral projection. An alteration in the alignment of C1 and C2 vertebral bodies can be seen, with an anterior displacement of the atlas over the axis. b: Helical computerized tomography (CT) of the cervical spine, axial projection. A C2 fracture that affects the odontoid process and the anterior and left portion of the body can be seen, with dislocation of the joint facets of C1 and C2. c: Helical CT of the spinal column: Three dimensional retrospective reconstruction.

In the majority of patients, atlantoaxial dislocation is progressive, but in a small percentage it could stabilize or spontaneously fuse.<sup>4</sup> Type I odontoid fractures are oblique and unilateral, due to avulsion of one of the winged ligaments that pass by the tip of the odontoid process.<sup>5</sup> These fractures are seldom displaced and usually heal without complications.

Type II fractures occur in the union of the odontoid process and the body of C2 and interrupt blood flow to the odontoid process. If displacement is more than 4 mm, it is considered a sign of instability. Type III fractures have a horizontal oblique direction, adjacent to the base of the odontoid process with extension to the vertebral body of

C2. If the fracture is stable, treatment of the lesions is orthopedic; if unstable, treatment of choice is surgical. Different internal and external fixation methods have been proposed for the treatment of these fractures. The rate of fusion failure in cases treated with external fixation through orthosis, "halo" or Minerva oscillates between 7% and 100%. Because of this, most of the authors prefer to perform an internal fixation, helped by an external one in some cases, especially in combined atlantoaxial fractures. The different internal fixation techniques can be done through an anterior, posterior or combined approach, according to the preference of the surgeon or the characteristics of the lesion.<sup>6</sup>

In rheumatoid arthritis, erosion and osteoporosis weaken the arch of C1, making extreme care necessary in order not to fracture it.<sup>7</sup> The most frequent site of fusion failure is the interface between the bone implant and the posterior arch of C1.<sup>8</sup>

After the intervention, 68% of patients show symptom improvement, while 29% have postoperative complications, which include sudden death, dislocation of the cervical spine, fracture of the arch of the atlas, hemiparesis, dysphagia, pressure ulcers and infection of the surgical wound.<sup>9</sup>

### Conclusions

In patients with long-standing rheumatoid arthritis, the possibility of atlantoaxial dislocation must be present as a complication of the disease. From this one must keep in mind that these patients have a higher susceptibility to present a fracture-dislocation of the abovementioned joint with minimal-intensity trauma.

### References

1. Lipson SJ. Rheumatoid arthritis in the cervical spine. *Clin Orthop.* 1989;239:121-7.
2. Fujiwara K, Fujimoto M, Owaki J, Kono J, Nadase T, Yonenobu K. Cervical lesion related to systemic progression in rheumatoid Arthritis. *Spine.* 1998;23:2052-6.
3. Winfield J, Young A, Williams P, Cobertt M. Prospective study of radiological changes in hands, feet, and cervical spine in adult rheumatoid arthritis. *Ann Rheum Dis.* 1983;42:613-8.
4. Dreyer SJ, Boden SD. Natural history of rheumatoid arthritis of the cervical spine. *Clin Orthop.* 1999;366:98-106.
5. Anderson LD, D'Alonzo RT. Fractures of the Odontoid Process of the axis. *J Bone Joint Surg (Am).* 1974;56:1663-74.
6. Lind B, Nordwall A, Sihlbom H. Odontoid fractures treated with halocest. *Spine.* 1987;12:173-7.
7. Papadopoulos SM, Dickman CA, Sontag VKH. Atlantoaxial stabilization in rheumatoid arthritis. *J Neurosurg.* 1991;74:1-7.
8. Zoma A, Sturrock RD, Fisher WD, Freeman PA, Hamblen DL. Surgical stabilization of the rheumatoid cervical spine. A review of indications and results. *J Bone Joint Surg (Br).* 1987;69:8-12.
9. Hartlev LB, Gudmundsdottir G, Mosdal C, Stengaard-Pedersen K. Rheumatoid arthritis with atlanto-axial subluxation. Pre- and postoperative symptoms, radiological findings and operative complications. *Ugeskr Laeger.* 2008;170:647-50.