



Case report

NeuroBehçet: a case

Germán Latorre González, * Ana Belén Escribano Gascón, Carlos López de Silanes de Miguel, Rocío García Cobos, Luis Ignacio Casanova Peño, and Teresa Lapeña Montero

Hospital Clínico San Carlos, Madrid, Spain

ARTICLE INFO

Article history:

Received February 7, 2008

Accepted June 2, 2008

Online April 2, 2009

Keywords:

Behçet's disease

NeuroBehçet

Neurological alterations

ABSTRACT

Behçet's disease is an inflammatory systemic disorder, with oral and genital ulcers, as well as ophthalmologic and cutaneous disturbances. Five percent of the patients have neurological alterations. We present a case of neuroBehçet with a rare neurological involvement.

A 28-years-old male patient with recurrent oral and genital ulcer history and folliculitis presents 48 h progressive fever, headache, nausea, right sixth cranial nerve palsy, and right upper limb paresis. The CSF showed lymphocyte pleocytosis and high proteinorrachia, so antibiotic treatment was initiated. Cerebral MR found hyperintense enhancing lesions in the brainstem and left transverse sinus thrombosis. Patient improved with endovenous corticosteroids and was discharged asymptomatic.

Neurological involvement in Behçet's disease is rare and moreover the coexistence of parenchymatous and non-parenchymatous alterations in the same patient. It normally has a good response to immunosuppressant treatment.

© 2008 Elsevier España, S.L. All rights reserved.

Neurobehçet: a propósito de un caso

RESUMEN

La enfermedad de Behçet es un trastorno inflamatorio sistémico, caracterizado por aftosis orogenital así como por alteraciones oftalmológicas y cutáneas. Un 5% de los pacientes presenta manifestaciones neurológicas. Se presenta un caso de neurobehçet con participación neurológica inhabitual.

Varón de 28 años con antecedente de aftas orales y genitales recurrentes e historia de foliculitis, que acudió por cuadro de 48 h de fiebre, cefalea, náuseas, paresia del sexto par craneal y del miembro superior derecho. El análisis del líquido cefalorraquídeo reveló pleocitosis linfocitaria con hiperproteínorraquia, se inició tratamiento antibiótico de amplio espectro. Se realizó resonancia magnética cerebral, que mostró lesiones hiperintensas de predominio troncoencefálico con realce tras infusión de gadolinio y trombosis del seno transverso izquierdo. El paciente mejoró progresivamente con tratamiento intravenoso con corticoides hasta quedar asintomático.

La afectación neurológica en la enfermedad de Behçet es infrecuente y más aún la coexistencia de lesiones intraparenquimatosas y extraparenquimatosas. Habitualmente, presenta buena respuesta al tratamiento inmunosupresor.

© 2008 Elsevier España, S.L. Todos los derechos reservados.

Palabras clave:

Enfermedad de Behçet

Neurobehçet

Afectación neurológica

Introduction

Behçet's disease (BD) is an infrequent systemic inflammatory process with an autoimmune basis that primarily affects young, white men. It is usually manifested as recurrent oral and genital ulcers, polyarthritis, skin (eritema nodosus, folliculitis, pathergy, pustules,

and papules) and eye alterations (anterior or posterior uveitis, retinal vasculitis). Other organs may be affected, among them the nervous system. Its ethiopathogenesis is not clear and there are no genetic or biological markers for their diagnosis or follow-up.¹

Clinical observation

A 28-year-old male patient was admitted to our hospital with fever, headache, nausea, malaise, and myalgias lasting for 48 h,

* Corresponding author.

E-mail address: ger.latorre@gmail.com (D. Latorre González).

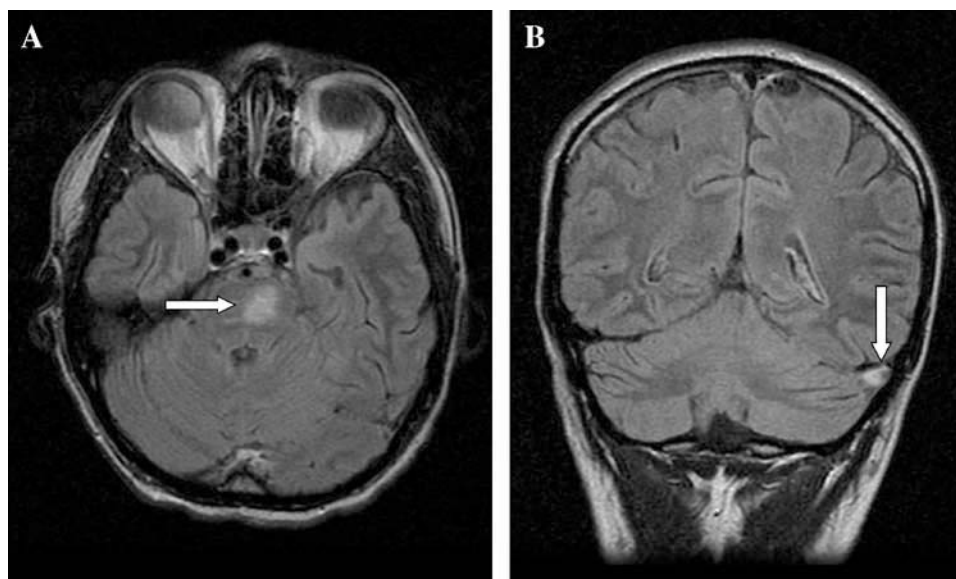


Figure. A) Transversal fluid-attenuated inversion recovery (FLAIR) sequence; hyperintense cerebral and stem image (white arrow). B) Coronal FLAIR sequence; left transverse sinus thrombosis (white arrow).

accompanied by bilateral diplopia and clumsiness of the upper right extremity.

The general physical examination and the vital signs were normal, except for the presence of fever. The neurological examination showed sixth cranial nerve paresis, upper right extremity paresis, neck stiffness, and papilledema.

In the Emergency Room a complete laboratory analysis was normal except for a erythrocytation rate of 25 mm/h. A lumbar puncture was performed which showed an opening pressure of cerebrospinal fluid (CSF) of 23 cm of water; 140 leukocytes, with 90% mononuclear cells; 85.6 mg/dL of protein, and glucose 45 mg/dL. The microbiologic CSF exams (gram stain, ink stain and direct antigen testing) were negative.

Faced with the clinical data and tests performed in the ER, wide-spectrum empirical antibiotic treatment was begun, in spite of which symptoms persisted. Two days after hospitalization, a painful scrotal ulcer appeared. The patient was reinterrogated and he admitted a history of oral ulcers at least on 3 occasions in the past year and recurrent folliculitis. A magnetic resonance of the central nervous system was performed that showed hyperintense lesions in the potentiated T2 sequences in the left paramedial region of the protuberance, which presented a nodular enhancement after the infusion with gadolinium, as well as a filling image of the left transverse sinus compatible with thrombosis (Figure). The rest of the serological, immunological, and microbiological studies were negative. Intravenous treatment with high-dose steroids and anticoagulants was begun, with the symptoms disappearing. Azathioprine was opted for in the long term but the lack of compliance on the part of the patient generated 2 relapses of aseptic meningoencephalitis in the following months, treated anew with intravenous steroids. At the moment, the patient is asymptomatic, follows a chronic treatment with azathioprine, and has not shown any new relapses of the disease or medication related complications.

Discussion

Nervous system involvement occurs in 5% of cases of BD and is exceptional at the moment of diagnosis. In addition, it is rare that the neurological observations precede classical manifestations such as ulcers or uveitis.² The central nervous system can be affected in several

ways; as parenchymal alterations (aseptic meningoencephalitis, with predominant rhombencephalitis and myelitis) and extraparenchymal or secondary, due to the appearance of thrombotic arterial or venous episodes that affect the central nervous system. The latter suppose approximately 20% of cases of neuroBehçet in most of the described series.³ It is exceptional that both manifestations coexist in the same patient. Currently, the relationship between the appearance of thrombotic episodes, due to a thrombophilia probably unleashed by primary endothelial dysfunction, and parenchymal manifestations in the midst of a vasculitis assumedly generated by immune complexes, is unknown.^{4,5} Physiopathology of the parenchymal manifestations is not exactly known because anatomoclinical series are not very extensive. Some anatomoclinical studies have shown areas of meningoencephalitis with low grade chronic lymphocyte infiltrates, as well as perivenular and periarterolar neutrophilic, plasmocytic and lymphocytic infiltrates and zones of multifocal necrosis which tend to localize on the stem and spinal cord.⁶ There can also be peripheral nervous system affection (mononeuritis multiplex, polyradiculoneuritis, myositis).⁷ Occasionally, neuropsychiatric manifestations can be seen (depression, dementia, psychosis, chorea), as well as vestibular, gastrointestinal, vascular (thromboflebitis, thoracic aneurism), cardiac (pericarditis, myocarditis), renal, and urological (urethritis, epididimitis) affection.

The treatment of the neurological manifestations of BD is controversial because of the clinical and physiopathological heterogeneity, the difficulty in predicting the clinical progression and the absence of controlled trials. Large intravenous doses of methylprednisolone are usually used for treating flares in addition to background immunosuppressants in order to avoid relapse.⁸ There is no evidence on which immunosuppressant is most useful for neuroBehçet cases, and their use is based on empirical observations. The most commonly used drugs are azathioprine, methotrexate, or monthly boluses of cyclophosphamide; the use of cyclosporine is not recommended because worsening of neurological manifestations has been associated to it.^{9,10} The selection of the drug is based on operational criteria and recommendations from task forces and expert consensus, more than on solid scientific evidence. Regarding other drugs employed for eye or systemic manifestations of BD, such as mycophenolate mofetil, infliximab, or etanercept, there is no current information available on its potential use in neuroBehçet.^{11,12}

Regarding anticoagulant treatment, its use is also controversial and, once again, there are no controlled trials available. Most of the authors agree on the use of anticoagulant or antiplatelet agents, with or without steroids, for the treatment of thrombosis of the cerebral venous sinuses, but there is no consensus on which drug to use (sodium heparin, low molecular weight heparins, oral anticoagulants, antiplatelet drugs) nor the time they should be employed, making it important to perform an individualized recommendation in each case based on the experience of the medical team and the patients' preferences.¹³

Conclusions

The diagnosis of BD is clinical and in order to facilitate such a process, diagnostic criteria have been developed.¹⁴ The case we present is an extremely rare presentation of BD, with affection of the nervous system manifested by severe rhombencephalitis and simultaneous thrombosis of the cerebral venous sinuses. In the largest series published to date, this coincidence has been seen in less than 1% of neurobehçet cases.¹⁵ This process must be suspected in all cases of aseptic lymphocytic meningoencephalitis or cerebral venous thrombosis without other prothrombotic risk factors.¹⁶

References

1. Cem-Evereklioglu MD. Current concepts in the etiology and treatment of Behçet Disease. *Surv Ophthalmol*. 2005;50:297-350.
2. Akman-Demir G, Baykan-Kurt B, Serdaroglu P, Gürvit H, Yurdakul S, Yazici H, et al. Seven-year follow-up of neurologic involvement in Behçet's syndrome. *Arch Neurol*. 1996;53:691-4.
3. Akman-Demir G, Serdaroglu G, Tasçi B. Clinical patterns of neurological involvement in Behçet's disease: Evaluation of 200 patients. *Brain*. 1999;122:2171-81.
4. Mizuki N, Ohno S. Immunogenetic studies of Behçet's disease. *Rev Rheum Engl*. 1996;63:520-7.
5. Dinc A, Takafuta T, Jiang D, Melikoglu M, Saruhan-Dineskeneli G, Shapiro SS, et al. Anti-endothelial cell antibodies in Behçet's disease. *Clin Exp Rheumatol*. 2003;21:27-30.
6. Lakhnani S, Tani K, Lie JT, Katoh H, Ishigatsubo Y, Ohokubo T. Pathological features of Behçet's syndrome: A review of Japanese autopsy registry data. *Hum Pathol*. 1985;16:790-5.
7. Akman-Demir G, Serdaroglu P. Neuro-Behçet's Disease: A practical approach to diagnosis and treatment. *Practical Neurology*. 2002;2:340-7.
8. Siva A, Fresko I. Behçet's disease. *Curr Treatment Options Neurol*. 2000;2:435-47.
9. Schwartz RB, Bravo SM, Klufas RA, Hsu L, Barnes PD, Robson CD, et al. Cyclosporin neurotoxicity and its relation to hypertensive neuropathy: CT and MR findings in 16 cases. *Am J Roentgenol*. 1995;165:627-31.
10. Kotake S, Higashi K, Yoshikawa K, Sasamoto Y, Okamoto T, Matsuda H, et al. Central nervous system symptoms in patients with Behçet's disease receiving therapy. *Ophthalm*. 1999;106:586-9.
11. Sfikakis PP. Behçet's disease: A new target for anti-tumour necrosis factor treatment. *Ann Rheum Dis*. 2002;61:51-3.
12. Russel AI, Lawson WA, Haskard DO. Potential new therapeutic options in Behçet's syndrome. *BioDrugs*. 2001;15:25-35.
13. Calamia KT, Schirmer M, Melikoglu M. Major vessel involvement in Behçet disease. *Curr Opin Rheumatol*. 2004;17:1-8.
14. Yurdakul S, Hamuryudan V, Yazici H. Behçet syndrome. *Curr Opin Rheumatol*. 2004;16:38-42.
15. Benamour S, Naji T, Alaoui FZ, El-Kabli H, El-Aidouni S. Neurological involvement in Behçet's disease. 154 cases in a cohort of 925 patients and review of the literature. *Rev Neurol (Paris)*. 2006;162:1084-90.
16. Siva A, Altintas A, Saip S. Behçet's syndrome and the nervous system. *Curr Opin Neurol*. 2004;17:347-57.