

## Case report

## *Legionella* in a patient with rheumatoid arthritis receiving abatacept

Patricia Novas Vidal, Silvia González Díez, and Javier Velasco Montes \*

Servicio de Medicina Interna, Hospital Universitario Marqués de Valdecilla, Santander, Spain

## ARTICLE INFO

## Article history:

Received September 9, 2008  
 Accepted October 12, 2008  
 Available online May 6, 2009

## Keywords:

Arthritis rheumatoid  
 Abatacept  
 Legionella pneumophila

## Palabras clave:

Artritis reumatoide  
 Abatacept  
 Legionella pneumophila

## ABSTRACT

Abatacept is a new drug available for refractory rheumatoid arthritis (RA), as other biologic therapies this drug is not free of potentially serious adverse events. We present a case of a 73-year-old patient treated with abatacept who suffered a Legionella pneumophila type 1 pneumoniae.

© 2008 Elsevier España, S.L. All rights reserved.

### ***Legionella* y artritis reumatoide en tratamiento con abatacept**

## RESUMEN

El abatacept es un nuevo fármaco disponible para el tratamiento de los pacientes con artritis reumatoide (AR) refractaria. No obstante, al igual que sucede con otros tratamientos biológicos, este tratamiento no está exento de potenciales efectos adversos. A continuación se presenta el caso de una paciente de 73 años, con AR tratada con abatacept, en el que se desarrolló neumonía por Legionella pneumophila tipo 1.

© 2008 Elsevier España, S.L. Todos los derechos reservados.

## Introduction

Common treatments for rheumatoid arthritis (RA) include traditional antirheumatic disease-modifying drugs (DMARD) such as methotrexate and biologic agents, such as TNF (tumor necrosis factor) inhibitors. In spite of the fact that these therapeutic options benefit a lot of patients, a significant proportion does not respond to anti-TNF therapy<sup>1-4</sup> and other present a diminished response to it with time.<sup>5</sup> In addition, a subgroup of patients presents drug-related toxicity that obliges the clinician to suspend treatment.<sup>1,2,4</sup> Other treatments have recently been introduced to the population of patients that have an inadequate response to anti-TNF treatment.<sup>6,7</sup> These treatments have mechanisms of action different than traditional DMARD and anti-TNF agents.

Abatacept is a soluble modulator of costimulation of human origin, directed selectively against the costimulating CD80/CD86:CD28 signal, necessary for activation of T cells. In the ATTAIN trial (Abatacept Trial in Treatment of Anti-TNF INadequate responders), efficacy and security of abatacept in patients with active RA and inadequate response to anti-TNF treatment<sup>7</sup> was measured. At 6 months, the double blind phase of this trial provided the first clues that supported this treatment strategy in TNF inhibitor-non responding patients and

that demonstrated significant improvement, after treatment with abatacept, in signs and symptoms, physical function, and quality of life.<sup>7</sup> Recently, the findings after 2 years of treatment with this drug have been presented<sup>8</sup> and have confirmed the maintained beneficial effects observed at 6 months.

The incidence of severe infections stands out among the adverse events described with this treatment (5 of every 100 patients per year). Pneumonia is among the most frequent infections (incidence over 0.5% of patients).<sup>8</sup>

## Case report

We present the case of a 73-year-old woman without any history of addiction, with a history of arterial hypertension and mild chronic obstructive pulmonary disease for the past 10 years, as well as seronegative RA since 1980 (28 years since onset), without any extra-articular complications. Since her diagnosis she had been treated with gold salts, non-steroidal anti-inflammatory drugs, steroids and, sequentially, with leflunomide, etanercept, adalimumab, and infliximab (12 months with each), suspended due to lack of efficacy in the control of joint symptoms. At the moment of presentation, the patient was being treated with prednisolone (4 mg PO), methotrexate

\* Corresponding author.

E-mail address: javier\_velasco\_montes@hotmail.com (J. Velasco Montes).

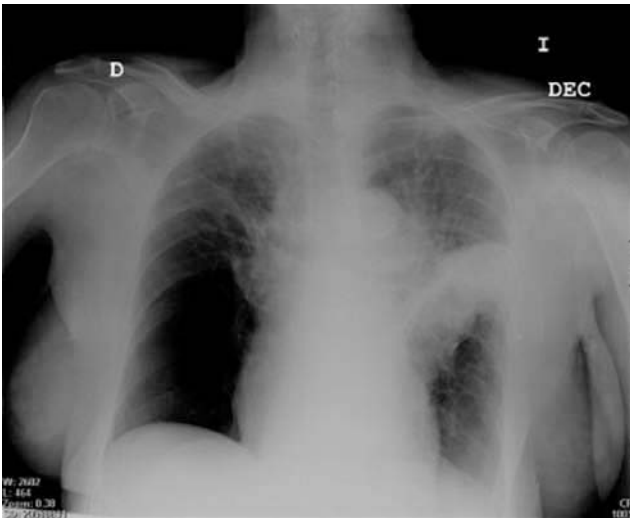


Figure. Posteroanterior thorax x-ray of the patient upon admission.

(15 mg weekly) and, faced with worsening symptoms, abatacept (up until that date she had received 3 intravenous 750 mg doses, with an interval of 2 weeks between them).

On the week of the last dose, the patient presented 38°C fever with productive coughing and pleuritic pain in the left thorax, which intensified progressively, being admitted to the hospital 15 days later. In the complementary tests, there was  $15.4 \times 10^9$  white blood cells (76% segmented) and the chest x-ray revealed an extensive alveolar infiltrate in the left superior lobe which led to a minimal ipsilateral atelectasis. There was also a bullous lesion in the base of the right hemithorax, present on previous x-rays. Serology for *Legionella pneumophila* type 1 antigens, obtained after 2 days, were positive, which led to the continuation of treatment with cefotaxime and levofloxacin which had been installed empirically; in spite of this, the patient presented deterioration of her initial conditions (extension to the contralateral lung in serial x-rays).

Nevertheless, after 15 days of treatment with the previous guideline, besides respiratory intensive physical therapy, it was possible to give him of discharge without other complications.

## Discussion

Treatment with TNF inhibiting agents is associated with an increased risk of infection, especially by intracellular micro-organisms.<sup>9</sup> In this respect, previous studies have described infections due to *Mycobacterium tuberculosis*,<sup>10</sup> *Listeria monocytogenes*,<sup>11</sup> *Aspergillus fumigatus*,<sup>12</sup> *Pneumocystis jirovecii*,<sup>13</sup> *Histoplasma capsulatum*,<sup>14</sup> or *Coccidioides immitis*<sup>15</sup> after the start of TNF inhibiting therapy, although the number of cases described with *Legionella* infection has been less. A French national registry on opportunistic and severe infections only collected 10 cases of pneumonia due to *L pneumophila* during 2004 (6 patients treated with adalimumab, 2 patients treated with etanercept, and 2 patients treated with infliximab), which led to the estimation of the relative risk of infection by *Legionella* to be between 16.5 and 21.<sup>16</sup>

In spite of the fact that infections are widely known to be a complication of the drugs used for the treatment of RA, this is not always true with regard to the new drugs (abatacept among them). In this sense, this case of pneumonia due to *Legionella* associated to the use of abatacept is the first one published in Spain, which is probably due to the short half-life of this drug (approved by the Spanish Agency for Drugs in December 2007 and commercialized since April 2008).

Physicians prescribing abatacept must be on the lookout for the potential appearance of severe infections, such as pneumonia due to *Legionella*.

## References

- Lipsky PE, van der Heijde DM, St Clair EW, Furst DE, Breedveld FC, Kalden JR, et al. Infliximab and methotrexate in the treatment of rheumatoid arthritis. Anti-Tumor Necrosis Factor Trial in Rheumatoid Arthritis with Concomitant Therapy Study Group. *N Engl J Med.* 2000;343:1594-602.
- Weinblatt ME, Kremer JM, Bankhurst AD, Bulpitt KJ, Fleischmann RM, Fox RI, et al. A trial of etanercept, a recombinant tumor necrosis factor receptor: Fc fusion protein, in patients with rheumatoid arthritis receiving methotrexate. *N Engl J Med.* 1999;340:253-9.
- Weinblatt ME, Keystone EC, Furst DE, Moreland LW, Weisman MH, Barbra CA, et al. Adalimumab, a fully human anti-tumor necrosis factor alpha monoclonal antibody, for the treatment of rheumatoid arthritis in patients taking concomitant methotrexate: The ARMADA trial. *Arthritis Rheum.* 2003;48:35-45.
- Maini R, St Clair EW, Breedveld F, Furst D, Kalden J, Weisman M, et al. Infliximab (chimeric anti-tumour necrosis factor alpha monoclonal antibody) versus placebo in rheumatoid arthritis patients receiving concomitant methotrexate: A randomised phase III trial. ATTRACT Study Group. *Lancet.* 1999;354:1932-9.
- Buch MH, Bingham SJ, Bryer D, Emery P. Long-term infliximab treatment in rheumatoid arthritis: Subsequent outcome of initial responders. *Rheumatology (Oxford).* 2007;46:1153-6.
- Cohen SB, Emery P, Greenwald MW, Dougados M, Furie RA, Genovese MC, et al. Rituximab for rheumatoid arthritis refractory to anti-tumor necrosis factor therapy: Results of a multicenter, randomized, double-blind, placebo-controlled, phase III trial evaluating primary efficacy and safety at twenty-four weeks. *Arthritis Rheum.* 2006;54:2793-806.
- Genovese MC, Becker JC, Schiff M, Luggen M, Sherrer Y, Kremer J, et al. Abatacept for rheumatoid arthritis refractory to tumor necrosis factor alpha inhibition. *N Engl J Med.* 2005;353:1114-23.
- Genovese MC, Schiff M, Luggen M, Becker JC, Aranda R, Teng J, et al. Efficacy and safety of the selective costimulation modulator abatacept following 2 years of treatment in patients with rheumatoid arthritis and an inadequate response to anti-tumour necrosis factor therapy. *Ann Rheum Dis.* 2008;67:547-54.
- Hyrich KL, Silman AJ, Watson KD, Symmons DP. Anti-tumour necrosis factor alpha therapy in rheumatoid arthritis: An update on safety. *Ann Rheum Dis.* 2004;63:1538-43.
- Keane J, Gershon S, Wise RP, Mirabile-Levens E, Kasznica J, Schwieterman WD, et al. Tuberculosis associated with infliximab, a tumor necrosis factor alpha-neutralizing agent. *N Engl J Med.* 2001;345:1098-104.
- Slifman NR, Gershon SK, Lee JH, Edwards ET, Braun MM. *Listeria monocytogenes* infection as a complication of treatment with tumor necrosis factor alpha-neutralizing agents. *Arthritis Rheum.* 2003;48:319-24.
- de Rosa FG, Shaz D, Campagna AC, Dellaripa PE, Khettry U, Craven DE. Invasive pulmonary aspergillosis soon after therapy with infliximab, a tumor necrosis factor-alpha-neutralizing antibody: A possible healthcare-associated case?. *Infect Control Hosp Epidemiol.* 2003;24:477-82.
- Tai TL, O'Rourke KP, McWeeney M, Burke CM, Sheehan K, Barry M. *Pneumocystis carinii* pneumonia following a second infusion of infliximab. *Rheumatology (Oxford).* 2002;41:951-2.
- Lee JH, Slifman NR, Gershon SK, Edwards ET, Schwieterman WD, Siegel JN, et al. Life-threatening histoplasmosis complicating immunotherapy with tumor necrosis factor alpha antagonists infliximab and etanercept. *Arthritis Rheum.* 2002;46:2565-70.
- Bergstrom L, Yocum DE, Ampel NM, Villanueva I, Lisse J, Gluck O, et al. Increased risk of coccidioidomycosis in patients treated with tumor necrosis factor alpha antagonists. *Arthritis Rheum.* 2004;50:1959-66.
- Tubach F, Ravaud P, Salmon-Ceron D, Pettipain N, Brocq O, Grados F, et al. Emergence of *Legionella pneumophila* pneumonia in patients receiving tumor necrosis factor-alpha antagonists. *Clin Infect Dis.* 2006;43:e95-e100.