

Images in clinical rheumatology

Massive pleural effusion in systemic lupus erythematosus

Derrame pleural masivo en lupus erimematoso sistémico

Mireya Elizabeth González Leija, * Mauricio Orrantia Vertiz and Miguel Á. Vázquez Zaragoza

Hospital de Especialidades, Centro Médico Nacional Siglo XXI, IMSS, México D.F., Mexico

ARTICLE INFO

Available online September 20, 2009

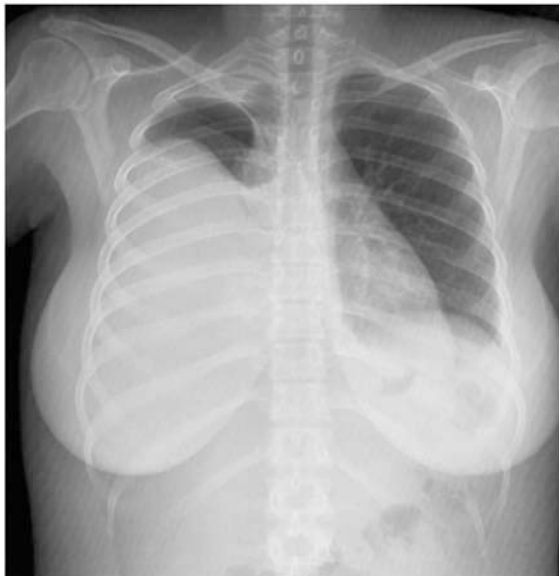

Figure 1. Posteroanterior chest x-ray showing a right pleural effusion.

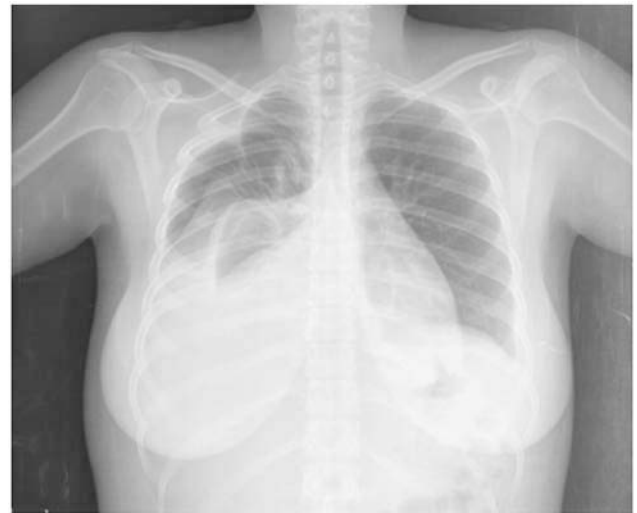

Figure 3. Posteroanterior chest x-ray after thoracocentesis that shows atelectasia and residual effusion.

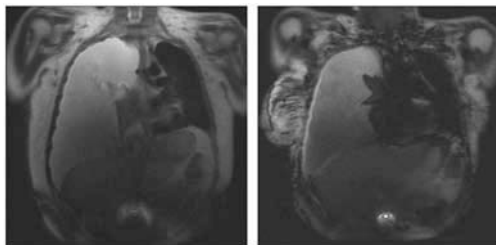


Figure 2. Magnetic resonance image of the thorax with the presence of bilateral pleural effusion with predominance on the right.

Clinical case

A 27-year-old woman, with a 2 month diagnosis of systemic lupus erythematosus (SLE) characterized by hematologic abnormalities (lymphopenia and low platelets), as well as mucocutaneous lesions (hair loss and malar erythema), arthritis, and serositis (pleural and pericardial effusion), with positive antinuclear antibodies (ANA) 1:1.280 with a speckled pattern and positive native anti-DNA >250 U/mL, as well as positive anti-Ro and anti-Sm antibodies, had been receiving treatment with prednisone, 40 mg a day, and azathioprine, 100 mg a day since a month earlier. She came into the clinic due to facial and bilateral maleoli edema, without dyspnea.

A massive right pleural effusion was documented (Figures 1-3), and a diagnostic-therapeutic thoracocentesis was performed. A fluid characterized as an exudate was obtained, with positive

* Corresponding author.

E-mail address: mireyaeli@yahoo.com (M.E. González Leija).

native anti-DNA antibodies >250 U/mL, negative bacterial, fungi and mycobacterial cultures and negative cytology for malignant cells.

Diagnosis and progression

The concluding diagnosis was massive pleural effusion secondary to lupus activity and was treated with prednisone at a dose of 1 mg/kg and furosemide, with patient improvement.

The prevalence of serositis in SLE is of 12%.² Pleural effusions in SLE tend to be small and bilateral and are rarely massive as in this case.² They are exudates with normal glucose, polymorphonuclear cells when the onset is acute, and lymphocytes in chronic disease, proteins >3.5 g/dL and DHL levels lower than those found in rheumatoid arthritis, in which they can reach levels of 1000 U/L.^{6,7} The presence of AAN, anti-DNA antibodies, and LE cells in pleural fluid has been reported.^{1,8,9}

There were high titer of ANA in the pleural effusion (>1:640), something rarely seen in diseases other than SLE.^{3,4,5} Negative or low titers of ANA and anti-DNA in the pleural effusion suggest other diagnoses.

Other causes of pleural effusion must be ruled out, for example infection, pulmonary embolism, heart failure, nephritic syndrome or

neoplasia, before a final diagnosis is made.⁹ In this case, the pleural effusion was solved without the need for pleurodesis.¹⁰

References

1. Pines A, Kaplinsky N, Olchovsky D, Rozenman J, Frankl O. Pleuro-pulmonary manifestations of systemic lupus erythematosus: Clinical features of its subgroups. Prognostic and therapeutic implications. *Chest.* 1985;88:129–35.
2. Man BL, Mok CC. Serositis related to systemic lupus erythematosus: Prevalence and outcome. *Lupus.* 2005;14:822–6.
3. Khare V, Baethge B, Lang S, Wolf RE, Campbell GD. Antinuclear antibodies in pleural fluid. *Chest.* 1994;106:866–71.
4. Porcel JM, Ordi-Ros J, Esquerda A, Vives M, Madroño AB, Bielsa S, et al. Antinuclear antibody testing in pleural fluid for the diagnosis of lupus pleuritis. *Lupus.* 2007;16:25–7.
5. Good JT, King TE, Antony VB, Sahn SA. Lupus pleuritis: Clinical features and pleural fluid characteristics with special reference to pleural fluid antinuclear antibodies. *Chest.* 1983;84:714–8.
6. Alarcón-Segovia D, Alarcón DG. Pleuro-pulmonary manifestations of systemic lupus erythematosus. *Chest.* 1961;39:7–17.
7. Keane MP, Lynch III JP. Pleuropulmonary manifestations of systemic lupus erythematosus. *Thorax.* 2000;55:159–66.
8. Miller LR, Greenberg SD, McLarty JW. Lupus lung. *Chest.* 1985;88:265–9.
9. Middleton JW. Pulmonary manifestations of systemic diseases. *Chest.* 1951;19:473–80.
10. Breuer GS, Deeb M, Fisher D, Neshor G. Therapeutic options for refractory massive pleural effusion in systemic lupus erythematosus: A case study and review of the literature. *Semin Arthritis Rheum.* 2005;34:744–9.