



Original article

Systematic review on the use of adalimumab in autoimmune. Efficacy and safety in 54 patients

Cándido Díaz-Lagares,^a Rafael Belenguer,^b and Manuel Ramos-Casals^{a,*}^aLaboratorio de Enfermedades Autoinmunes Josep Font, Servicio de Enfermedades Autoinmunes, IDIBAPS, Hospital Clinic, Barcelona, Spain^bUnidad de Reumatología, Hospital 9 d'Octubre, Valencia, Spain

ARTICLE INFO

Article history:

Received March 4, 2009

Accepted June 10, 2009

Keywords:

Adalimumab

Autoimmune systemic diseases

Uveitis

ABSTRACT

Objective: To analyze published evidence about adalimumab use in autoimmune diseases.**Methods:** Systematic review of MEDLINE database of citations included from January 1990 to December 2008 employing the terms “adalimumab” and the different systemic autoimmune diseases.**Results:** Our search identified 241 potentially relevant citations. 154 were retrieved for detailed evaluation. Finally, 18 were selected as relevant, including 54 patients. The reported diseases were as follow: Behçet disease in 16 patients, idiopathic uveitis in 13, sarcoidosis in 5, uveitis associated with rheumatologic diseases in 5 (psoriasis in 2, ankylosing spondylitis in 1, juvenile idiopathic arthritis in 1, Crohn disease in 1), Vogt-Koyanagi-Harada disease in 4, Birdshot uveitis in 4, vasculitis in 3 (1 temporal arteritis, 1 Takayasu's disease, 1 skin vasculitis associated with rheumatoid arthritis), adult onset Still disease in 2, relapsing polychondritis in 1 and systemic sclerosis in 1. The clinical spectrum included uveitis (39 cases), skin and/or mucosae (9), vasculitis (3), arthritis (6), lung (3). These patients were refractory to standard therapy, including corticosteroids (42 cases, 78%), immunosuppressants (42, 78%) and biologics (29, 54%). Fifty (93%) patients responded to adalimumab. The clinical response was similar in those patients who had been treated with other biologic and in those who had not received biologic therapy before adalimumab. The patients were followed for 11.9 months. Twelve (22%) patients relapsed. Five (9%) patients suffer some side effect (3 local skin reaction, 1 angioedema, 1 lung fibrosis). One patient (2%) died due to progression of her disease.**Conclusions:** Available data about the use of adalimumab in autoimmune diseases come from case reports and uncontrolled studies, that include patients with severe disease and refractory to standard therapy. In this setting, it seems to be an effective and safe treatment option, especially in patients with uveitis and Behçet's disease. This initial data must be confirmed by controlled assays before extending adalimumab use.

© 2009 Elsevier España, S.L. All rights reserved.

Revisión sistemática del uso de adalimumab en enfermedades autoinmunes. Eficacia y seguridad en 54 pacientes

RESUMEN

Palabras clave:

Adalimumab

Enfermedades autoinmunes sistémicas

Uveitis

Objetivo: Analizar la experiencia publicada sobre el uso de adalimumab en el tratamiento de enfermedades autoinmunes en adultos.**Métodos:** Se realizó una revisión sistemática de los artículos incluidos en la base de datos Medline desde el 1 de enero de 1990 al 31 de diciembre de 2008, combinando el término «adalimumab» con las diferentes enfermedades autoinmunes sistémicas. Se identificaron un total de 241 artículos, de los que 154 se revisaron a texto completo y 18 fueron finalmente seleccionados como relevantes.**Resultados:** En los 18 artículos seleccionados se incluían 54 pacientes adultos con enfermedades autoinmunes tratados con adalimumab: 16 pacientes con enfermedad de Behçet; 13 con uveítis idiopática; 5 con sarcoidosis; 5 con uveítis asociadas a otras enfermedades (psoriasis en 2, espondilitis anquilosante en 1, artritis idiopática juvenil en 1, enfermedad de Crohn en 1); 4 con enfermedad de Vogt-Koyanagi-Harada; 4 con uveítis de Birdshot; 3 con vasculitis (arteritis de la temporal, enfermedad de Takayasu y una vasculitis cutánea asociada a artritis reumatoide), 2 con enfermedad de Still del adulto; uno con policondritis

* Corresponding author.

E-mail address: mramos@clinic.ub.es (M. Ramos-Casals).

recidivante y un paciente con esclerosis sistémica. Las manifestaciones clínicas que motivaron la indicación fueron la uveítis (39 casos), afectación mucocutánea (9), vasculitis (3), artritis (6) y afectación pulmonar (3). En todos los casos se trataba de enfermedades refractarias a tratamiento con glucocorticoides (42 casos, 78%), inmunosupresores (42,78%) y otros biológicos (29,54%). Cincuenta (93%) pacientes respondieron a adalimumab. La respuesta fue similar tanto en aquellos que habían recibido otro biológico como en los que adalimumab era el primer biológico administrado. En 5 (9%) pacientes se describieron efectos adversos (3 reacciones cutáneas locales, un paciente con angioedema y una exacerbación de una fibrosis pulmonar). Tras un tiempo medio de seguimiento de 11,9 meses, 12 (22%) pacientes presentaron recidiva y uno (2%) falleció por exacerbación de su enfermedad de base.

Conclusiones: La evidencia del uso de adalimumab en enfermedades autoinmunes proviene de casos aislados y ensayos no controlados, que incluyen en todos los casos a pacientes graves y refractarios a tratamiento convencional. En este contexto clínico, el uso de adalimumab aparece como una opción eficaz y segura, especialmente en pacientes con uveítis y enfermedad de Behçet.

© 2009 Elsevier España, S.L. Todos los derechos reservados.

Introduction

Cytokines are molecules that are essential for the normal functioning of the immune system. An imbalance in production, caused by exposure to certain environmental factors in a genetically predisposed host, has been linked to the pathogenesis of autoimmune diseases.^{1,2} The factor tumor necrosis (TNF) is a cytokine produced mainly by monocytes, macrophages and T lymphocytes, which exerts its action by binding to two receptors (p55 and p75) present on the membrane of neutrophils, endothelial cells and fibroblasts. This binding promotes the release of other mediators by target cells, amplifying the signal and contributing to produce inflammation and tissue damage.³ Knowledge of the role of TNF has been the basis for the design and use of anti-TNF drugs in diseases of an autoimmune nature.

Anti-TNF drugs currently approved by international drug regulating agencies are infliximab (a monoclonal IgG1 chimeric mouse and human antibody), etanercept (a recombinant fusion protein that combines two p75 TNF receptors, and the Fc domain of a human IgG1) and adalimumab (a fully humanized IgG1 monoclonal antibody). Adalimumab and infliximab have a similar mechanism of action and effectively bind both the soluble form as well as the transmembrane form of TNF, whereas etanercept binds only to the soluble form of TNF. Adalimumab and etanercept are administered subcutaneously and can be administered at home, providing stable and continuous plasma levels, while infliximab requires intravenous administration in the hospital.⁴

International regulating agency approved indications for the use of anti-TNF include rheumatoid arthritis, Sjögren's syndrome, ankylosing spondylitis, psoriatic arthritis, juvenile chronic arthritis, inflammatory bowel disease and psoriasis.^{5,6} In clinical practice, the use of these therapies has recently been extended to systemic autoimmune disease resistant to conventional treatment and, in an administrative context, of off-label use (compassionate hospital-use with approval by the Ministry of Health).

Adalimumab is the first fully human anti-TNF monoclonal antibody, with a structure and function indistinguishable from human IgG1 and a half-life that is also similar (approximately 2 weeks).⁷ The FDA and the EMEA endorse the use of adalimumab in rheumatoid arthritis, psoriatic arthritis, ankylosing spondylitis, psoriasis, juvenile chronic arthritis and inflammatory bowel disease.⁶ However, there is no known scientific evidence for the use of adalimumab in autoimmune diseases.

The aim of this study is to gather information about the efficacy and safety of adalimumab in systemic autoimmune diseases through a systematic review of the literature.

Materials and methods

We conducted a systematic review of the Medline database through the PubMed website (<http://www.ncbi.nlm.nih.gov>) of articles published from 1 January 1990 to December 31 2008 by combining the following terms: "adalimumab", "antiphospholipid syndrome", "Behçet disease", "Churg Strauss vasculitis", "myositis", "polymyositis", "dermatomyositis", "giant cell arteritis", "Horton arteritis", "systemic lupus erythematosus", "rheumatic polymyalgia", "Relapsing polychondritis", "sarcoidosis", "Sjogren's syndrome", "Still's disease", "adult-onset Still's disease", "systemic sclerosis", "Wegener's granulomatosis", "uveitis", "vasculitis", "progressive glomerulonephritis", "polyarteritis nodosa", "microscopic polyangiitis", "cryoglobulinemia", and "antisynthetase syndrome".

No filters were set for the language of publication or type of study. As a first step we analyzed the content of the abstracts of the identified articles. We then selected all articles that made reference to patients with autoimmune diseases for full text review. No information was extracted for evaluation from abstracts or unpublished results (*in press*, personal communications). After reviewing the full text articles, they were considered as relevant for inclusion into the study based on the following premises:

- The article should refer to adult patients (age > 18 years) with autoimmune diseases treated with adalimumab.
- Information contained in the article should allow the assessment of treatment response and adverse events.
- In the case of reviews, those that did not include unpublished original cases were not regarded as relevant
- In case of duplicate articles, we selected the most recent.

We define favorable response as improvement or stabilization of the clinical indication for which adalimumab was prescribed. Complete resolution of all manifestations was considered as complete response, and in the other cases, as partial response. Response was defined as unfavorable when clinical progression persisted despite treatment.

Results

We identified a total of 241 articles by combining the search terms previously described, of which 154 (63.9%) were reviewed in full text. Following this review, 18 items were considered as relevant to the study, and which reported a total of 54 adult patients with autoimmune diseases treated with adalimumab⁸⁻²⁵ (Figure).

1) General features

Of the 54 patients, 34 were women and 20 men with a mean age of 39.72 years at the time of initiation of treatment with adalimumab (1921-1974). Autoimmune diseases and general characteristics of their illness are listed in Table 1.

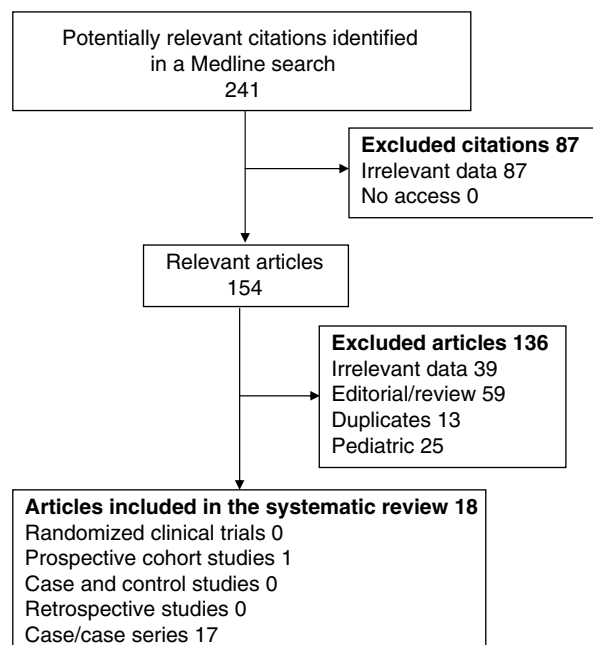


Figure 1. Systematic review flow chart.

The clinical manifestations for which the treatment was indicated included uveitis, 39 cases (72%), skin lesions 9 (17%), vasculitis in four (7%), arthritis in 4 (7%), pulmonary 3 (5%), disorders of the gastrointestinal tract in 2 (4%) and central nervous system involvement in 2 cases (4%). They were all the cases of patients who had failed conventional treatment with corticosteroids, immunosuppressants and / or other biological treatments. Forty-two (78%) patients had been treated with glucocorticoids, 42 (78%) with immunosuppressants (31 had received methotrexate, 25 cyclosporin A, 6 azathioprine, 7 methotrexate, 4 mycophenolate mofetil, 4 chlorambucil, 2 hydroxychloroquine, 2 leflunomide, 2 pentoxifylline, 1 colchicine, 1 minocycline) and 29 (54%) had received other biological treatment (15 had received infliximab, 7 etanercept and 8 daclizumab). The dose used was 40mg of adalimumab sc (bi-weekly in 46 patients and weekly in 4). In four cases the dose was not specified.

Clinical response to adalimumab treatment was favorable in 50 (93%) patients. Only 4 patients did not respond to treatment: one patient had Vogt-Koyanagi-Harada uveitis, one with psoriatic arthritis, a patient with adult Still's disease and one with scleroderma. The response rate was similar in patients who had been treated with other biological in relation to those without (93% vs 92%, $P=0.843$). The dose of glucocorticoid and / or immunosuppressants was reduced in 43 (80%) of 48 patients for whom this information was specified.

The mean follow up of patients was 11.9 months, ranging from 2 to 48 months. During this time, relapse was observed in 12 (22%) patients (9 cases of posterior uveitis, one of idiopathic anterior uveitis, a case of Behçet disease with systemic manifestations

Table 1

Autoimmune diseases in which adalimumab has been employed

Autoimmune disease	n (%)	Prior immunosuppressants	Prior biologics	Response	Adverse events	Relapse	Follow up, months
1. Behçet's disease	16 (29.6%)	11 mtx., 11 cs. A, 3 cfm., 3 aza., 3 clor., 1 mmf., 1 colchicine, 1 thalidomide	9 infliximab, 3 etanercept	16 (100%)	4 (25%): 3 lichenoid reactions, 1 angioedema	3 (19%)	13.5
2. Idiopathic uveitis	13 (24.1%)	10 mtx., 12 cs. A, 3 mmf., 2 aza., 1 clor.	6 daclizumab, 3 etanercept, 1 infliximab	13 (100%)	0 (0%)	6 (46%)	10.6
3. Sarcoidosis	5 (9.3%)	4 mtx., 2 hcq., 1 cs. A, 1 cfm., 1 minocycline, 1 pentoxifylline	1 daclizumab	5 (100%)	0 (0%)	0 (0%)	11.6
4. Birdshot uveitis	4 (7.4%)	2 mtx., 2 cs. A	1 daclizumab	4 (100%)	0 (0%)	0 (0%)	9.5
5. Vogt-Koyanagi-Harada disease	4 (7.4%)	4 cs. A, 2 mtx., 1 aza., 1 clor.	1 infliximab, 1 daclizumab	3 (75%)	0 (0%)	1 (25%)	9.5
7. Adults Still's disease	2 (3.7%)	2 mtx., 1 cs. A, 1 cfm.	1 infliximab, 1 etanercept	1 (50%)	0 (0%)	0 (0%)	9
8. Psoriatic uveitis	2 (3.7%)		1 etanercept	1 (50%)	0 (0%)	0 (0%)	10
9. Relapsing polychondritis	1 (1.9%)	1 aza., 1 mtx., 1 cfm., 1 mmf., 1 cs. A	1 infliximab	1 (100%)	0 (0%)	0 (0%)	48
10. Systemic sclerosis	1 (1.9%)	1 mtx., 1 aza., 1 leflu.		0 (0%)	1 (100%) Lung fibrosis	0 (0%)	13
11. Uveitis associated to ankylosing spondylitis	1 (1.9%)	1 mtx.		1 (100%)	0 (0%)	0 (0%)	24
12. Uveitis associated to juvenile chronic arthritis	1 (1.9%)	1 mtx.		1 (100%)	0 (0%)	0 (0%)	18
13. Uveitis associated to Chron's disease	1 (1.9%)	1 mtx.		1 (100%)	0 (0%)	1 (100%)	12
14. Temporal arteritis	1 (1.9%)	1 mtx.		1 (100%)	0 (0%)	0 (0%)	6
15. Takayasu's arteritis	1 (1.9%)	1 mtx., 1 cfm.	1 infliximab	1 (100%)	0 (0%)	0 (0%)	8
16. Skin vasculitis associated to rheumatoid arthritis	1 (1.9%)	1 mtx., 1 leflu.	1 infliximab, 1 etanercept	1 (100%)	0 (0%)	0 (0%)	8

aza. indicates azathioprine; cfm., cyclophosphamide; clor., chlorambucil; cs. A, cyclosporine A; hcq., hydroxychloroquine; leflu., leflunomide; mmf., mycophenolate mofetil; mtx., methotrexate.

without ocular involvement and one case of cutaneous vasculitis associated with rheumatoid arthritis). 5 (9%) patients presented adverse events (three lichenoid skin reactions, one with a skin reaction associated to angioedema and one in a patient in whom there was an exacerbation of underlying pulmonary fibrosis). The same patient (2%) died due to the exacerbation of the underlying lung disease.

2) Uveitis

We identified 39 patients with uveitis treated with adalimumab, of which 19 were included in a nonrandomized uncontrolled trial,⁸ the remaining belonging to six series of cases.^{9-12,24,25} The etiology of uveitis was: 18 cases associated with other diseases (Behçet's disease in 11 patients, sarcoidosis in 2, 2 psoriasis and Crohn's disease, ankylosing spondylitis and juvenile idiopathic arthritis in one patient respectively), 13 idiopathic uveitis, 8 primary uveitis (Vogt-Koyanagi-Harada disease in 4 uveitis patients and Birdshot uveitis in 4 patients). Of the 39 patients, 21 were male and 18 female with a mean age of 38.6 years (21-74). The location of uveitis was specified in 37 cases: 24 cases (61%) had panuveitis, seven (18%) had posterior uveitis, 3 patients (8%) had intermediate uveitis and 3 patients (8%) had anterior uveitis. Of the 27 patients in which the condition was specified to be unilateral or bilateral, 26 (96%) presented bilateral uveitis.

In 37 patients, the previous treatment characteristics were specified. All but four had been treated with glucocorticoids and a mean of 1.74 immunosuppressants (23 patients had received cyclosporin A, 20 methotrexate, 5 azathioprine, 4 chlorambucil, 3 cyclophosphamide and 3 mycophenolate). Twenty (51%) patients had been treated with other biologics (infliximab in 7 cases, 7 daclizumab and 6 etanercept). The associated treatment was specified in 19 cases. In all but one glucocorticoids were used, which in 15 cases were associated with another immunosuppressant (methotrexate in 12, azathioprine in 1, 1 mycophenolate mofetil and cyclosporine in 1).

Thirty-seven (95%) patients had a favorable clinical response: 27 (69%) experienced clinical improvement and 10 (26%) were clinically stabilized. 2 (5%) remaining patients showed clinical deterioration in one of the two affected eyes despite treatment. Table 2 summarizes the response rate by etiology of uveitis. Table 3 summarizes the different definitions of response in different studies.

As for the overall response rate, no significant differences between patients who had previously been treated with a biologic (95%) and those without (94.7%). In contrast, patients not previously treated with biological showed a higher rate of clinical improvement in visual (89.5% vs 50%, $P=0.007$) than those who had received biological.

The mean follow up of patients was 12.6 months (4-30). During this time, 10 (27%) patients experienced at least one relapse, which responded to the periocular injection of corticosteroids in the eight cases that specified the management of the relapse. No adverse effects were reported except for minor local reactions at the injection site.⁸

The work of Díaz-Llopis et al⁸ is the best designed and largest to date. This is a prospective nonrandomized uncontrolled trial that included 19 patients with bilateral chronic uveitis of various etiologies, which were refractory to treatment with corticosteroids, immunosuppressants and biological agents. Results from 38 affected eyes showed visual acuity improvement in 12 (31%), stabilization in 25 (66%) and worsening in one (3%). Chronic cystoid macular edema was resolved in 54% of affected eyes. In addition, all patients were able to decrease immunosuppressants by at least 50% of the dose. During the 12 month follow-up of this study, eight patients (42%) had recurrence, which was controlled by injection of periocular corticosteroids in all cases. No adverse events were seen except mild local reactions at the injection site. A study with similar results, albeit retrospective, is that of Callejas-Rubio et al²⁴; a series of 10 refractory patients with uveitis of different etiologies. In their series, all patients were treated with concomitant methotrexate, except two who received pulse steroids. All patients (100%) had improvement of ocular inflammation and visual acuity. Only two patients (20%) relapsed, and adverse events were not described.

3) Behçet's Disease

Sixteen patients with Behçet's disease were treated with adalimumab^{8,10,11,20,24} (10 men and 6 women, mean age of 38.18 years). In terms of clinical manifestations, 11 patients had uveitis (9 as the only manifestation), 6 had oral and/or genital ulcers, two arthritis, 2 had CNS manifestations, two digestive affection in the form of esophagitis or colitis and one had vasculitis. The 9 patients treated exclusively due to ocular manifestations have been analyzed in a previous section. Of the 7 patients treated

Table 2
Response to adalimumab in patients with uveitis according to etiology

Pathology	No. of cases	Response	Relapse
Idiopathic	13	13 (100%)	6 (46.1%)
Behçet	11	11 (100%)	2 (18.2%)
Vogt-Koyanagi-Harada	4	3 (75%)	1 (25%)
Birdshot	4	4 (100%)	0 (0%)
Sarcoidosis	2	2 (100%)	0 (0%)
Ankylosing spondylitis	1	1 (100%)	0 (0%)
Idiopathic juvenile arthritis	1	1 (100%)	0 (0%)
Crohn's disease	1	1 (100%)	1 (100%)
Psoriasis	2	1 (50%)	0 (0%)

Table 3
Definition of response in those studies that included patients with uveitis

Author	Type of study	n	Classification of the type of response	Parameters used to evaluate response
Díaz-Llopis ⁸	Prospective, uncontrolled	19	Improvement Stability Worsening	Visual acuity (+/-0.3 log.) Ocular inflammation (+/-2)
Petropoulos ⁹	Clinical case	2	Improvement Stability Worsening	Macular edema (change in thickness of fovea) Visual acuity (0-1) Clinical
Díaz-Llopis ¹²	Clinical case	1	Absence of relapse, allows suspension of other drugs	Macular edema Fluorescein
Mushtaq ¹⁰	Clinical case	3	Undefined	Visual acuity (before, not post-treatment)
Van Laar ¹¹	Clinical case	2	Partial response "½" Complete response "0"	Visual acuity (before and post-treatment) No information on any parameter
Callejas-Rubio ²⁴	Descriptive study	10	"Improvement of visual acuity and eye inflammation"	No information on any parameter
Huynh ²⁵	Retrospective	2	Remission: no anterior or posterior inflammation, no macular edema	Visual acuity (scale log.) Macular inflammation (0/+3)

with adalimumab for extraocular manifestations, all had received glucocorticoids and immunosuppressive therapy (3 had received methotrexate, two cyclosporin A, one colchicine, one thalidomide and one azathioprine). All patients except one had previously been treated with infliximab.

Clinical response was favorable in all patients (56% were classified as total and 44% as partial). Response according to clinical manifestation is shown in Table 4. 5 of the 6 patients managed to reduce the dose of immunosuppressant. Follow-up time was 13.2 months (range 3–26 months), during which one of the patients relapsed (14%). Four (57%) patients experienced adverse effects which in 3 patients consisted of lichenoid type cutaneous lesions and were controlled with local steroids, and in one patient consisted of urticaria with angioedema that required the administration of intravenous steroids and antihistamines, leading to the discontinuation of treatment.

4) Sarcoidosis

Five patients with sarcoidosis and were treated with adalimumab^{8,9,17–19} (3 women and 2 men, mean age 43.2 years). In terms of clinical manifestations, two had severe skin involvement with facial nodules and ulcers in the lower limbs in one case, and ulcers of the lower limbs in the other, another 2 had bilateral uveitis with significant visual impairment, and one patient had interstitial lung disease. All had previously received corticosteroids and immunosuppressants (4 methotrexate, one cyclophosphamide, one cyclosporine). One of the patients with ocular involvement was also treated with daclizumab. Adalimumab administration was weekly in the 2 patients with cutaneous manifestations and standard in the other 3 patients (40 mg sc every 2 weeks). As for the associated treatment, 2 patients received corticosteroids, one received glucocorticoids and methotrexate and another received pentoxifylline and hydroxychloroquine. We have no information in one patient.

All patients responded favorably within 2 weeks to 2 months. There were no recurrences or adverse events during follow-up, which was 11.6 months. Table 5 summarizes the response of these patients

5) Vasculitis

Three patients with vasculitis have been treated with adalimumab (13 with temporal arteritis, 14 with Takayasu's arteritis and 15 with cutaneous vasculitis associated to rheumatoid arthritis). All cases were women, with a mean age of 55 years (35–70). The areas affected were the supra-aortic vessels, aorta and skin. The 3 cases were patients who presented therapeutic failure to conventional therapy. The patient with temporal arteritis and Takayasu's arteritis had previously received corticosteroids and immunosuppressants, and in the case of the latter, he had been treated with infliximab also. The patient with rheumatoid arthritis associated vasculitis was previously treated with methotrexate, infliximab and etanercept. Full remission of the symptoms was achieved in the three patients. In patients with large vessel vasculitis a reduction in immunosuppressive therapy was achieved. Follow-up time was 10 months (6–16), during which there were no relapses or adverse events.

Table 4

Response of patients with Behçet's disease according to clinical manifestations

Clinical	Cases	Complete response	Partial response
Oral ulcers	7	4 (57.1%)	3 (42.8%)
Genital ulcers	5	2 (40%)	3 (60%)
Papulopustular skin affection	3	2 (66.7%)	1 (33.3%)
Arthritis	3	2 (66.7%)	1 (33.3%)
CNS	2	2 (100%)	0 (0%)
Digestive	2	1 (50%)	1 (50%)
Vasculitis	1	0 (0%)	1 (100%)

Table 5

Response of patients with sarcoidosis according to clinical manifestations

Clinical	Cases	Response	Relapse
Skin affection	2	2 (100%)	0 (0%)
Uveitis	2	2 (100%)	0 (0%)
Pulmonary	1	1 (100%)	0 (0%)

6) Other autoimmune diseases

The use of adalimumab in 2 patients with adult Still's disease (one patient with favorable clinical response²² and one with no response²³ has been described, one with relapsing polychondritis (good response)¹⁶ and another in a patient with systemic sclerosis (slight improvement of joint symptoms, but death from baseline lung disease progression).²¹

Discussion

Since the introduction of adalimumab and until December 2008 there have been a total of 54 patients with autoimmune diseases treated *off-label* with adalimumab. The data comes from reports of isolated cases, case series and uncontrolled prospective studies, which included patients with failure to conventional treatment with corticosteroids and immunosuppressive drugs and even with other biological treatments. The two entities with a greater number of reported cases are uveitis and Behçet's disease, followed by sarcoidosis and vasculitis, and other isolated diseases such as adult Still's disease, relapsing polychondritis and scleroderma.

The data of our review shows a greater than 90% response in patients treated with adalimumab, with a low incidence of adverse events, which in most patients corresponds to local skin reactions at the injection site. Results are similar to those obtained with infliximab in the different diseases studied,^{26,27} but higher than those observed with etanercept in the treatment of uveitis^{28–32} (efficacy between 78%–100% for infliximab vs 33% to 65% for etanercept in the treatment of uveitis) and sarcoidosis²⁶ (efficacy of 97% for infliximab and 29% for etanercept). This could be due to the different mechanism of action of etanercept, which blocks only the soluble form of TNF.

Uveitis is the clinical entity with the largest number of cases reported in Medline and treated with adalimumab, a total of 39. The first reported cases of uveitis treated with adalimumab^{33,34} correspond to the pediatric population; two studies that included 32 children with uveitis showed an efficacy above 80%.

As for the experience in adults, published data so far shows similar or even higher efficacy than in children, with a high response rate and a low rate of adverse effects.

The study by Díaz-Llopis et al⁸ is the best designed and the largest to date. In this study, chronic cystoid macular edema, one of the lesions associated with ocular inflammation and more resistant to treatment, was resolved in 54% of affected eyes, which can be superimposed to the previous data seen with infliximab.³⁵

An important limitation when drawing conclusions from the different studies lies in the heterogeneity of patients and the different scales of measurement employed when measuring the response of uveitis to treatment.

The next illness, in terms of the amount of experience reported for adalimumab, was Behçet's disease and there are a total of 16 cases published cases,^{8,10,11,20,24} of which 11 are uveitis (9 as the only manifestation and 2 accompanied by systemic disease). The response was positive in all patients and for all manifestations. Adverse events were limited to mild skin reactions at the injection site, except one patient who had a severe reaction in the form of urticaria and angioedema that prompted the suspension of treatment.

One advantage of adalimumab is the possibility of subcutaneous administration. This advantage is addressed in the work of Van Laar et al¹¹ and Mustaq et al.¹⁰ In them, a total of 9 patients with refractory Behçet's disease with uveitis and/or other systemic manifestations were initially treated with infliximab and presented a good response. In the series of Van Laar, after presenting a new relapse, infliximab was switched to adalimumab, given its greater ease of administration, achieving results similar to those previously obtained with infliximab. In the work of Mustaq et al, because of the difficulties associated to its use, infliximab was replaced by adalimumab after a period of clinical stability, maintaining the response in all cases.

Other conditions in which we find a smaller number of cases reported are sarcoidosis,^{8,9,17–19} vasculitis,^{13–15} adult Still's disease,^{22,23} systemic sclerosis¹⁶ and relapsing polychondritis,²¹ proving effective in all except in systemic sclerosis. In the case of sarcoidosis, the case studies show a favorable response for different clinical manifestations. Initial studies with infliximab is also obtained similar results which a later trial did not confirm.²⁶ On the experience with etanercept, in uncontrolled and controlled trials, a low efficacy was seen for the treatment of sarcoidosis.²⁶

With regard to vasculitis, infliximab and etanercept, as adalimumab, have proven effective in the treatment of temporal arteritis^{36–39} and Takayasu's disease^{40–44} in previous case series and uncontrolled trials. However, two randomized controlled trials showed no differences when compared to placebo.^{45,46}

The efficacy of adalimumab in the different diseases studied is especially important because patients achieve response after multiple treatments that ended in failure, and in which therapeutic options have been exhausted. Particularly instructive in this regard is the patient with aortitis secondary to relapsing polychondritis,¹⁶ refractory to glucocorticoids, 5 immunosuppressants (azathioprine, methotrexate, cyclophosphamide, cyclosporine and mycophenolate) and infliximab, and who presented a complete remission after starting adalimumab.

Another aspect to consider is that when there is a lack of response to an anti-TNF, either by primary failure, loss of efficacy or development of adverse events, there does not appear to be a lack of response to other anti-TNF drugs, as demonstrated in previous studies.^{47,48} The results of our review show the same tendency. Of the 29 patients who had previously failed other biologic drugs, all but two responded favorably to adalimumab. Although in patients with uveitis and Behçet disease, with data that allow stratification of partial and complete responses, there was a higher proportion of partial and less than complete responses than in those who had already failed another biological drug therapy.

The reported adverse events, low in frequency and severity, are consistent with those described in the literature, consisting mainly of mild skin reactions at the injection site. The 100% human nature of adalimumab confers a lower risk of developing allergic reactions than with infliximab. However, although smaller, the risk exists and, in one of the reported cases, one patient presented angioedema related to drug administration, which required intravenous drug administration and discontinuation of treatment. Adalimumab, like the rest of anti-TNF therapy increases the risk of infection, especially *Mycobacterium tuberculosis*. This risk can be reduced substantially with screening for latent tuberculosis and appropriate prophylaxis.⁴⁹ In the series of Díaz-Llopis,⁸ three patients had latent tuberculosis after the initial screening. Before starting treatment with adalimumab, they received isoniazid prophylaxis and none developed the infection. An adverse event in which there is clear participation of adalimumab was seen in the patient with scleroderma who developed pulmonary fibrosis, as the authors could not exclude an infection or progression of the underlying disease. 24 cases have been reported in association to development and/or progression of interstitial lung disease in

patients with rheumatic and/or digestive diseases treated with anti-TNF.⁵⁰

In summary, current information on the use of adalimumab for autoimmune diseases includes 54 cases reported mostly as isolated, a series of cases and an uncontrolled study of patients resistant to conventional treatment. In this context, it has proved to be a safe and effective drug, with a greater cumulative experience in patients with uveitis and Behçet's disease. Adalimumab appears to have an efficacy profile similar to infliximab in the diseases in which it has been used so far. In contrast, etanercept appears to be less effective in the treatment of uveitis and sarcoidosis. At this moment, and expecting the results of clinical trials that confirm previous findings, current scientific evidence does not allow for the recommendation of adalimumab as the first option in the treatment of systemic autoimmune diseases. The clinical scenario for the use of adalimumab is restricted to cases which are resistant to conventional therapy with steroids and immunosuppressants, and in those patients who have failed other anti-TNF drugs, due to either lack of efficacy or to the development of adverse events.

Disclosures

CDL and MRC form part of the BIOGEAS project, which has received financing from ROCHE and ABBOTT.

References

- O' Shea JJ, Averil M, Lypsky P. Cytokines and autoimmunity. *Nat Immunol*. 2002;2:37–45.
- Davidson A, Diamond B. Autoimmune diseases. *N Engl J Med*. 2001;345:340–50.
- Bazzoni F, Beutler B. The tumor necrosis factor ligand and receptor families. *N Engl J Med*. 1996;334:1717–25.
- Olsen N, Stein CM. New drugs for rheumatoid arthritis. *N Engl J Med*. 2004;350:2167–79.
- Furst DE, Breedveld FC, Kalden JR, Smolen JS, Burmester GR, Sieper J, et al. Updated consensus statement on biological agents for the treatment of rheumatic diseases, 2007. *Ann Rheum Dis*. 2007;66(Suppl III):ii2–22.
- Kuek A, Hazleman BL, Östör A. Immune-mediated inflammatory diseases (IMIDs) and biologic therapy: a medical revolution. *Postgrad Med J*. 2007;83:251–60.
- Rau R. Adalimumab (a fully human anti-tumor necrosis factor alpha monoclonal antibody) in the treatment of active rheumatoid arthritis: the initial results of five trials. *Ann Rheum Dis*. 2002;61(Suppl II):ii70–3.
- Díaz-Llopis M, García-Delpech S, Salom D, Udaondo P, Hernández-Garfella H, Bosch-Morell F, et al. Adalimumab therapy for refractory uveitis: a pilot study. *J Ocul Pharmacol Ther*. 2008;24:351–61.
- Petropoulos IK, Vaudaux D, Guex-Crosier Y. Anti-TNF alpha therapy in patients with chronic non infectious uveitis: the experience of Jules Gonin Eye Hospital. *Klin Monatsbl Augenheilkd*. 2008;225:457–61.
- Mushtaq B, Saeed T, Situnayake S, Murray PL. Adalimumab for sight threatening uveitis in Behçet disease. *Eye*. 2007;21:824–5.
- Van laar JAM, Missotten T, Van Daele PLA, Jammitski A, Baarsma GS, Van Hagen PM. Adalimumab: a new modality for Behçet's disease? *Ann Rheum Dis*. 2007;66:565–6.
- Díaz Llopis M, Amselem L, Romero FJ, García-Delpech S, Hernández ML. Tratamiento con adalimumab-nuevo anti-TNF- del síndrome de Vogt-Koyanagi-Harada. Adalimumab therapy for Vogt-Koyanagi-Harada. *Arch Soc Esp Ophthalmol*. 2007;82:131–2.
- Ahmed MM, Mubashir E, Hayat S, Fowler M, Berney SM. Treatment of refractory temporal arteritis with adalimumab. *Clin Rheumatol*. 2007;26:1353–5.
- Tato F, Rieger J, Hoffman U. Refractory Takayasu's arteritis successfully treated with the human, monoclonal anti-tumor necrosis factor antibody adalimumab. *Int Angiol*. 2005;24:304–7.
- Thirion L, Picard D, Mejjad O, Courville P, Le Loet X, Joly P. Vasculite avec ulcérations cutanées au cours de la polyarthrite rhumatoïde: traitement par anti TNF. *Ann Dermatol Venerol*. 2006;133:453–5.
- Seymour MW, Home DM, Williams RO, Allard SA. Prolonged response to anti-tumor necrosis factor treatment with Adalimumab (Humira) in relapsing polychondritis complicated by aortitis. *Rheumatology (Oxford)*. 2007;46:1738–9.
- Heffernan MP, Smith DI. Adalimumab for treatment of cutaneous sarcoidosis. *Arch Dermatol*. 2006;146:17–9.
- Callejas-Rubio JL, Ortego-Centeno O, López-Pérez L, Benticuaga MN. Treatment of therapy-resistant sarcoidosis with adalimumab. *Clin Rheumatol*. 2006;25:596–7.
- Philips MA, Lynch J, Azmi FH. Ulcerative cutaneous sarcoidosis responding to adalimumab. *J Am Acad Dermatol*. 2005;53:917.
- Sánchez-Cano D, Callejas-Rubio JL, Ortego-Centeno N, Ruiz-Villaverde R. Urticaria and angioedema in a patient with Behçet's disease treated with adalimumab. *Clin Exp Rheumatol*. 2007;25:507–8.

21. Allanore Y, Devos-Francois G, Caramella C, Boumier P, Jounieaux V, Kahan A. Fatal exacerbation of fibrosing alveolitis associated with systemic sclerosis in a patient treated with adalimumab. *Ann Rheum Dis.* 2006;65:834-5.
22. Dechant C, Schauenberg P, Antoni CE, Kraetsch HG, Kalden JR, Manger B. Longterm outcome of TNF blockade in adult-onset Still's disease. *Dtsch Med Wochenschr.* 2004;129:1308-12.
23. Benucci M, Li GF, Del Rosso A, Manfredi M. Adalimumab (anti-TNF-alpha) therapy to improve the clinical course of adult-onset Still's disease: the first case report. *Clin Exp Rheumatol.* 2005;23:733.
24. Callejas-Rubio JL, Sánchez-Cano D, Serrano JL, Ortego-Centeno N. Adalimumab therapy for refractory uveitis: a pilot study. *J Ocul Pharmacol Ther.* 2008;24:613-4.
25. Huynh N, Cervantes-Castañeda RA, Bhat P, Gallagher MJ. Biologic response modifier therapy for psoriatic ocular inflammatory disease. *Ocul Immunol Inflamm.* 2008;16:89-93.
26. Ramos-Casals M, Brito-Zerón P, Muñoz S, Soto MJ, y el BIOGEAS Study Group. A systematic review of the off-label use of biological therapies in systemic autoimmune diseases. *Medicine (Baltimore).* 2008;87:345-64.
27. Imrie FR, Dick AD. Biologics in the treatment of uveitis. *Curr Opin Ophthalmol.* 2007;18:481-6.
28. Galor A, Pérez VL, Hammel JP, Lowder CY. Differential effectiveness of etanercept and infliximab in the treatment of ocular inflammation. *Ophthalmology.* 2006;113:2317-23.
29. Schmeling H, Horneff G. Etanercept and uveitis in patients with juvenile idiopathic arthritis. *Rheumatology (Oxford).* 2005;44:1008-11.
30. Saurenmann RK, Levin AR, Rose JB, Parker S, Rabinovitch T, Tyrrell PN, et al. Tumor necrosis factor alpha inhibitors in the treatment of childhood uveitis. *Rheumatology (Oxford).* 2006;45:982-9.
31. Foeldvari I, Nielsen S, Kummerle-Deschner J, Espada G, Horneff G, Bica B, et al. Tumor necrosis factor-alpha blocker in treatment of juvenile idiopathic arthritis-associated uveitis refractory to second-line agents: results of a multinational survey. *J Rheumatol.* 2007;34:1146-50.
32. Guignard S, Gossec L, Salliot C, Ruysen-Witrand A, Luc M, Duclos M, et al. Efficacy of tumour necrosis factor blockers in reducing uveitis flares in patients with spondylarthropathy: a retrospective study. *Ann Rheum Dis.* 2006;65:1631-4.
33. Biester S, Deuter C, Michels H, Haefner R, Kummerle-Deschner J, Doychova D, et al. Adalimumab in the therapy of uveitis in childhood. *Br J Ophthalmol.* 2007;91:319-24.
34. Vazquez-Cobian LB, Flynn T, Lehman TJA. Adalimumab therapy for childhood uveitis. *J Pediatr.* 2006;149:572-5.
35. Markomichelakis NN, Theodosiadis PG, Pantelia E, Papaefthimiou S, Theodosioidis GP, Sfikakis PP. Infliximab for chronic cystoid macular edema associated with uveitis. *Am J Ophthalmol.* 2004;138:648-50.
36. Cantini F, Niccoli L, Salvarini C, Padula A, Olivieri I. Treatment of longstanding active giant cell arteritis with infliximab: report of four cases. *Arthritis Rheum.* 2001;44:2933-5.
37. Airo P, Antonioli CM, Vianelli M, Toniati P. Anti-tumor necrosis factor treatment with infliximab in a case of giant cell arteritis resistant to steroid and immunosuppressive drugs. *Rheumatology (Oxford).* 2002;41:347-9.
38. Tan AL, Holdsworth J, Pease C, Emery P, McGonagle D. Successful treatment of resistant giant cell arteritis with etanercept. *Ann Rheum Dis.* 2003;62:373-4.
39. Andonopoulos AP, Meimaris N, Daoussis D, Bounas A, Giannopoulos G. Experience with infliximab (anti-TNF alpha monoclonal antibody) as monotherapy for giant cell arteritis. *Ann Rheum Dis.* 2003;62:1116.
40. Hoffmann GS, Merkel PA, Brasington RD, Lenschow DJ, Liang P. Anti-tumor necrosis factor therapy in patients with difficult to treat Takayasu arteritis. *Arthritis Rheum.* 2004;50:2204-96.
41. Della Rosa A, Tavani A, Merlini G, Baldini C, Sebastiani M, Lombardi M, et al. Two Takayasu arteritis patients successfully treated with infliximab: a potential disease-modifying agent? *Rheumatology (Oxford).* 2005;44:1074-5.
42. Karageorgaki ZT, Mavragani G, Papatheanasiou MA, Skopouli FN. Infliximab in Takayasu arteritis: a safe alternative? *Clin Rheumatol.* 2007;26:984-7.
43. Jolly M, Curran JJ. Infliximab-responsive uveitis an vasculitis in a patient with Takayasu arteritis. *J Clin Rheumatol.* 2005;11:213-5.
44. Tanaka F, Kawakami A, Iwanaga N, Tamai M, Izumi Y, Aratake K, et al. Infliximab is effective for Takayasu arteritis refractory to glucocorticoids and methotrexate. *Intern Med.* 2006;45:313-6.
45. Hoffman GS, Cid MC, Rendt-Zagar KE, Merkel PA, Weyand CM, Stone JH, et al. Infliximab for maintenance of glucocorticosteroid-induced remission of giant cell arteritis: a randomized trial. *Ann Intern Med.* 2007;146:621-30.
46. Salvarani C, Macchioni P, Manzini C, Paolazzi G, Trotta A, Manganelli P, et al. Infliximab plus prednisone or placebo plus prednisone for the initial treatment of polymyalgia rheumatica: a randomized trial. *Ann Intern Med.* 2007;146:631-9.
47. Nikas SN, Voulgari PV, Alamanos Y, Papadopoulos CG, Venetsanopoulou AI, Georgiadis AN, et al. Efficacy and safety of switching from infliximab to adalimumab. A comparative controlled study. *Ann Rheum Dis.* 2006;65:257-60.
48. Wick MC, Ernestman S, Lindblad S, Bratt J, Klareskog L, Van Vollenhoven RF. Adalimumab restores clinical response in patients with secondary loss of efficacy from infliximab or etanercept: results of the STURE registry at Karolinska University Hospital. *Scand Rheumatol.* 2005;34:353-8.
49. Carmona L, Gómez-Reino JJ, Rodríguez-Valverde V, Montero D, Pascual-Gómez E, Mola EM, et al. Effectiveness of recommendations to prevent reactivation of latent tuberculosis infection in patients treated with tumor necrosis factor antagonists. *Arthritis Rheum.* 2005;52:1766-72.
50. Ramos-Casals M, Brito-Zerón P, Muñoz S, Soria N, Galiana D, Bertolaccini L, et al. Autoimmune diseases induced by TNF-targeted therapies: Analysis of 233 cases. *Medicine (Baltimore).* 2007;86:242-51.