

## Case report

## Atypical presentation of microscopic polyangiitis

Susana Olivera-González,<sup>a,\*</sup> Beatriz Amores-Arriaga,<sup>a</sup> Marta Matía-Sanz,<sup>a</sup> Carmen Gómez-Del Valle,<sup>a</sup> Miguel Ángel Torralba-Cabeza,<sup>a</sup> Juan Ignacio Pérez-Calvo,<sup>a</sup> and Manuel Moros-García<sup>b</sup>

<sup>a</sup>Servicio de Medicina Interna, Hospital Clínico Universitario Lozano Blesa, Zaragoza, Spain

<sup>b</sup>Servicio de Anatomía Patológica, Hospital Clínico Universitario Lozano Blesa, Zaragoza, Spain

## ARTICLE INFO

## Article history:

Received June 13, 2009

Accepted July 21, 2009

## Keywords:

Microscopic polyangiitis

Central nervous system

Cytoplasmic anti-neutrophil cytoplasmic antibody

## Palabras clave:

Poliangeítis microscópica

Sistema nervioso central

Anticuerpos anticitoplasma de neutrófilos patrón citoplasmático

## ABSTRACT

Microscopic polyangiitis is a systemic vasculitis that affects small caliber vessels, with renal and lung compromise. We present the case of a patient with an atypical presentation of this disease and an onset characterized by central nervous system affection in the form of a motor deficit

© 2009 Elsevier España, S.L. All rights reserved.

### Presentación atípica de poliangeítis microscópica

## RESUMEN

La poliangeítis microscópica es una vasculitis sistémica que afecta a pequeños vasos, con afectación renal y pulmonar. A continuación se presenta el caso clínico de un paciente con manifestación atípica de esta enfermedad, que debutó con afectación del sistema nervioso central, en forma de déficit motor.

© 2009 Elsevier España, S.L. Todos los derechos reservados.

### Introduction

Microscopic polyangiitis (MPA) is a systemic necrotising vasculitis that affects small-calibre vessels (capillaries, venules or arterioles). Its clinical manifestations are similar to those of polyarteritis nodosa (PAN), but it is characterised by the presence of rapidly progressive glomerulonephritis and pulmonary capillaritis, which are normally absent in PAN.<sup>1</sup> The case of a patient with an atypical presentation form of MPA is presented.

### Case report

The patient was a 69-year-old male with a history of nasal polyposis, asthma, arterial hypertension and benign prostatic hypertrophy, who was following treatment with salmeterol/fluticasone, nifedipine,

aspirin, tamsulosin, doxazosin and topical nasal mometasone. He was admitted due to asthenia and weight loss of 4–6 kg with one month of evolution, accompanied by facial oedema and fever of 48 hours evolution. Upon examination, blood pressure and oxygen saturation were normal. The patient was conscious and presented disorientation in time and space as well as autopsychic disorientation. On cardiac auscultation, tones were rhythmic at 70 bpm, without murmurs. The rest of the examination was normal, with no oedema in the lower extremities. At 5 days after admission, he presented left hemiparesis. The neurological examination showed left hemiparesis, with crural predominance, with patellar tendon reflex exaltation. Laboratory tests revealed anaemia (Hb 8.2 g/dl, Hct 23.6%, MCV 87.1) and renal failure (urea 1.63 g/l, creatinine 1.4 mg/dl, with the latter reaching figures of 3.3 mg/dl during evolution); the remaining laboratory parameters were normal. More than 100 erythrocytes/field were detected in the urine sediment test. There was a clear deterioration of renal function

\* Corresponding author.

E-mail address: [susana.olivera@yahoo.es](mailto:susana.olivera@yahoo.es) (S. Olivera-González).

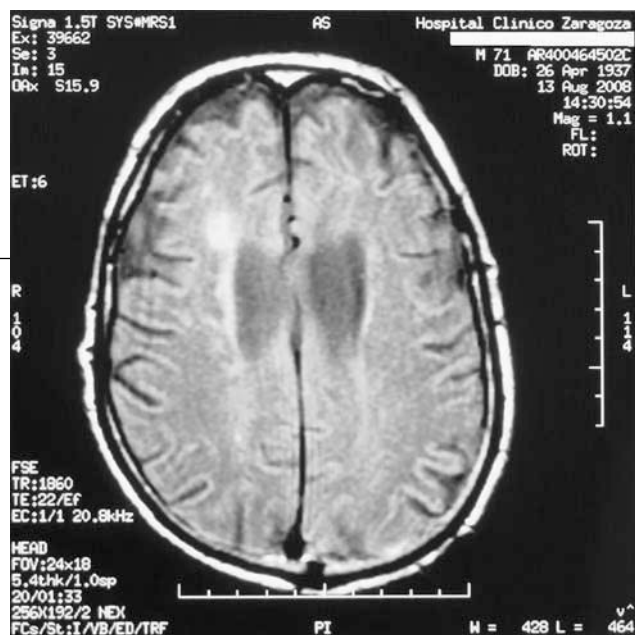


Figure 1. Magnetic resonance image, T1 sequence, showing deep sylvian infarct.

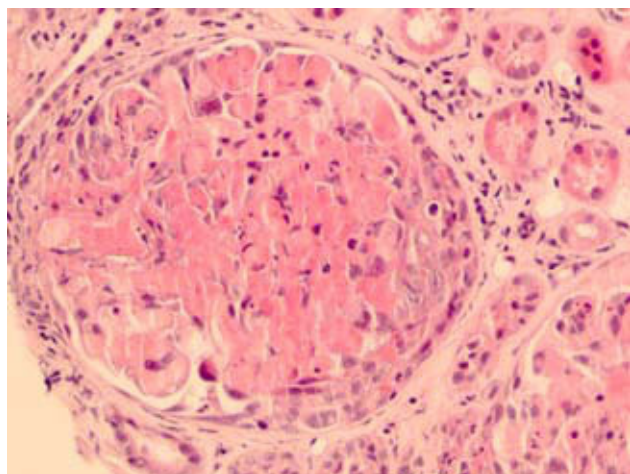


Figure 2. Light microscopy (haematoxylin-eosin staining), showing glomerulus with karyorrhexis phenomena, intravascular thrombi and crescent formation.

with creatinine clearance of 24.71 ml/min, proteinuria of 1.63 g/24 h and granular cylinders. A cerebral CT and lumbar puncture were carried out and their results were normal. A subsequent MRI revealed multiple lacunar infarcts in the white matter (middle oval and deep sylvian white matter) (Figure 1). The proteinogram and serology (including hydatid disease, trichinosis, HBV, HCV, parvovirus B19, CMV and EBV) were not altered. The remaining cultures were negative. We measured ANA autoantibodies, antibodies (Ab) against double-stranded DNA, anticardiolipin immunoglobulin (Ig) M and IgG, with all results being normal. These were determined by ELISA c-ANCA, with negative result, and by ELISA p-ANCA, which yielded more than 100 IU/ml (normal: 0–7 IU/ml). Suspecting a rapidly progressive renal failure, we carried out a renal biopsy, which revealed necrotising glomerulonephritis with 31% epithelial crescents, compatible with MPA (Figure 2). The patient was treated with prednisone (1.5 mg/kg/day) and cyclophosphamide cycles (one monthly cycle of 500

mg i.v. for 6 months, with a cumulative dose of 3 g), which caused neurological symptoms to disappear 15 days after starting treatment. The patient is currently asymptomatic, with a maintenance dose of prednisone of 10 mg/day. In the latest analysis, creatinine was 1.63 mg/dl and creatinine clearance was 46.01 ml/min.

## Discussion

The term microscopic polyarteritis was coined in 1948 by Davson, when noting glomerulonephritis in a patient with PAN. In 1992, the term MPA was adopted to refer to a necrotising vasculitis affecting small-calibre vessels and presenting renal and pulmonary features. Immunohistochemical staining reveals lack of Ig deposits in the vascular lesion, thus suggesting that the formation of immune complexes is not involved in the pathogenesis. The disease may begin gradually with fever, weight loss and musculoskeletal pain, although it is often acute. In 79% of the cases, it involves glomerulonephritis with a rapid advance, which causes kidney failure. Haemoptysis occasionally constitutes the first sign of alveolar haemorrhage, with a frequency of 12%.<sup>2</sup> Other manifestations include multiple mononeuritis<sup>3</sup> and digestive and cutaneous vasculitis.<sup>4</sup> In 75% of patients, ANCA appear and anti-myeloperoxidase Ab are predominant.<sup>2</sup>

In the case of our patient, the clinical presentation was a rapidly worsening renal failure and disruption of the central nervous system in the form of motor deficit. The differential diagnosis of Wegener's granulomatosis was considered, as it was a case of probable vasculitis with multiorgan involvement and, in particular, renal involvement. Autoimmunity tests were requested and resulted normal, except for the presence of positive p-ANCA. In addition, the patient did not present involvement of the upper airway or pulmonary nodules, so the diagnosis of Wegener's granulomatosis was not suggested. Renal injury in MPA is identical to that observed in Wegener's granulomatosis, but the absence of granulomatous inflammation led us to discard the latter.<sup>5</sup>

Survival at 5 years is 74%, and death takes place due to alveolar haemorrhage or digestive, kidney or heart disorders. Treatment for MPA is carried out with corticosteroids, with or without cyclophosphamide, depending on the severity.<sup>6</sup> After treatment, our patient showed improved renal function and the neurological symptoms disappeared, so these were attributed to MPA-produced vasculitis.

In conclusion, the singularity of this case lies in the central nervous system involvement as an atypical presentation of MPA. This is one of the few cases reported in the medical literature,<sup>7,8</sup> and illustrates the variety of clinical manifestations of this entity.

## References

- Ruiz-Laiglesia JE, Argoitia A, López-Unzu A, Laplaza Y. Poliangeítis microscópica: aspectos clínicos y tratamiento. *Nefrología*. 1997;XVII:446–7.
- Sneller MC, Langford CA, Fauci AS. Síndromes de las vasculitis. *Harrison, principios de medicina interna* (2203–15). Mexico: McGraw-Hill Interamericana; 2005.
- Sugiura M, Koike H, Iijima M, Mori K, Hattori N, Katsumo M, et al. Clinicopathological features of monosystemic vasculitic neuropathy and microscopic polyangiitis-associated neuropathy: A comparative study. *J Neurol Sci*. 2006;241:31–7.
- Kawakami T, Kawanabe T, Saito C, Kannari M, Mizoguchi M, Nagafuchi H, et al. Clinical and histopathologic features of 8 patients with microscopic polyangiitis including two with a slowly progressive clinical course. *J Acad Dermatol*. 2007;57:840–8.
- Lane SE, Watts RA, Shepstone L, Scott DG. Primary systemic vasculitis: clinical features and mortality. *QJM*. 2005;98:97–111.
- Jayne D. Challenges in the management of the microscopic polyangiitis: past, present and future. *Curr Opin Rheumatol*. 2008;20:3–9.
- Han S, Rehman HU, Jayaratne PS, Carty JE. Microscopic polyangiitis complicated by cerebral haemorrhage. *Rheumatol Int*. 2006;26:1057–60.
- Tang CW, Wang PN, Lin KP, Huang DF, Wang SJ, Chen WT. Microscopic polyangiitis presenting with capsular warning syndrome and subsequent stroke. *J Neurol Sci*. 2009;277:174–5.