

Original article

## Reliability and reproducibility of a morpho-textural image analysis method over a patellar ligament ultrasonography

 José Ríos-Díaz,<sup>a,\*</sup> Ana de Groot Ferrando,<sup>b</sup> Jacinto J. Martínez-Payá,<sup>a</sup> and Mária Elena del Baño Aledo<sup>a</sup>
<sup>a</sup>Grupo de Investigación "Ecografía y Morfo-densitometría Preventiva", Departamento Ciencias de la Salud, Universidad Católica San Antonio de Murcia (UCAM), Murcia, Spain  
<sup>b</sup>Khronos Fisioterapia, Elche, Alicante, Spain

## ARTICLE INFO

## Article history:

Received October 18, 2009

Accepted January 17, 2010

## Keywords:

 Biological therapies  
 Follow-up  
 Adverse events  
 Registry  
 Rheumatic diseases

## ABSTRACT

**Objective:** Image analysis techniques over ultrasonograms may be useful to extract quantitative information. Because ecography and the selection of the area of interest are technician-dependent, the objective of this work was to calculate the reliability and the reproducibility of the analysis method.

**Material and methods:** Test-retest reliability study on 60 cross-sectional patellar ligament ultrasonograms on 1 cm of patella were carried out. Sonosite Titan L-38 (5-10 MHz) and the Image analysis software J v1.40 were used. Morphometric variables were: perimeter, area, width, thickness, and mean echogenicity; textural variables were: uniformity, homogeneity and entropy. The intraclass correlation coefficient (ICC) was calculated with a confidence interval of 95%.

**Results:** Intraclass correlation coefficients over 0,70 were found, with an agreement ranging from good to very good in all of the variables both for the intra ecography and inter ecography studies.

**Conclusion:** Very good levels of reliability and internal consistency were seen, demonstrating that from the statistical point of view, the variability introduced by the technician is not significant. This method can be taken as a reference to analyze the reliability between several ultrasonographers.

© 2009 Elsevier España, S.L. All rights reserved.

### Fiabilidad y reproducibilidad de un nuevo método de análisis morfotextural de imágenes ecográficas del tendón rotuliano

## RESUMEN

**Objetivos:** La aplicación de ecografía cuantitativa sobre el tejido tendinoso puede resultar de utilidad pero es necesario conocer la fiabilidad tanto del proceso de la toma ecográfica como de la selección de las regiones para el análisis. Los objetivos del trabajo fueron calcular la fiabilidad y reproducibilidad del método de análisis morfotextural intra-ecografía e interecografía del tendón rotuliano.

**Material y métodos:** Estudio de concordancia del tipo test-retest sobre 120 ecografías transversales del tendón rotuliano a 1 cm del pico de la rótula, con un ecógrafo Sonosite Titan y sonda L-38 (5-10 MHz) y el software de análisis Image J v1.40. Se calcularon variables morfométricas: perímetro, área, anchura, grosor y ecogenicidad media; y texturales: uniformidad, homogeneidad y entropía. Se calculó el coeficiente de correlación intraclass (CCI) junto con las representaciones gráficas de Bland con un IC del 95%.

**Resultados:** Se encontraron coeficientes de correlación intraclass con valores superiores a 0,70, con fuerza de la concordancia entre buena y muy buena en todas las variables y tanto en el estudio intraecografía como en el estudio interecografía.

**Conclusión:** La fiabilidad del método fue buena por lo que la variabilidad introducida por los exploradores no es significativa y el método es potencialmente válido para el estudio y cuantificación ecográfica del tejido tendinoso.

© 2009 Elsevier España, S.L. Todos los derechos reservados.

## Palabras clave:

 Ecografía  
 Fiabilidad  
 Tendón rotuliano  
 Análisis textural  
 Procesamiento de imagen asistido por ordenador

## Introduction

It is generally said that an ultrasound is an innocuous technique, quickly-performed and inexpensive. However, the scanner needs to

have suitable anatomic knowledge to identify the structures being analysed at every moment and it is therefore very technician-dependent. Quantification of information contained in ultrasound images is one of this field's most crucial aspects as it allows us to differentiate between normal, pathological and even pre-pathological states at first glance. In ultrasound, this interest is even greater as, in spite of its potential usefulness, there are few jobs where the

\* Corresponding author.

E-mail address: jrrios@pdi.ucam.edu (J. Ríos-Díaz).

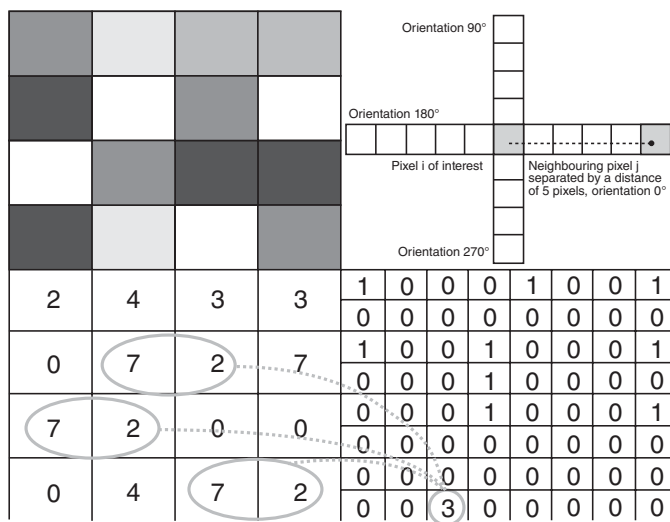
ultrasound image is manipulated to extract quantitative information from it.<sup>1</sup> We speak of a quantitative ultrasound when the information extracted from the image goes further than visual interpretation of the ultrasound pattern and this pattern is analysed with variable objectives, which are quantifiable through image analysis.

The grey-scale ultrasound image is configured after processing the echoes resulting from the different acoustic tissue impedances that go through the ultrasound beam. In the case of a tendon, an ultrasound pattern will be obtained that is the reflection of the tendinous structure in which the joint tissue regions are shown to be hyperechoic and the extracellular matrix areas will show a hyperechoic signal.<sup>2</sup>

Therefore, the image obtained will be represented by a combination of discrete elements (pixels) with a specific grey intensity. Through advanced ultrasound image analysis, the morphometric type variables such as perimeters, areas, widths, thicknesses or circularity indexes, and mean echogenicity levels can be calculated.<sup>3</sup> However, they will never allow us to quantify the “aspect” or texture of the image and will therefore not reveal the echogenic patterns changes unless they are very obvious.

In this way, image textural analysis has been useful to differentiate images for different requirements. Haralick et al<sup>4</sup> developed an algorithm, Grey Level Co-occurrence matrix (GLCM), that allowed them to differentiate different textures in satellite images. This has later been applied to many areas, including biomedical images. Different investigators have achieved improvements in diagnosis through ultrasound images in prostate tumours,<sup>5</sup> in lung tumours,<sup>6</sup> in endometrial tumours,<sup>7</sup> and in hepatic pathology.<sup>8,9</sup>

Texture analyses through GLCM are based on comparing the grey levels on pixel pairs. A matrix for the proliferation probability of these grey values throughout the image is set up. The relative position can be determined between the pixel pairs, defining the distance between the pixels themselves and in which direction  $\theta$  (Figure 1). There will be a matrix that gathers information on the frequency with which certain grey levels appear on the image and the relationship between them. From the resulting matrix, we can



**Figure 1.** Construction of a grey scale concurrence matrix. On the upper left hand side, the pixels of an image are represented with a grey scale (imaginary) represented in the lower left image. The coincidences for a given pixels pair are computed (a distance  $d$  and an angle  $\theta$  is the separation between them); the algorithm counts how many times the grey scale in the pixel pair is repeated and builds up the probability of appearance matrix for this pair in the image. It is on this matrix that the textural variables are calculated (for theoretical basics, see Haralick et al, 1973).<sup>4</sup>

calculate a series of variables—Haralick et al<sup>4</sup> described up to 14. We have chosen the 3 most useful in our area:

- 1) Angular Second Moment (ASM) or uniformity

$$\sum_{i,j=0}^{N-1} P_{ij}^2 \tag{1}$$

where  $i$  and  $j$  are the respective grey levels of the pixel pair, which can have values between 0-225.  $P$  is the probability with which the pixel pair's grey levels will appear in the image (for a given distance or distances). The maximum value (1) will be reached if all the pixel pairs in the image are identical (independent to the grey scale value of the pairs' components), which means that it can be said that this variable numerically quantifies how regular a certain image is.

- 2) Inverse Difference Moment or homogeneity

$$\sum_{i,j=0}^{N-1} \frac{P_{ij}}{1+(i-j)^2} \tag{2}$$

where  $i$  and  $j$  are the respective grey levels of the pixel pair, which can have values between 0-225.  $P$  is the probability with which the grey levels of the pixel pair will appear in the image (for a given distance or distances). This variable quantifies the homogeneity grade that the image presents but in a completely different way to that of uniformity. In Equation (2), you can see that for the homogeneity calculation the difference between the grey level of each of the pixel pair are taken into account. This is why uniformity tends to be greater when the differences of the pixel grey levels in an image are small, while uniformity is less if the differences in the pixels are large.

- 3) Entropy

$$\sum_{i,j=0}^{N-1} P_{ij}(-\ln P_{ij}) \tag{3}$$

where  $i$  and  $j$  are the respective grey levels of the pixel pair, which can have values between 0-225.  $P$  is the probability with which the grey levels of the pixel pair will appear in the image (for a given distance or distances). It can be interpreted as the disordered or chaotic level (in the physical sense of the term) present in the image. It takes its maximum value when all the pixel pairs are represented with the same probability in the image, which in some way means maximum possible disorder in the image.

Given that carrying out the ultrasound and the analysis of the image itself are technician-dependent, the objective of this job was to evaluate the reliability and reproducibility of the intra- and inter-ultrasound methods.

### Material and methods

**Design:** As it is a reliability study, the working design corresponds to a transversal analytical observational study.<sup>10</sup>

**Material:** A Sonosite Titan<sup>®</sup> ultrasound was used with broadband linear array L-38 with a work frequency of 5-10 mHz, suitable to carry out skeletal muscle ultrasounds. The images were stored uncompressed in a bitmap format (bmp) at a size of 640x480 pixels (217x163mm) in 8-bit with 256 possible grey levels.

Image J v.1.40 software was used to analyse the image<sup>11</sup> together with its corresponding morphometric and textural analysis applications.<sup>12</sup>

A digital graphics tablet was also available (Wacom<sup>®</sup> tablet, Wacom Co., Ltd. 2007, USA) to trace areas of interest.

**Method:** Thirty healthy subjects were chosen (males between 20 and 30 years old) with no previous tendinous history and having

given written consent. The process selection for the subjects did not take into account any inclusion or exclusion criteria because the aim was to obtain a sufficient number of ultrasounds on which to carry out successive measurements and compare them, not to extract information concerning the patients themselves.

The study was carried out in the first half of 2009 at the Health Science Department of the San Antonio Catholic University of Murcia. To start with, 60 transversal patellar tendon ultrasounds with a 1 cm vertex insertion in the patella were carried out: Thirty of them were at a depth of 3.9 cm to obtain a complete image of the tendon needed for morphometric analysis; there were another 30 at a depth of 2.4 cm, on which we carried out a texture analysis. Each ultrasound was analysed twice, with a time interval between measurements of 3-5 days, so as to evaluate the reliability of the morpho-texture image (intra-ultrasound) analysis method.

Once the reliability and reproducibility of the image analysis process was established, the reliability of the ultrasound-taking process was assessed. To do so, 30 ultrasounds were taken at 3.9 cm and 30 at 2.4 cm by the same ultrasonographer and on the same subjects, with the aim of assessing the reliability of the ultrasound taking process (inter-ultrasound). A total of 120 ultrasounds were therefore taken.

In Figure 2, the flowchart of the method followed for taking and distributing the ultrasounds is presented.

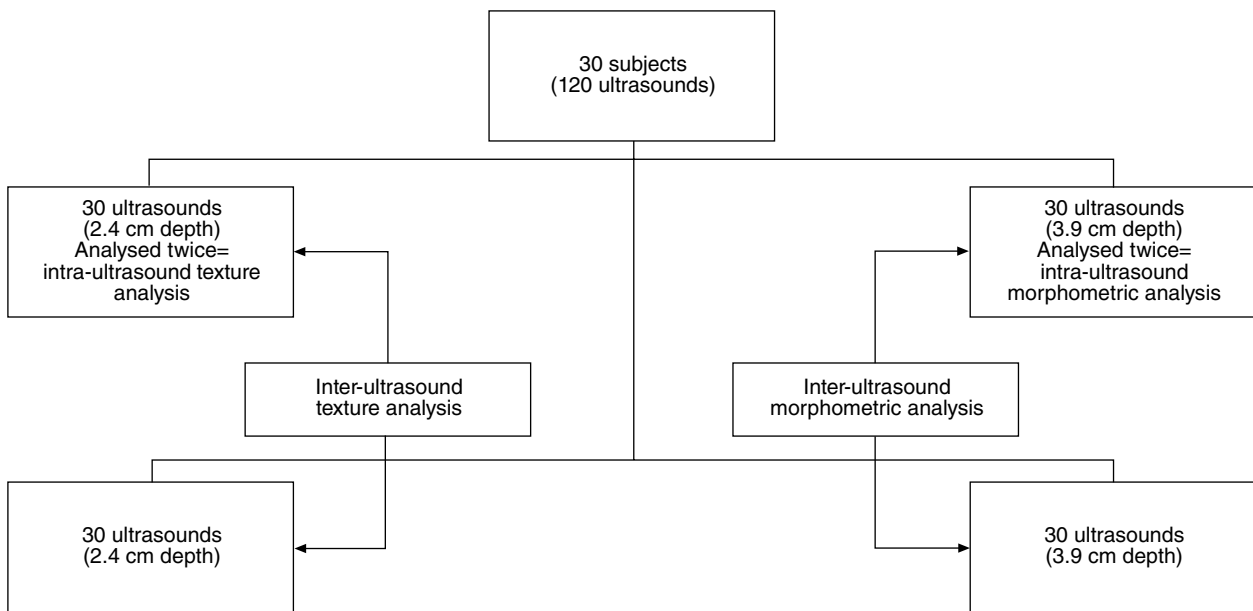
In all cases, the ultrasounds were performed according to a previously established protocol in which the ultrasound parameters

**Table 1**

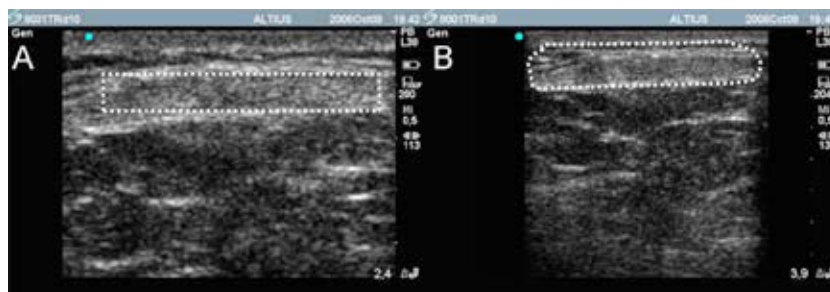
Reliability and concordance strength for the morpho-texture variables in the intra-ultrasound analysis

Variables	ICC	CI 95%		Concordance strength
		Average	Lower	
Perimeter	0.87	0.67	0.95	Good
Area	0.86	0.66	0.94	Good
Width	0.73	0.36	0.89	Good
Thickness	0.87	0.70	0.95	Good
Echogenicity	0.88	0.72	0.95	Good
Uniformity	0.94	0.87	0.97	Very good
Homogeneity	0.91	0.80	0.96	Very good
Entropy	0.96	0.91	0.98	Very good

ICC indicates intraclass correlation coefficient calculated according to alpha two-way mixed effect model and absolute agreement with a confidence interval (CI) of 95%.



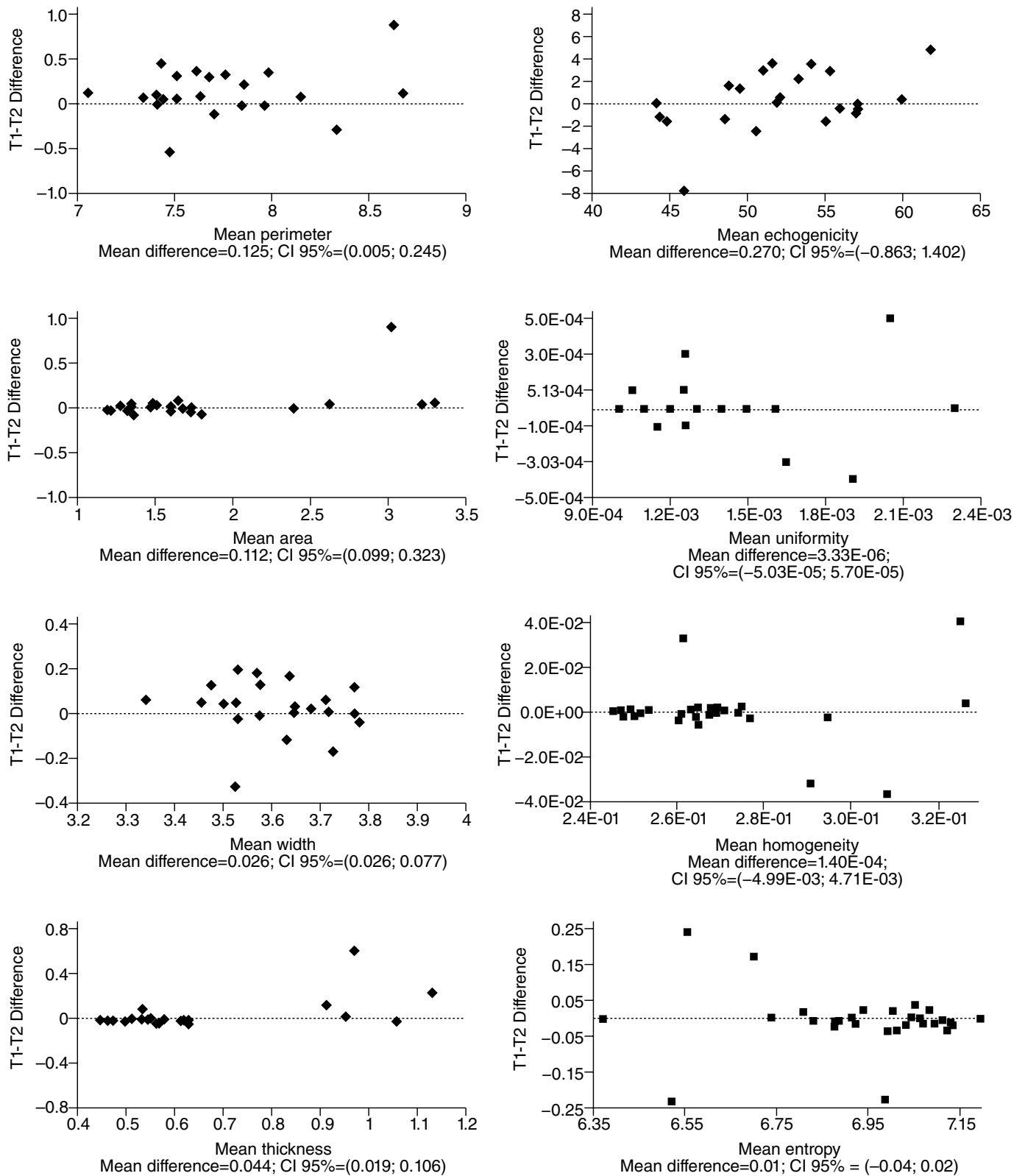
**Figure 2.** Flowchart for intra- and inter-ultrasound analyses.



**Figure 3.** Determination of the perimeter and the area of interest in a cross-section of the patellar tendon. A) Ultrasound at a depth of 2.4 cm and the area of interest for texture analysis. B) Depth of 3.9 cm and marked tendinous perimeter.

(without manipulating the gain curves), the probe position (perpendicular and transversal to the body and tendon), the amount of conductive gel (through a dispenser), and the subject's position (in a dorsal recumbent position with the knee bent at 30°) were defined.

The morphometric variables such as the tendon perimeter, area, thickness, and echogenicity (average grey level) were automatically calculated from the tendinous perimeter, which had to be manually outlined by the image analysis technician (Figure 3).



**Figure 4.** Bland graphics for morpho-texture variables in the inter-ultrasound analysis. The differences between the first (T1) and the second measurement (T2) are represented on the ordinate axis. The mean of the first and second measurement is represented on the abscissa axis. The points represent each of the ultrasounds on the analysed sample at two different time points. Each graph is completed with the value of the mean difference and confidence interval of this difference. CI indicates confidence interval.

The technician selected an area of interest for the texture study that the algorithm would later analyse. A rectangular area was marked (300×60 px) in such a way that the central part of the tendon would be covered (Figure 3). The texture variables were uniformity, homogeneity, and entropy.

Statistical analysis: The intraclass correlation coefficient (ICC) was calculated to allow us to obtain a measurement of the consistency grade or agreement between measurements.<sup>13–15</sup> It was specifically calculated under the alpha 2-way mixed effect model, looking for the absolute concordance in which, to determine an agreement between 2 variables, they have to vary in parallel and their means and variances must be the same.<sup>16,17</sup>

The lower and higher ICC limits were calculated with a confidence interval of 95%. ICC can swing from a value of 0 (where there is no concordance between measurements) to a value of 1 in a situation of perfect concordance. The usual qualitative scale for this type of studies was used in which concordance was considered very good (>0.90), good (0.80–0.90), moderate (0.60–0.80) and poor (<0.60).<sup>18,19</sup>

Graphic representations for this type of analysis were carried out just as Bland and Altman<sup>20</sup> recommend to complete the study. These types of graphs represent the differences between the measurement pairs (ordinate axis) and their mean; therefore, each mean is represented by a point. When concordance is high, the values tend to group around the horizontal line (which represents absolute concordance). The graph is completed with the value of the mean difference and its confidence interval.

The statistical analysis programme was SPSS 15.0 (SPSS Inc. Chicago, IL, USA) and a confidence interval of 95% was applied to all statistical tests.

The study protocol was approved by the relevant local ethics committees following Helsinki Declaration guidelines.

All patients included in the study received sufficient information and gave their informed written consent to participate in it.

## Results

Table 1 presents the ICC values for the morpho-texture variable in the intra-ultrasound study, which in this case is assessing the reliability of the image analysis method. On a quantitative scale,<sup>19</sup> the concordance strength was good for the morphometric variables (ICC higher than 0.70) and very good for the texture (ICC values higher than 0.90).

Figure 4 graphically shows the concordance between measurements through the corresponding Bland graphs with mean differences always less than at least 2 orders of magnitude with respect to the magnitude in which the variable is measured. This indicates that the error between the first measurement (T1) and the second measurement (T2) is at least 100 times less than the value of the variable itself. The confidence intervals for these differences

(which can be seen at the base of each of the graphs) are also reduced, which indicates that there is little variability between the differences in successive measurements.

In the case of the reliability analysis on ultrasounds taken at two different times on the same subjects, we are assessing precisely this phase of the method: the possible variability between different ultrasound takes. The results (Table 2) show that the concordance strength is very good, not only for morphometric variables but also for texture. The only exceptions are the tendon width variable and homogeneity, in which it was moderate.

Figure 5 presents the corresponding graphic representations, which show, the same as in the previous case, that the mean differences for each of the variables are at least 2 orders of magnitude less than the magnitude in which the variable is measured. In addition, the majority of the points on the graph are around the straight line that represents absolute concordance between measurements.

## Discussion

Although the average ICC values were good or very good, some considerations must be taken into account. Lower ICC confidence interval limits of a perimeter 0.67 were observed in the intra-ultrasound study (Table 1). The rest of the morphometric variables derived from it (automatically calculated from the perimeter marked by the technician) showed lower limits of similar concordance, except in width, which was 0.36. The lower limit ICC confidence values were less than those registered in studies on tendons easier to delimit and identify, such as the Achilles tendon.<sup>21,22</sup> This could be because the lower border of the patellar tendon is not always clear and its identification can therefore be one of the points in the method that is most exposed to subjectivity and the technician's experience. Even so, if the corresponding Bland graphs are analysed (Figure 4), one can see that the mean differences between the measurements and their confidence intervals are about 100 times less than the units of the variable itself and, the concordance between the measurements can therefore be confirmed as good.

In the case of the ICC values found for intra-ultrasound variables, it can be seen (Table 1) that the lower limits of the 3 variables (uniformity, homogeneity, and entropy) are higher than 0.80 with very good mean concordance levels (>0.90). In selecting the area of interest, the technician has clearer references: the algorithm only analyses rectangular areas and the technicians limits themselves to placing the rectangle (which is always the same size) on the central area of the tendon, taking as the reference its higher border, which always presents an easily-found hyperechogenic image.

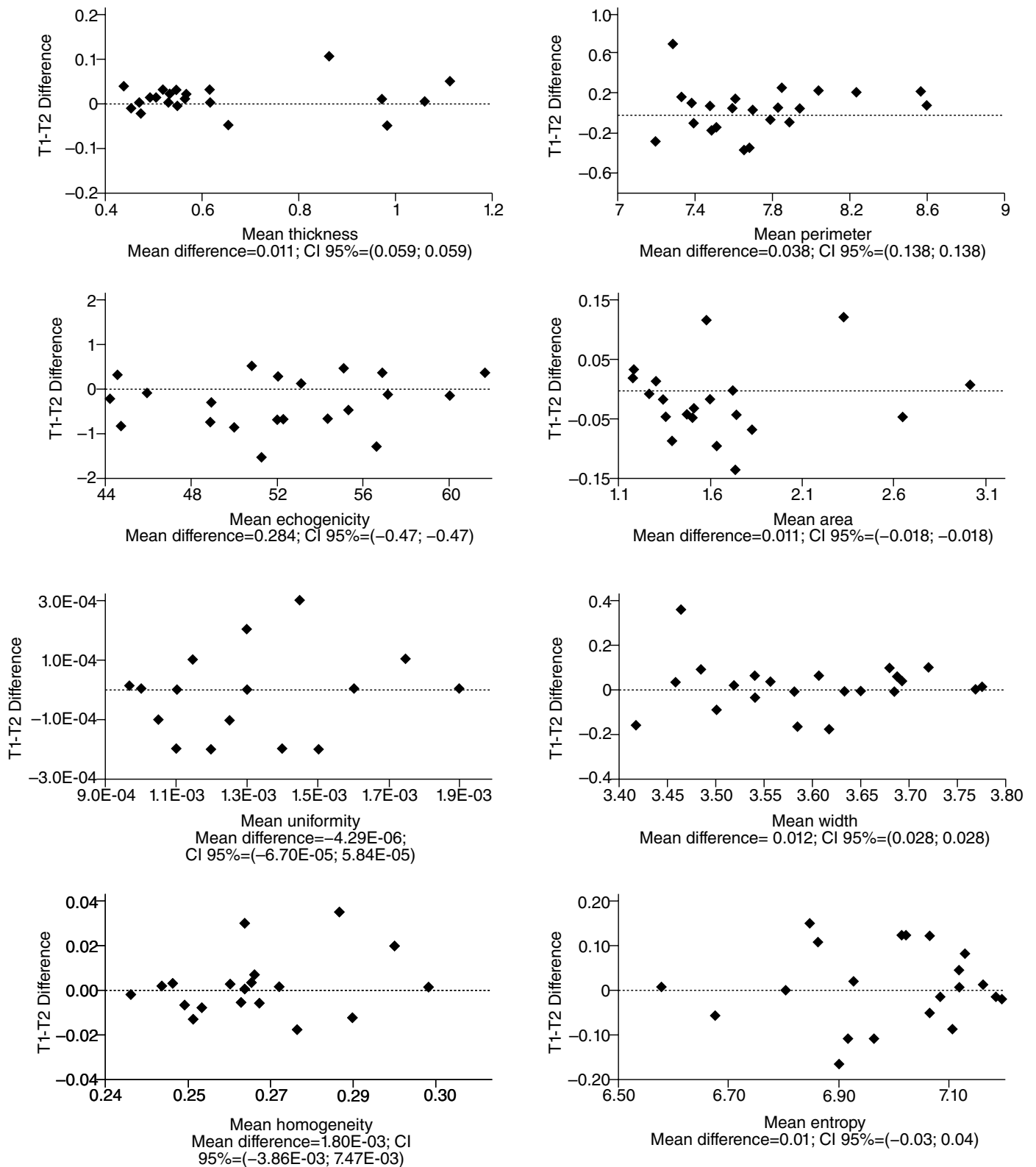
In the reliability study that we have called inter-ultrasound and that has enabled us to control the reliability phase of the method as related to taking the ultrasound, here both the morphometrical variables and the textural ones showed ICCs similar to those in the intra-ultrasound study (Table 2). It is important to highlight that this method phase can be decisive in the final "aspect" of the ultrasound; precautions should therefore be taken regarding the position of the subject, the ultrasonographer, and the anatomic references to correctly position the probe.<sup>23</sup>

In the image analysis phase, different attempts have been tried to automate the perimeter contours through the implementation of snakes (active contours). These, starting from an initiator marked by the technician, are capable of locating the limits of the structure of interest. Bastida<sup>24</sup> and Morales et al<sup>25</sup> both carried out their studies with this type of algorithm on transversal ultrasounds of the Achilles tendon with results that are promising but insufficient at present due to the limitations of the ultrasound image itself. Therefore, reliability studies are also necessary if the images are to be manipulated for extracting quantitative information.

**Table 2**  
Reliability and concordance strength for the morpho-texture variables in the inter-ultrasound analysis

Variables	ICC	CI 95%		Concordance strength
		Average	Lower	
Perimeter	0.91	0.78	0.96	Very good
Area	1.00	0.99	1.00	Very good
Width	0.70	0.27	0.88	Good
Thickness	0.99	0.98	1.00	Very good
Echogenicity	1.00	0.99	1.00	Very good
Uniformity	0.91	0.79	0.97	Very good
Homogeneity	0.86	0.65	0.94	Good
Entropy	0.94	0.84	0.97	Very good

ICC indicates intraclass correlation coefficient calculated according to alpha two way mixed effect model and absolute agreement with a confidence interval (CI) of 95%.



**Figure 5.** Bland graphics for morpho-texture variables in the inter-ultrasound analysis. The differences between the first (T1) and the second measurement (T2) are represented on the ordinate axis. The mean of the first and second measurement is represented on the abscissa axis. The points represent each of the ultrasounds of the analysed sample during two different time points. Each graph is completed with the value of the mean difference and confidence interval of this difference. CI indicates confidence interval.

Through the morpho-textural analysis of a tendinous ultrasound image, we have been able to distinguish between sedentary or sports subjects<sup>26</sup> and changes in the ultrasound patterns of subjects who do training<sup>27</sup> and in professional

volleyball players throughout the season<sup>28</sup> have been quantified. This means that they could potentially be used to detect and quantify the ultrasound patterns compatible with pathology, even before symptoms appear.

Based on the results obtained in this study, we can confirm that the method used has good reliability and reproducibility. It would be interesting to expand this study so as to recognise the reliability of inter-observers and even different ultrasound teams, which would increase the strength of the method.<sup>29,30</sup>

### Conflict of interests

The authors declare no conflict of interests.

### References

- Martínez-Payá JJ, Ríos-Díaz J, Palomino MA, Martínez LM, Calvo MC, Tenas MJ, et al. Análisis cuantitativo de la ecogenicidad del sistema músculo-esquelético. In: Esparza F, Fernández T, Martínez JL, Guillén P, editors. *Prevención de las lesiones deportivas*. Murcia: Quaderna Editorial; 2006. p. 245-7.
- Schmidt G. *Ecografía. De la imagen al diagnóstico*. Madrid: Editorial Médica Panamericana; 2008.
- Martínez-Payá JJ, Ríos-Díaz J, Martínez F, Martínez-Almagro A. Procesos degenerativos asintomáticos del tendón largo del bíceps braquial. Análisis ecogénico como medida de prevención. In: Bielsa R, Rivero A, Molina JJ, Manzano A, editors. *Actividad física y deporte en la sociedad del siglo XXI*. Madrid: Gymnos Editorial Deportiva; 2005. p. 1039-47.
- Haralick RM, Shanmugam K, Dinstein I. Textural features for image classification. *IEEE Trans Syst Man Cybern*. 1973; SMC-3:610-21.
- Sheppard MA, Shih L. Efficient image texture analysis and classification for prostate ultrasound diagnosis. *IEEE*. 2005;8:7-8.
- Bader W, Bohmer S, Van Leeuwen P, Hackmann J, Westhof G, Hatzmann W. Does texture analysis improve breast ultrasound precision? *Ultrasound Obstet Gynecol*. 2000;15:311-6.
- Michail G, Karahaliou A, Skiadopoulou S, Kalogeropoulou C, Terzis G, Boniatis I, et al. Texture analysis of perimenopausal and post-menopausal endometrial tissue in grayscale transvaginal ultrasonography. *Br J Radiol*. 2007;80:609-16.
- Cao GT, Shi P, Hu B. Liver fibrosis identification based on ultrasound images. *Conf Proc IEEE Eng Med Biol Soc*. 2005;6:6317-20.
- Nishiura T, Watanabe H, Ito M, Matsuoka Y, Yano K, Daikoku M, et al. Ultrasound evaluation of the fibrosis stage in chronic liver disease by the simultaneous use of low and high frequency probes. *Br J Radiol*. 2005;78:189-97.
- Argimón JM, Jiménez J. *Métodos de investigación clínica y epidemiológica*. Madrid: Elsevier; 2006.
- Rasband WS. Image J [homepage on the Internet]. Bethesda, Maryland, USA: US National Institutes of Health [accessed 29/4/2009]. Available from: <http://rsbweb.nih.gov/ij/>
- Cabrera JA. Texture analyzer plugin for Image J [homepage on the Internet] [accessed 29/4/2009]. Available from: <http://rsbweb.nih.gov/ij/plugins/texture.html>
- Latour J, Abraira V, Cabello JB, López J. Las mediciones clínicas en cardiología: validez y errores de medición. *Rev Esp Cardiol*. 1997;50:117-28.
- Prieto L, Lamarca R, Casado A. La evaluación de la fiabilidad en las observaciones clínicas: el coeficiente de correlación intraclase. *Med Clin (Barc)*. 1998;110:142-5.
- Lomas R. Reproducibilidad de una medida. ¿Cómo analizar los datos? *Cuest fisioter*. 2008;37:131-2.
- McGraw KO, Wong SP. Forming inferences about some intraclass correlation coefficients. *Psychol Methods*. 1996;1:30-46.
- Pardo A, Ruiz MA. *Análisis estadístico de datos con SPSS 13 base*. Madrid: McGraw Hill; 2005.
- Trop I, Stolberg HO, Nahmias C. Estimates of diagnostic accuracy efficacy: how well can this test perform the classification task? *Can Assoc Radiol J*. 2003;54:80-6.
- Pita S, Pértegas S. La fiabilidad de las mediciones clínicas: el análisis de concordancia para las variables numéricas. *Atención Primaria en la Red*. 2004. 11 pages. Available from: [http://www.fisterra.com/mbe/investiga/conc\\_numerica/conc\\_numerica2.pdf](http://www.fisterra.com/mbe/investiga/conc_numerica/conc_numerica2.pdf)
- Bland JM, Altman DG. Statistical methods for assessing agreement between two methods of clinical measurement. *Lancet*. 1986;1:307-10.
- Del-Baño-Aledo ME, Martínez-Payá JJ, Ríos-Díaz J, Palomino M. Aplicación en fisioterapia de la valoración cuantitativa de las características morfoecogénicas del tendón de Aquiles. *Fisioterapia*. 2008;30:61-8.
- Ríos-Díaz J, Martínez-Payá JJ, De-Groot-Ferrando A, Del-Baño-Aledo ME. Fiabilidad y validez interna del método de análisis textural y morfométrico de imágenes ecográficas tendinosas. *Rev Fisioter (Guadalupe)*. 2009;8.
- Martínez-Payá JJ, Ríos-Díaz J, Martínez LM, Montaña JA, Peña O. Bases físicas y morfológicas para la interpretación de la imagen ecográfica músculo-esquelética. In: Martínez-Payá JJ, editor. *Anatomía ecográfica del hombro*. Madrid: Editorial Médica Panamericana; 2008. p. 3-38.
- Bastida MC. Automatisation of morphologic and echogenic measures of human locomotor apparatus structures by means of ultrasonographic images processing [dissertation]. Cartagena, Murcia: Superior Technical School of Telecommunication Engineering, Polytechnic University of Cartagena; 2008.
- Morales J, Verdú R, Larrey J, Sancho JL, Bastida MC. Morphological and echogenic measurements of structures of locomotor system by means of echographic images processing. In: *Las TIC y la gestión del conocimiento en el desarrollo de la Salud: proceedings of the VII Congreso Internacional de Informática en Salud*; 2009 Feb 9-13; La Habana, Cuba [cited 2009 Jul 17]; [7 pages]. Available from: <http://informatica2009.sld.cu/Members/jmorales/medidas-morfologicas-y-ecogenicas-de-estructuras-del-aparato-locomotor-mediante-procesado-de-imagenes-ecograficas/>
- Ríos-Díaz J, Martínez-Payá JJ, De-Groot-Ferrando A, Del-Baño-Aledo ME. Nuevo método de análisis textural mediante matrices de co-ocurrencia del nivel de gris sobre imagen ecográfica del tendón de Aquiles: diferencias entre deportistas y sedentarios. *Cuest Fisioter*. 2009;38:68-79.
- Ríos-Díaz J, Martínez-Payá JJ, Del-Baño-Aledo ME. El análisis textural mediante las matrices de co-ocurrencia (GLCM) sobre imagen ecográfica del tendón rotuliano se muestra útil para detectar cambios histológicos tras un entrenamiento con plataforma de vibración. *Cult Cienc Deporte*. 2009;4:91-102.
- De-Groot-Ferrando A, Ríos-Díaz J, Martínez-Payá JJ, Del-Baño-Aledo ME. Comportamiento morfo-ecogénico y textural del tendón rotuliano frente a estímulos de estrés. Libro de Actas. XI Jornadas Nacionales y I Congreso Internacional de Fisioterapia de la Actividad Física y el Deporte. Madrid, 22-24 octubre 2009. Madrid: Asociación Española de Fisioterapeutas; 2009. p. 201-2.
- Bourantas CV, Plissiti ME, Fotiadis DI, Protopoulos VC, Mpozios GV, Katsouras CS, et al. In vivo validation of a novel semi-automated method for border detection in intravascular ultrasound images. *Br J Radiol*. 2005;78:122-9.
- Lujan ME, Chizen DR, Peppin AK, Krieglger S, Leswick DA, Bloski TG, et al. Improving inter-observer variability in the evaluation of ultrasonographic features of polycystic ovaries. *Reprod Biol Endocrinol*. 2008;6:30-40.