



Case report

Severe flare of Behcet's disease with intense mucocutaneous manifestations

José M. Martín,^{a,*} Elisabeth Mateo,^b Carlos Monteagudo,^c and Esperanza Jordá^a

^aServicios de Dermatología, Hospital Clínico Universitario, Valencia, Spain

^bMedicina Interna, Hospital General Universitario, Valencia, Spain

^cAnatomía Patológica, Hospital Clínico Universitario, Valencia, Spain

ARTICLE INFO

Article history:

Received November 2, 2009

Accepted May 5, 2010

Keywords:

Cytomegalovirus

Behcet's disease

ABSTRACT

Behcet's disease is a multisystemic inflammatory disease with various manifestations at the skin level, especially in the form of acne-like lesions or erythema nodosum. Susceptibility to this disease is strongly linked to the presence of the HLA_B51 allele, although certain environmental factors such as infectious agents have also been implicated in its pathogenesis. We present the case of a patient with Behcet's disease who developed a severe flare characterized by lesions similar to those seen in Sweet's syndrome. Histologically we observed granulomatous vasculitis.

© 2009 Elsevier España, S.L. All rights reserved.

Brote severo de la enfermedad de Behçet con manifestaciones mucocutáneas intensas

RESUMEN

La enfermedad de Behçet es un trastorno inflamatorio multisistémico que se manifiesta de forma muy variada a nivel cutáneo, especialmente en forma de lesiones acneiformes o de eritema nodoso. La susceptibilidad a padecer esta enfermedad se halla fuertemente ligada con la presencia del alelo HLA-B51, aunque determinados factores ambientales como agentes infecciosos también se han implicado en la patogénesis. Presentamos el caso de una paciente con una enfermedad de Behçet que desarrolló un brote severo con lesiones cutáneas análogas a las que se aprecian en el síndrome de Sweet. Histológicamente se apreciaron fenómenos de vasculitis granulomatosa.

© 2009 Elsevier España, S.L. Todos los derechos reservados.

Palabras clave:

Citomegalovirus

Enfermedad de Behçet

Introduction

Behcet's disease is a multi-systemic inflammatory disease that manifests itself by the appearance of recurrent mouth and genital ulcers and by skin and eye lesions. Lesions in the joints are also frequent and it affects the vascular and central nervous system as well.^{1,2} Fortunately, the majority of the time these manifestations are self-limited except for eye lesions, which can cause blindness

Although the pathogenic factors of Behcet's disease differ according to different geographic areas,³ susceptibility to this disease

is strongly linked to the human leukocyte antigen (HLA)-B51. Certain environmental factor such as infectious agents have also been implicated in the pathogenesis.^{1,4-6}

We present the case of a young woman with Behcet's disease who manifested a severe flare, with generalised skin-mucous lesions, arthritis and eye lesions, probably related to Cytomegalovirus (CMV).

Case report

A 39-year-old woman was admitted to be studied because of a flare of generalised oedematous-erythematous skin lesions, together with generalised arthralgias, and pronounced oedema on both ankles

* Corresponding author.

E-mail address: jmmart@eresmas.com (J.M. Martín).

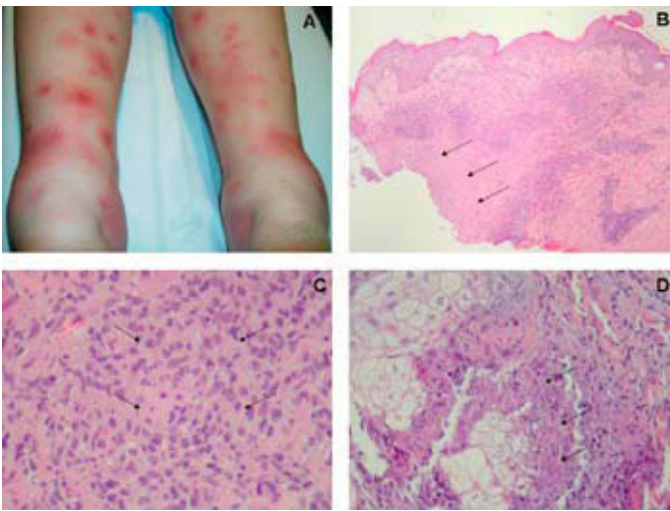


Figure. A) Oedematous-erythematous lesions found on the legs. B) Overview of a lesion, with necrosis at the centre and peripheral mononuclear infiltrates (H-E, $\times 40$). C) Detail granulomatous infiltrates from of epithelioid cells on the vascular walls with slight endothelium damage (H-E, $\times 500$). D) Detail of focal necrosis in some sebaceous glands (H-E, $\times 500$).

that practically made her unable to walk (Figure 1A). The patient also had a temperature (38°C), shivers and eye discomfort. Her clinical condition also manifested oral aphthous ulcers about 5 mm in diameter, as well as genital ones on the interior wall of the vulva, which were about 1 cm in size.

As medical records of interest, the patient suffered from recurrent bipolar aphthosis and various episodes of erythema nodosum over the last four years. Currently she was not taking any medication.

The skin lesions were made up from various size papules and oedematous-erythematous plaques, and very small pustules could be seen in the middle of the majority of these. They were distributed over nearly all the integument, as lesions were seen on the head, trunk and four limbs. A skin biopsy of one of them was carried out.

Histologically, an area of necrobiosis was seen on the reticular dermis, surrounded by a thick lymphohistiocytic infiltrate, also present at a perivascular level (Figure 1B), with a granulomatous pattern (Figure 1C). The infiltrate was superficial and deep, with focal necrosis seen in some sebaceous glands (Figure 1D).

The ulcerative genital lesion was also biopsied. It showed an area of epidermal ulceration with underlying granulation tissue and interstitial and perivascular inflammatory infiltrates in the skin, with neutrophils but with no signs of vasculitis.

The ophthalmological exploration showed a cotton-wool exudate in the right eye. An eye angiography was also performed, revealing that there were papillary telangiectasias in the right eye, with signs of diffuse vasculitis.

In the blood tests carried out on admittance, only a leukocytosis (7,600 leukocytes/mm) was seen with normal formulation. The blood count biochemistry was also normal. The C-reactive protein was 153 mg/L and the globular sedimentation speed was 68 mm/h.

Auto-immune studies were negative for ANCA, anti-glomerular basement membrane, antinuclear antibodies and anti-dsDNA. The blood cultures, as well as the BAAR sputum determination, were also negative. Serologies for human immunodeficiency virus, hepatitis B, hepatitis C and lues were also requested and were negative. Signs were present for positive IgG for antiviral herpes simplex (HSV) types 1+2 and human antiviral herpes, while the IgM for those viruses were negative, with IgM and IgG positive for CMV. A thorax-abdomen-pelvic CAT scan resulted insignificant. HLA determination showed positive for HLA A24, B45, B51 and BW4.

Antibiotic and anti-inflammatory treatment had initially been prescribed, with great clinical deterioration in the first few days, persistent high temperature, and the appearance of vesicular and pustular lesions in the centre of the initial plaques and nodules. Treatment was later started with 30 mg/d prednisone, with spectacular improvement in 48 h.

Discussion

Skin lesions in Behcet's disease are rare but very varied.² Among the most frequent primary skin damage are sterile papular-pustulose and vesicular-pustules, which are normally found on the limbs and face and that look like those found in intestinal inflammatory disease and intestinal derivation syndrome. Erythema nodosum is the skin manifestation that is observed in second place; it is mainly seen on the legs and buttocks, although exceptionally it can also appear on the face and neck.

Other less common manifestations are pseudofolliculitis and acne-like nodules. Although even rarer, inflammatory plaques with pustules that remind us of Sweet syndrome can also appear, like those seen on this patient. Lesions similar to pyoderma gangrenosum, erythema multiforme or palpable purpura lesions secondary to a vasculitis are also possible.^{1,7,8}

Microscopic changes are unspecific and varied. The anatomical pathology of skin lesions can be divided into 3 main categories: vascular, extravascular (with or without vascular pathology) and acne-like. Skin vasculopathy is capable of affecting any size vessels in the dermis and subcutaneous tissue. It can present itself as lymphocytic or leukocytoclastic vasculitis with or without venous thrombosis and necrosis. A predominance of histiocytes related to vasculitis is preferable, leading to a diagnosis of granulomatous vasculitis. A pattern similar to that characterised by Sweet syndrome through angio-centred neutrophil infiltrates that disintegrate can be seen, together with leukocytoclasia and extravasation of hematies. Vascular thrombosis is not infrequent and its presence must motivate the search for an underlying bleeding disorder.

Although the cause and pathogeny of Behcet's disease are still unknown, diverse infectious, immunological and genetic reasons have been put forward, but there is still no evident proof in favour of any of them. The pathological substrate is a leukocytoclastic, lymphocytic or (more rarely) granulomatous vasculitis, preferably of the capillaries and veins. Although infrequent, vessels of a larger size can also be affected.^{4,7} In endemic regions, such as the Mediterranean, this syndrome is closely related to the human leukocyte antigen HLA-B51, and up to 10% of those affected have some family member ill.

Certain infectious agents have also been implicated with the development of this illness, fundamentally herpes simplex virus (HSV). Several studies have shown antibodies against HSV-1 present in the blood of people with Behcet's disease in much larger quantities than in control groups, in the same way as with current immune complexes with antigenic HSV-1 material. The presence of genetic HSV material has also been seen in the genital and intestinal ulcers of patients with Behcet's disease, and test animals have developed clinical features with similar manifestations to Behcet's disease when they have been inoculated with HSV.⁶

Other viruses, including HCV, parvovirus B19 and Epstein-Barr virus, are also associated with this disease although less consistently.^{1,4,9} There is controversy in literature with regards to CMV, as in some studies an association with this virus to bipolar aphthosis and Behcet's disease has been demonstrated,¹⁰ whilst others suggest otherwise.^{11,12}

In this case, the evidence through serological examinations of positive IgM and IgG against CMV, and the rise of antibodies coinciding with the development of clinical manifestations that are

very different and much more aggressive than those the patient had had until then, suggest that CMV could have played an etiopathogenic role in the development of this flare. The necrosis on the sebaceous glands observed in the histology, which is a histological finding associated to infections with the herpes virus, would also support this hypothesis.

Conclusions

A flare of Behçet's disease is described, characterised by the impact of the mucocutaneous manifestations, which constitutes the predominant clinical manifestation.

Conflict of interest

The authors declare that they have no conflicts of interest.

References

1. Sakane T, Takeno M, Suzuki N, Inaba G. Behçet's disease. *New Engl J Med.* 1999;341:1284-91.
2. Balabanova M, Calamia KT, Perniciaro C, O'Duffy JD. A study of the cutaneous manifestations of Behçet's disease in patients from the United States. *J Am Acad Dermatol.* 1999;41:540-5.
3. Sanchez-Roman J, Castillo-Palma MJ, Torronteras Santiago R, Varela Aguilar JM, Lopez Checa F, Sanchez Garcia F. Type I herpes virus, HLA phenotype and Behçet disease. *Med Clin (Barc).* 1992;98:366-8.
4. Magro CM, Crowson AN. Cutaneous manifestations of Behçet's disease. *Int J Dermatol.* 1995;34:159-65.
5. Kaklamani VG, Variopoulos G, Kaklamani PG. Behçet's disease. *Semin Arthritis Rheum.* 1998;27:197-217.
6. Direskeneli H. Behçet's disease: infectious aetiology, new autoantigens, and HLA-B51. *Ann Rheum Dis.* 2001;60:996-1002.
7. Chen KR, Kawahara Y, Miyakawa S, Nishikawa T. Cutaneous vasculitis in Behçet's disease: a clinical and histopathologic study of 20 patients. *J Am Acad Dermatol.* 1997;36:689-96.
8. Alpsoy E, Uzun S, Azman A, Alpaslan Acar M, Memisoglu HR, Basaran E. Histologic and immunofluorescence findings of non-follicular papulopustular lesions in patients with Behçet's disease. *J Eur Acad Dermatol Venereol.* 2003;17:521-4.
9. Sun A, Chang JG, Chu CT, Liu BY, Yuan JH, Chiang CP. Preliminary evidence for an association of Epstein-Barr virus with pre-ulcerative oral lesions in patients with recurrent aphthous ulcers or Behçet's disease. *J Oral Pathol Med.* 1998;27:168-75.
10. Sun A, Chang JG, Kao CL, Liu BY, Wang JT, Chu CT. Human cytomegalovirus as a potential etiologic agent in recurrent aphthous ulcers and Behçet's disease. *J Oral Pathol Med.* 1996;25:212-8.
11. Lee EB, Kwon YJ, Shin KC, Song YW, Park CG, Hwang ES, et al. Decreased serum level of antibody against human cytomegalovirus in patients with Behçet's disease. *Rheumatol Int.* 2005;25:33-6.
12. Ghodrattnama F, Wray D, Bagg J. Detection of serum antibodies against cytomegalovirus, varicella zoster virus and human herpesvirus 6 in patients with recurrent aphthous stomatitis. *J Oral Pathol Med.* 1999;28:12-5.