

Clinical rheumatology in images

Chronic tophaceous gout

Gota tofácea crónica

María José Pérez Galán,^{a,*} María Carmen Ramírez Barberena,^a and María Dolores Manjón García^b

^aServicio de Reumatología, Complejo Hospitalario de Jaén, Jaén, Spain

^bServicio de Medicina Interna, Complejo Hospitalario de Jaén, Jaén, Spain

Case report

Forty-three-year old male, consumer of 2 litres (80 ounces) of beer every day for the past 21 years. Fifteen years ago, he presented acute pain along with monoarticular inflammation of the lower limbs. At first he presented 2-3 annual episodes of monoarthritis, which improved with non-steroidal anti-inflammatory drugs. The patient did not follow the pharmaceutical treatment or the hygienic-dietetic measures recommended by his general practitioner correctly, so his monoarthritic crises became more frequent, extending to affectation of upper limb joints; the clinical picture evolved to oligoarthritis and finally to polyarthritis.

He currently attended consultation due to worsening of inflammatory arthralgias in the hands and feet, along with deformity, which made daily activities difficult. Physical exploration highlighted the presence of tophi at the level of the elbows, feet, and hands, some of them complicated with fistula to the exterior (Figures 1A and 1B), where the presence of monosodium urate crystals was observed. Laboratory tests detected uricemia a level of 8.3, with the rest of basic biochemistry at normal levels. Tests for blood count, acute phase reactants, rheumatoid factor, and citrullinated antibodies were normal or negative. Bone X-rays of the hands and feet showed increased soft tissue, along with the presence of significant bone erosion with sclerotic margins, highlighting a small, thin calcified line,¹ characteristic of gouty arthropathy (Figures 2A and 2B).

Diagnosis

Chronic tophaceous gout.

Evolution

The patient's symptoms improved after ceasing alcohol intake (beer) and starting treatment with colchicine, analgesics, and allopurinol.²

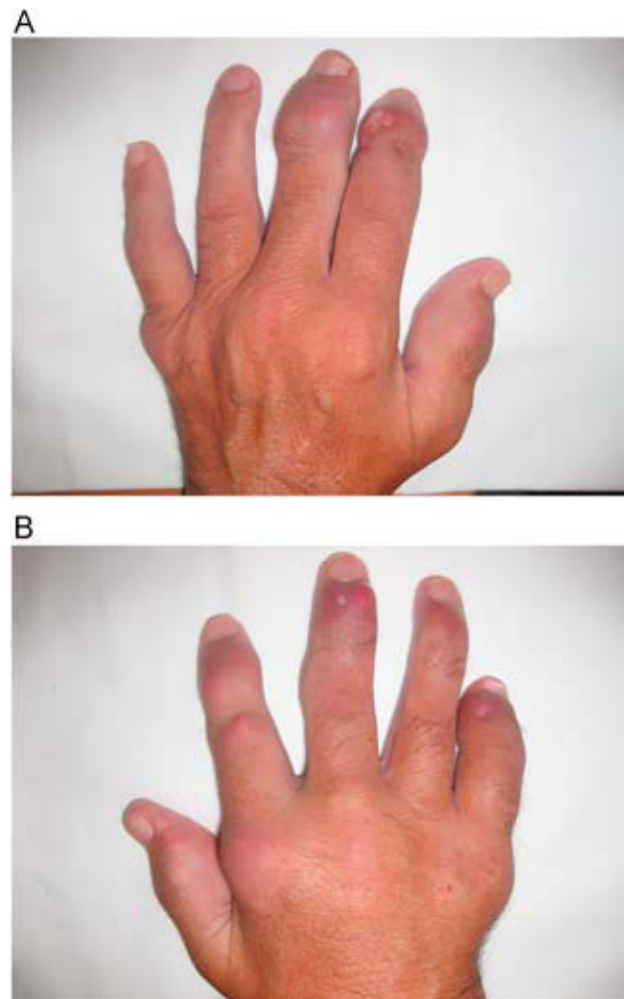


Figure 1. Swollen joints and tophi in the left hand (A) and right hand (B).

*Corresponding author.

E-mail address: mjpg77@hotmail.com (M.J. Pérez Galán).

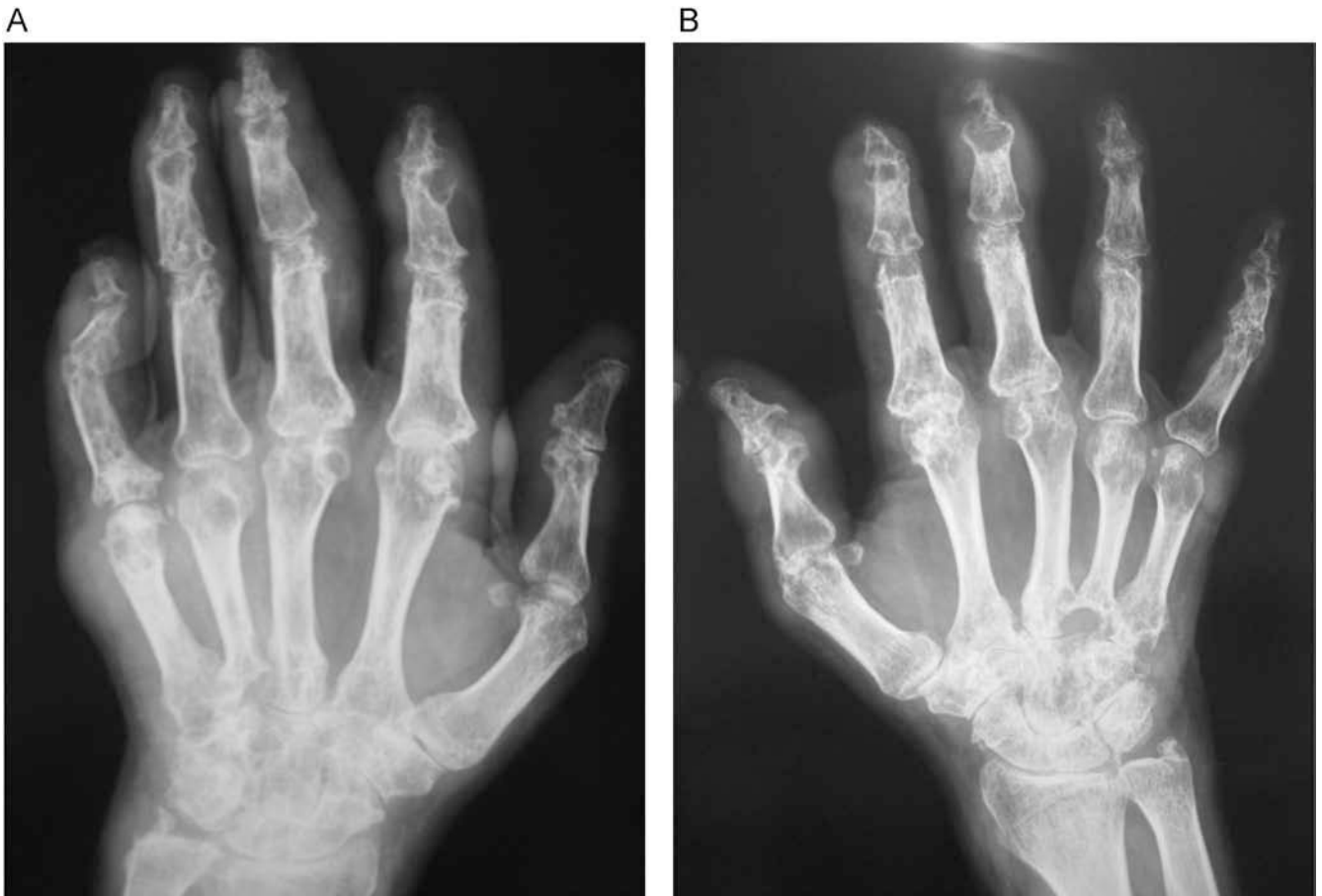


Figure 2. Bone X-ray with increased soft tissues and erosion in the left hand (A) and right hand (B).

Discussion

Gouty arthropathy is a common pathology in rheumatology consultations. Currently, the general population knows about its predisposing factors and, because it generally responds very well to treatment unless the patient does not comply with it correctly, it is less common to find patients with such severe bone involvement. In this case, surgical intervention was considered, because of the difficulty that the patient suffered for the performance of daily activities as a consequence of the tendinous infiltration of tophi. Surgical intervention was eventually ruled out due to the elevated risk of postoperative infection.^{3,4}

This case reminds us of the severe osteoarticular damage that a hyperuricemic arthropathy can cause when not treated correctly.

References

1. Choi MH, MacKenzie JD, Dalinka MK. Imaging features of crystal-induced arthropathy. *Rheum Dis Clin North Am.* 2006;32:427–46.
2. Tausche AK, Jansen TL, Schröder HE, Bornstein SR, Aringer M, Müller-Ladner U. Gout—current diagnosis and treatment. *Dtsch Arztebl Int.* 2009;106:549–55.
3. Kumar S, Gow P. A survey of indications, results and complications of surgery for tophaceous gout. *N Z Med J.* 2002;26;115(1158):U109. Erratum in: *N Z Med J.* 2002;23;115(1160):1.
4. Lee SS, Sun IF, Lu YM, Chang KP, Lai CS, Lin SD. Surgical treatment of the chronic tophaceous deformity in upper extremities—the shaving technique. *J Plast Reconstr Aesthet Surg.* 2009;62:669–74.