

Review Article

Recurrent Aphthous Stomatitis in Rheumatology[☆]

Gabriel Riera Matute,^{a,*} Elena Riera Alonso^b

^a Servei de Reumatologia, Centre d'Espesialitats Güell, Hospital Universitari de Girona Doctor Josep Trueta, Girona, Spain

^b Servei de Reumatologia, Hospital Universitari Mútua Terrassa, Terrassa, Barcelona, Spain

ARTICLE INFO

Article history:

Received 1 March 2011

Accepted 17 May 2011

Keywords:

Oral ulcers

Recurrent aphthous stomatitis

Complex aphthosis

ABSTRACT

Recurrent aphthous stomatitis consists on recurring oral ulcers of unknown etiology. Oral ulcers may be different in number and size depending on the clinical presentation, which also determines the time needed for healing. Moreover, there are factors associated to outbreaks but not implicated in its etiopathogenesis. When oral aphthosis has a known etiology, it is not considered as recurrent aphthous stomatitis. The severity and the clinical presentation helps in the differential diagnosis. Treatment is symptomatic in recurrent aphthous stomatitis while, if there is an underlying systemic disease, the treatment of such disease is need in addition to topical treatment.

© 2011 Elsevier España, S.L. All rights reserved.

Palabras clave:

Aftosis oral recurrente

Estomatitis aftosa recurrente

Aftosis compleja

La aftosis oral recurrente en Reumatología

RESUMEN

La aftosis oral recurrente consiste en la aparición de episodios repetidos de úlceras sin que exista una causa conocida. Son úlceras orales en número y tamaño variable según la forma de presentación, la cual también condiciona el tiempo necesario para la curación. Existen factores que favorecen su aparición, pero no son causales. En determinados casos, los brotes de aftosis tienen una causa conocida y entonces no se considera una aftosis oral recurrente. La forma de presentación de las úlceras y su gravedad son claves en el diagnóstico diferencial. El tratamiento es sintomático en la aftosis oral recurrente, mientras que si existe una causa sistémica de base el tratamiento será el indicado en este caso además del tópico.

© 2011 Elsevier España, S.L. Todos los derechos reservados.

Introduction

Aphtae (Greek aphtai, burn) are ulcerated lesions that sit on the mucosal surface where, unlike erosion, loss of continuity involves the whole epithelial lining and may affect the underlying connective tissue.

Aphthosis presents with ulcerated oral lesions (aphtae), which are often painful and self-limiting. The causes of oral ulcers are diverse: infectious skin diseases, cancer, hematological diseases, gastrointestinal diseases, rheumatic diseases, drugs, and radiotherapy (Table 1).^{1–4} They appear almost always in non-keratinized areas of the mouth found on the mucosal lining (inside of the cheeks, inner lips, soft palate, ventral tongue, and floor of the mouth), but are not exceptional in the keratinized surface that con-

stitutes the masticatory mucosa (gingiva and hard palate), or even the specialized mucosa, which is located in the epithelium of the dorsal tongue. They are considered acute if lasting less than six weeks or chronic if they last longer. When in the form of recurrent oral outbreaks in the absence of a systemic cause, they are referred to as recurrent oral aphthosis (ROA) or recurrent aphthous stomatitis.

Epidemiology

ROA is one of the most common oral disorders with a prevalence that varies across the studied populations,⁵ but that approximately 20% of the general population suffers at some point in their lives. There is a familial aggregation and is more common in women. It usually starts in childhood, adolescence, or young adults under 30, tending to decrease over time, both in severity and frequency.⁶

[☆] Please cite this article as: Riera Matute G, Riera Alonso E. La aftosis oral recurrente en Reumatología. Reumatol Clin. 2011. doi:10.1016/j.reuma.2011.05.003.

* Corresponding author.

E-mail address: grieramatute.girona.ics@gencat.cat (G. Riera Matute).

Table 1
Main Causes of Oral Ulcers.

<i>Infectious disease</i>
Herpetic stomatitis
Chicken pox
Herpes zoster
Coxsackie Virus (hand-foot disease, herpangina)
Infectious Mononucleosis
HIV infection ^a
Acute necrotizing gingivitis
<i>Mycobacterium tuberculosis</i>
<i>Treponema pallidum</i>
Fungal infections
Protozoal infections (leishmania)
<i>Malignant tumors</i>
<i>Blood diseases</i>
Anemia
Leukemia
Neutropenia
White cell dyscrasia
<i>Gastrointestinal diseases</i>
Celiac disease
Crohn's disease
Ulcerous colitis
<i>Skin diseases</i>
Lichen planus
Pemphigus
Penphigoid
Erythema multiformis
Herpetiform dermatitis
Lineal IgA disease
Ampule Epidermolysis
Chronic ulcerous stomatitis
Other dermatosis
<i>Rheumatic diseases</i>
Lupus erithematosus
Behçet's syndrome
MAGIC ^b syndrome
Sweet syndrome
Reactive arthritis
Wegener's granulomatosis
PFAPA ^c syndrome
<i>Drugs (Table 4)</i>
<i>Radiotherapy</i>

Source: Modified from Scully et al.²

^a Human immunodeficiency virus.

^b Mouth and Genital ulcers with inflamed cartilages.

^c Periodic fever, aphthous stomatitis, pharyngitis, cervical Adenitis.

Pathogenesis

The etiology and pathogenesis of ROA are unknown so far. It is likely that in genetically predisposed individuals, immune dysfunction linked to various triggers facilitates the development of aphthosis. Local immunological dysfunction could be related to increased T-lymphocyte subpopulations (CD4 and CD8), and plays an important role in altered immune responses in which the initial stimulus is not known. Changes in serum levels of immunoglobulins have also been described, which may play a role in the pathogenesis of ulcers and alterations in cell adhesion molecules that are essential to maintain a stable structure of the oralepithelium have been reported.^{7–11}

Possible local and general factors have been implicated and may favor the development or worsening of ulcers¹²:

1. Genetic. There is a familial aggregation, and some studies have correlated ROA to HLA^{13–15} antigens. The chance of developing aphthous lesions is 90% in people with two parents who present them, reduced to 20% in those in which parents have never presented them.¹⁶

- Immune imbalance in relation to likely immune events triggered by transitory immunodeficiency.¹⁷
- Infections probably mean little. There is evidence of possible cross-reactivity between bacterial antigens and the oral mucosa. Potential associations with infection by *Helicobacter pylori*¹⁸ as well as human herpes virus-6¹⁹ have been seen.
- Mechanical trauma²⁰ (bites, dentures, toothbrushes, etc.), thermal or chemical lesions. ROA has been related to the local irritant action of sodium lauryl sulfate, a surfactant used in many types of toothpaste, which can influence people with ROA.²¹
- Smoking cessation. In non-smokers there is decreased keratinization of the mucosa which is more sensitive, though, when lesions are present; when smoking, there is no effect on their severity.²²
- Deficiency of vitamins and minerals like iron, folic acid and vitamin B12 in patients with frequent ROA, without significant differences while studying each element separately.²³ In other studies there is a significant association with vitamin A and B12²⁴ and B1²⁵ vitamin deficiency.
- Hypersensitivity to foods (chocolate, cheese, citrus, tomatoes, seafood, etc.).^{26,27} Often allergy or food intolerance is associated with atopy, and in patients with a family history of ROA, a significant association with a history of atopy²⁸ has been seen.
- Hormonal changes. ROA has often been associated with the menstrual cycle, but this relationship has not been established clearly.²⁹
- Stress. It may play a role as a triggering or modifying factor rather than causing ROA.^{30,31}

Clinical Manifestations

The lesions are initiated by an inflammatory foci in the form of painful erythematous macules. Within hours, keratolysis mediated by cytokines leads to a shallow, rounded or oval, well-defined ulcer, with a raised inflammatory halo in which microscopically one can observe a large numbers of neutrophils, lymphocytes, and monocytes. The center is necrotic and covered by a yellowish-gray pseudomembrane (Fig. 1). They present centrifugal growth and healing is achieved by re-epithelialization from the edges.

Their presence may hinder speech, eating, and swallowing. Pain is similar to that resulting from a burn, and increases with contact with hot foods and spices.

There are three different forms of presentation of ulcers in ROA: minor, major, and herpetiform.³²

- Minor aphthosis is the most common. It usually affects non-keratinized mucosa, especially the lips, cheeks, and sides of the

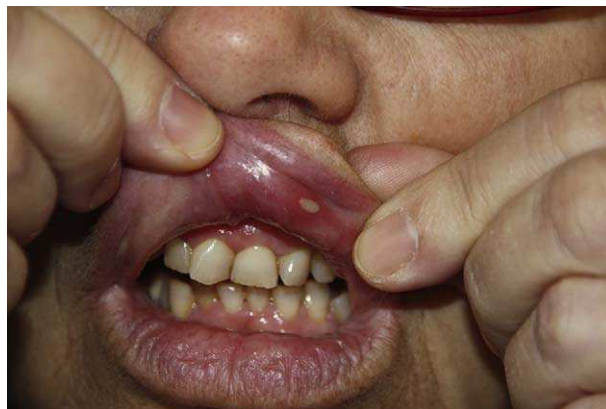

Fig. 1. Lesions start through an inflammatory foci in the form of erythematous painful macules.

tongue. It is characterized by single or few ulcers (less than 5) with a size of less than 1 cm. They are usually concentrated in the front of the mouth, and often occur 2–4 times a year. They present spontaneous healing without scarring in 1–2 weeks.

- Major aphthosis is less common. It typically affects the keratinized and non-keratinized mucosa, especially the soft palate. It occurs in the form of single or few ulcers (less than 5) of a size equal to or greater than 1 cm. They usually have a predilection for the back of the mouth. They are deeper and more painful than minor aphthae. It takes 2–12 weeks to heal and leave a scar.
- Aphthosis herpetiformis is the least common. It usually affects non-keratinized mucosa, especially the floor of the mouth and ventral surface of the tongue. It usually has a later onset than the two previous forms, occurring in the second or third decade of life. It manifests with a variable number of ulcers (10–100) with a size of 1–3 mm appearing simultaneously and can coalesce. It takes 1–4 weeks to heal and may leave scars, especially in the coalescing ulcers.

Differential Diagnosis

The presentation of oral aphtae helps in the differential diagnosis. According to it, diagnosis can be guided according to whether it is a solitary ulcer, recurrent episodes of one or more ulcers that heal spontaneously, a single episode preceded by blisters, ulcers affecting multiple oral locations, or persistent oral aphthosis affecting different sites (Table 2).³² With the emergence of recurrent episodes of one or more ulcers that heal spontaneously, the differential diagnosis must be made between recurrent aphthous stomatitis, Behçet's disease, aphthous-like-ulcers due to systemic diseases or drugs and recurrent erythema multiforme.

Table 2
Main Causes of Oral Ulcers According to Their Presentation.

<i>Single ulcer</i>
Trauma
Squamous carcinoma
Infections (syphilis, tuberculosis)
<i>Spontaneous episodes of one or more ulcers that heal spontaneously</i>
Recurrent aphthous stomatitis
Behçet's disease
"Aphthous-like-ulcers" due to systemic disease or drugs
Recurrent erythema multiformis
<i>Single episode of vesicle preceded ulcers which affect multiple oral localizations</i>
Viral infections (herpangina, primary herpetic stomatitis)
Erythema multiformis
<i>Persistent oral ulcers affecting different localizations</i>
Skin and mucosa (oral lichen planus)
Autoimmune ampules (oral pemphigus)
Gastrointestinal (Crohn's disease)
Hematological (leukemia)
Drugs

Source: Modified from Field et al.³²

In addition to the presentation of oral aphtae, the severity of clinical manifestations of oral aphthosis also helps to make the differential diagnosis. With this criterion they are classified as simple aphthosis and aphthosis complex (Fig. 2).^{33–36} Simple aphthosis presentation is more frequent.¹ It presents with recurrent oral lesions in any of the three ways (minor, major or herpetiformis), usually with 3–6 episodes per year that are of short duration and resolve spontaneously, allowing the diagnosis of ROA. Aphthosis complex manifests prolonged outbreaks that

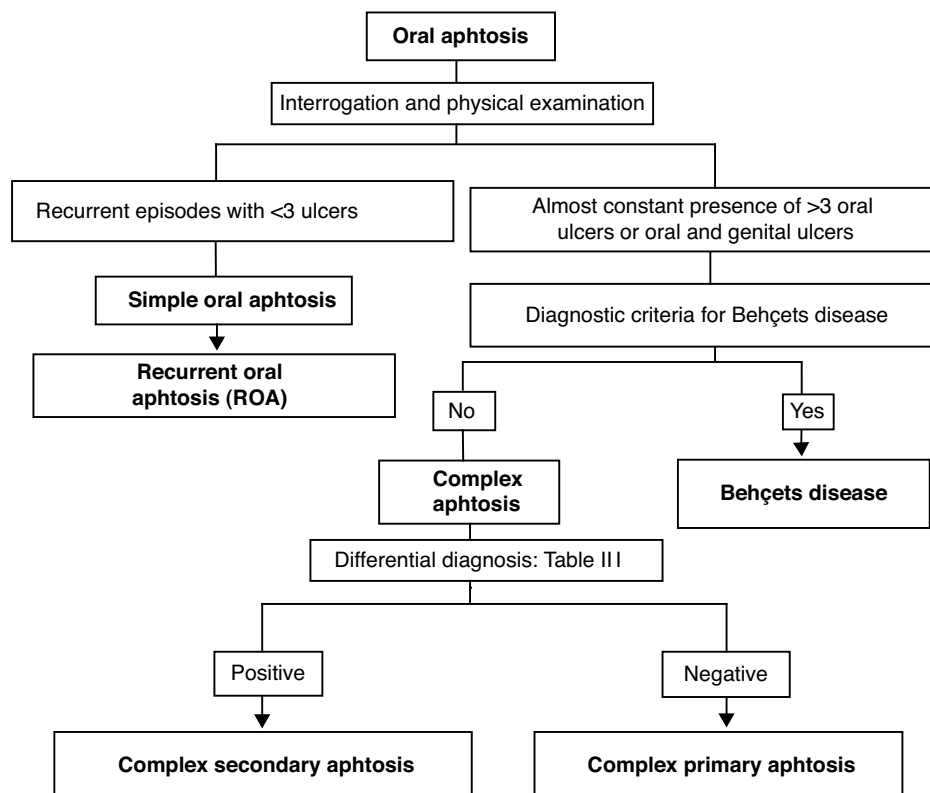


Fig. 2. Diagnostic algorithm for ROA differential diagnosis.
Source: Modified from Letsinger et al.³⁵

Table 3
Clinical Classification of Ulcers.

Simple aphthosis: recurrent attacks of minor, major or herpetiform ulcers, with disease free periods, mostly in young persons (ROA)
Complex aphthosis: almost constant presence of ≥ 3 oral ulcers or recurrent oral and genital ulcers. Excluding Behçet's disease, it may be: Primary or idiopathic complex aphthosis
Complex secondary aphthosis:
Intestinal inflammatory disease
HIV infection (human immunodeficiency virus)
Cyclic neutropenia
PFAPA syndrome ("Periodic Fever, Aphthous stomatitis, Pharyngitis, cervical Adenitis")
Iron, zinc, folate or vitamin B ₁ , B ₂ , B ₆ , B ₁₂ deficiency
Gluten enteropathy
Behçet's disease
MAGIC syndrome ("Mouth And Genital ulcers with Inflamed Cartilages")

Source: Modified from Letsinger et al.³⁵

are often continuous, with three or more oral lesions and may be associated with genital or perianal ulcers.

Faced with a complex oral aphthosis, the first step should be to rule out Behçet's disease. Once the diagnosis has been excluded, oral aphthosis complex can be classified as primary or secondary.

To establish the diagnosis of primary complex aphthosis, one must discard all the processes that can produce and that would classify it as secondary (Table 3),³⁵ but even so, it should be noted that the diagnosis of Behçet's disease can be difficult in the early stages and may be delayed up to several years, which justifies a careful follow-up of all patients diagnosed with complex primary aphthosis.³⁷

Secondary complex oral aphthosis may be a sign of many systemic processes that may present with episodes similar to recurrent oral aphthosis. The most common is inflammatory bowel disease, of which it may be its first manifestation.

In clinical rheumatology practice it is not uncommon to find ulcers secondary to certain drugs and some diseases with joint manifestations.

As for drugs, there have been many cases of oral ulceration in relation to them, and among them, several are commonly used in rheumatology, even to treat systemic diseases, which in turn can cause oral aphthosis (Table 4).³⁸⁻⁴²

With regard to the systemic diseases that may have joint involvement (arthritis or joint pain), some include the presence of ulcers among their diagnostic criteria:

1. Lupus erythematosus: oral or nasopharyngeal ulcers, usually painless, observed by a physician.⁴³
2. Behçet's disease: recurrent oral ulcers (major, minor or herpetiform aphthosis) seen by a physician or patient and having occurred at least three times in a period of 12 months.⁴⁴
3. Wegener's granulomatosis: oral or nasal inflammation to the development of painful or painless oral ulcers or purulent or bloody nasal discharge.⁴⁵
4. Crohn's disease: multiple small aphthous ulcerations in the upper and lower digestive tract, not necessarily with longitudinal organization, for at least three months, plus caseous granulomas.⁴⁶
5. PFAPA syndrome ("Periodic Fever, aphthous stomatitis, pharyngitis, cervical adenitis"): oral ulcers.⁴⁷

Other systemic diseases that have or may have joint involvement, and sometimes present with oral ulcers, but their presence is not included among diagnostic criteria:

1. Reactive arthritis may be present and typically are not painful.⁴⁸
2. Sjögren's syndrome: a dry oral mucosa often present ulcers.⁴⁹
3. Sweet syndrome or acute neutrophilic febrile dermatosis.^{50,51}
4. Ulcerative colitis: ulcers are more prevalent than those found in a control group of patients with functional disorders of intestinal motility,⁵² but are more persistent and tend to be larger.⁵³

Another syndrome that may be considered in the differential diagnosis of rheumatic diseases capable of producing an oral aphthosis complex is the MAGIC ("mouth and genital ulcers with inflamed cartilage") syndrome, which has no established diagnostic criteria, but is manifested by an overlap between Behçet's syndrome in which recurrent ulcers are a diagnostic criterion and relapsing polychondritis.⁵⁴

Treatment

Lack of knowledge regarding the cause of ROA makes it impossible to cure the disease. Existing symptomatic treatments are directed at reducing pain, shortening the healing of ulcers, and increasing the length of asymptomatic periods between attacks. When ulcers are small, with few symptoms and infrequent, topical treatment along with dietary measures such as avoiding foods that can worsen ulcers is sufficient, including those that due to their hard texture could erode the oral mucosa. If identified precipitating

Table 4
Drugs That Produce Oral Ulcers.

Alendronate	Diclofenac	Interferon	Penicillamine
Alprazolam	Dideoxycytidine	Interleukin-2	Penicillin
Allopurinol	Diltiazem	Imipramine	Potassium
Aspirin	Disopiramide	Isoprenaline	Proguanile
Atorvastatin	Docetaxel	Ketorolac	Promethazine
Aurothiomalate	Doxorrubicine	Lamotrigin	Propanolol
Azathioprine	Emepronius-Bromide	Leflunomide	Propilthiouracil
Aztreonam	Enalapril	Levamisole	Quinidine
Barbiturates	Erythromicine	Lythium	Ritonavir
Bleomiyicin	Everolimus	Losartan	Sachinavir
Captopril	Phenilbutazone	Melphan	Sertraline
			Streptomycin
Carbamazepine	Phenindione	Metamizole	Sulphonamides
Cyclosporine	Phenitoin	Methotrexate	Sulindac
Cisplatin	Fluconazole	Metronidazole	Terbutaline
Citarabine	Flunisolide	Mitomycin	Tetracyclines
Clarithromicina	Fluoxetin	Molgramostim	Vancomycin
Clonazepam	Gancyclovir	Naproxen	Vincristin
Chloranphenicol	Hydralazine	Nicorandil	Venlaphaxine
Chloroquine	Hydroxiurea	Niphedipine	Warfarin
Chloropromacine	Ibuprofen	Olanzapine	Zidovudin
Codeine	Indomethacin	Pancreatine	

factors can be corrected, and act on them. If there is a basic process that explains the appearance of aphthosis, treatment of it leads to improvement.

A systematic review of the outcome of various topical treatments used in ROA reached the following conclusions as to their ability to decrease the incidence of ulcers and their analgesic power⁵⁵:

1. Chlorhexidine
 - a. Incidence of ulcer. Compared with placebo mouthwash may be more effective in reducing the severity, incidence and duration of the ulcer (very low quality evidence).
 - b. Analgesia. Compared with placebo gel may be more effective in reducing pain (very low quality evidence).
2. Hexetidine
 - a. Incidence of ulcer. Compared with placebo may not be more effective in reducing the severity, incidence and duration of the ulcer (very low quality evidence).
 - b. Analgesia. Compared with placebo may not be more effective in reducing pain (very low quality evidence).
3. Carbenoxolone gel or mouthwash
 - a. Incidence of ulcer. Compared with placebo mouthwash may be more effective in reducing the number of ulcers (very low quality evidence).
 - b. Analgesia. Compared with placebo mouthwash may be more effective in reducing pain (very low quality evidence).
4. Topical corticosteroids
 - a. Incidence of ulcer. Compared with placebo may be more effective in reducing the incidence of new ulcers and their duration (very low quality evidence).
 - b. Analgesia. Compared with placebo may be quicker to reduce the amount and duration of pain without causing adverse local or systemic events (very low quality evidence).
5. Local anesthetic: benzidamide mouthwash
 - a. Incidence of ulcer. Compared with placebo may not be more effective in reducing the incidence of new ulcers (very low quality evidence).
 - b. Analgesia. Compared with placebo may not be more effective in reducing pain, but may be preferred for its transient topical analgesic effect (very low quality evidence).
6. Tetracycline mouthwash
 - a. Analgesia. Compared with placebo may be more effective in reducing pain (very low quality evidence).

Other topical treatments such as sucralphate⁵⁶ have also been proposed, which act by forming a protective film on the bottom of the oral ulcers, reducing pain and shortening healing time. Amlexanox 5% also leads to a rapid healing of ulcers when applied as oral ointment.⁵⁷

Local cauterization by caustic solutions such as silver nitrate⁵⁸ has been employed. Cryotherapy with liquid nitrogen has been used, but has not shown greater analgesic effect than placebo.⁵⁹ Laser treatment⁶⁰ has also been used, as has low intensity ultrasound.⁶¹

If ROA presents with recalcitrant recurrent episodes several systemic treatments have been recommended with varying success, including: steroids,⁶² pentoxiphylin,⁶³ levamisole,⁶⁴ colchicine and dapsone,⁶⁵ thalidomide,^{66,67} biologic drug⁶⁸ treatment,⁶⁹ clophazimine,⁷⁰ and others (methotrexate, azathioprine, cyclosporine, cyclophosphamide, etc.).^{71,72}

Conflict of interest

The authors have no conflict of interest to declare.

References

1. Scully C. Aphthous ulceration. *N Engl J Med.* 2006;355:165–72.
2. Scully C, Shotts R. ABC of oral health, mouth ulcers and other causes of orofacial soreness and pain. *BMJ.* 2000;321:162–5.
3. Porter SR, Leao JC. Review article: oral ulcers and its relevance to systemic disorders. *Aliment Pharmacol Ther.* 2005;21:295–306.
4. Rogers III RS. Recurrent aphthous stomatitis: clinical characteristics and associated systemic disorders. *Semin Cutan Med Surg.* 1997;16:278–83.
5. Porter SR, Scully C, Pedersen A. Recurrent aphthous stomatitis. *Crit Rev Oral Biol Med.* 1998;9:306–21.
6. Scully C, Gorsky M, Lozada-Nur F. The diagnosis and management of recurrent aphthous stomatitis: a consensus approach. *J Am Dent Assoc.* 2003;134:200–7.
7. Rogers III RS. Recurrent Aphthous stomatitis: clinical characteristics and evidence for an immunopathogenesis. *J Invest Dermatol.* 1977;69:499–509.
8. Eversole LR. Immunopathogenesis of oral lichen planus and recurrent aphthous stomatitis. *Semin Cutan Med Surg.* 1997;16:284–94.
9. Correnti M, Gutiérrez R, Perrone M. Factores inmunológicos y microbiológicos asociados con la etiología de la estomatitis aftosa recurrente. *Acta odontol venez.* 2008;46:531–8.
10. Correnti M, Gutiérrez R, Perrone M, Ávila M. Expresión de moléculas de adhesión y subpoblaciones linfocitarias en lesiones de pacientes con estomatitis aftosa recurrente. *Acta odontol venez.* 2009;47:79–81.
11. Gutiérrez R, Correnti M, Perrone M, De Guglielmo A. Determinación de subpoblaciones linfocitarias en lesiones de pacientes con estomatitis aftosa recurrente. *Acta odontol venez.* 2008;46:144–50.
12. Ortiz Vega AP, Chimenos Küstner E. Diagnóstico diferencial de las úlceras orales. *Piel.* 2002;17:119–27.
13. Jaber L, Weinberger A, Klein T, Yaniv I, Mukamel M. Close association of HLA-B52 and HLA-B44 antigens in Israeli Arab adolescents with recurrent aphthous stomatitis. *Arch Otolaryngol Head Neck Surg.* 2001;127:184–7.
14. Albanidou-Farmaki E, Deligiannidis A, Markopoulos AK, Katsares V, Farmakis K, Parapanissiou E. HLA haplotypes in recurrent aphthous stomatitis: a mode of inheritance? *Int J Immunogenet.* 2008;35:427–32.
15. Wilbelmsen NS, Weber R, Monteiro F, Kalil J, Miziara ID. Correlation between histocompatibility antigens and recurrent aphthous stomatitis in the Brazilian population. *Braz J Otorhinolaryngol.* 2009;75:426–31.
16. Femiano F, Lanza A, Buonaiuto C, Gombos F, Nunziata M, Piccolo S, et al. Guidelines for diagnosis and management of aphthous stomatitis. *Pediatr Infect Dis J.* 2007;26:728–32.
17. Albanidou-Farmaki E, Markopoulos AK, Kalogerakou F, Antoniadis DZ. Detection, enumeration and characterization of T helper cells secreting type 1 and type 2 cytokines in patients with recurrent aphthous stomatitis. *Tohoku J Exp Med.* 2007;212:101–5.
18. Albanidou-Farmaki E, Giannoulis L, Markopoulos A, Fotiades S, Aggouridaki X, Farmakis K, et al. Outcome following treatment for *Helicobacter pylori* in patients with recurrent aphthous stomatitis. *Oral Dis.* 2005;11:22–6.
19. Ghodrathnama F, Wray D, Bagg J. Detection of serum antibodies against cytomegalovirus, varicella zoster virus and human herpesvirus 6 in patients with recurrent aphthous stomatitis. *J Oral Pathol Med.* 1999;28:12–5.
20. Wray D, Graykowski EA, Notkins AL. Role of mucosal injury in initiating recurrent aphthous stomatitis. *Br Med J (Clin Res Ed).* 1981;283:1569–70.
21. Fakhry-Smith S, Din C, Nathoo SA, Gaffar A. Clearance of sodium lauryl sulphate from the oral cavity. *J Clin Periodontol.* 1997;24:313–7.
22. Sawair FA. Does smoking really protect from recurrent aphthous stomatitis? *Ther Clin Risk Manag.* 2010;6:573–7.
23. Barnadas MA, Remacha A, Condomines J, Moragas JM. Hematologic deficiencies in patients with recurrent oral aphthae [Article in Spanish]. *Med Clin (Barc).* 1997;109:85–7.
24. Piskin S, Sayan C, Durukan N, Senol M. Serum iron, ferritin, folic acid, and vitamin B₁₂ levels in recurrent aphthous stomatitis. *J Eur Acad Dermatol Venereol.* 2002;16:66–7.
25. Haisraeli-Shalish M, Livneh A, Katz J, Doolman R, Sela BA. Recurrent aphthous stomatitis and thiamine deficiency. *Oral Surg Oral Med Oral Pathol Oral Radiol Endod.* 1996;82:634–6.
26. Wray D, Vlagopoulos TP, Siraganian RP. Food allergens and basophil histamine release in recurrent aphthous stomatitis. *Oral Surg Oral Med Oral Pathol.* 1982;54:388–95.
27. Wardhana, Datau EA. Recurrent aphthous stomatitis caused by food allergy. *Acta Med Indones.* 2010;42:236–40.
28. Veller-Fornasa C, Bezze G, Rosin S, Lazzaro M, Tarantello M, Cipriani R. Recurrent aphthous stomatitis and atopy. *Acta Derm Venereol.* 2003;83:469–70.
29. McCartan BE, Sullivan A. The association of menstrual cycle, pregnancy, and menopause with recurrent oral aphthous stomatitis: a review and critique. *Obstet Gynecol.* 1992;80:455–8.
30. Soto Araya M, Rojas Alcayaga G, Esguep A. Association between psychological disorders and the presence of oral lichen planus, Burning mouth syndrome and Recurrent aphthous stomatitis [Article in English, Spanish]. *Med Oral.* 2004;9:1–7.
31. Gallo CB, Mimura MAM, Sugaya NN. Psychological stress and recurrent aphthous stomatitis. *Clinics.* 2009;64:645–8.
32. Field EA, Alland RB. Review article: oral ulceration-aetiopathogenesis, clinical diagnosis and management in the gastrointestinal clinic. *Aliment Pharmacol Ther.* 2003;18:949–62.

33. Jorizzo JL, Taylor RS, Schmalstieg FC, Solomon AR, Daniels JC, Rudloff HE, et al. Complex aphthosis: a forme frustre de Behçet's syndrome. *J Am Acad Dermatol.* 1985;13:80–4.
34. McCarty MA, Garton RA, Jorizzo JL. Complex aphthosis and Behçet's disease. *Dermatol Clin.* 2003;21:41–8, vi.
35. Letsinger JA, McCarty MA, Jorizzo JL. Complex aphthosis: a large case series with evaluation algorithm and therapeutic ladder from topicals to thalidomide. *J Am Acad Dermatol.* 2005;52:500–8.
36. Espinosa-Garriga G. ¿Qué hacer ante un paciente con aftas orales recurrentes? *JANO* 9 December 2005–12 January 2006; No. 1589:37–41. Available from: <http://www.jano.es/ficheros/sumarios/1/0/1589/37/1v0n1589a13083151.pdf001.pdf>.
37. Gürler A, Boyvat A, Türsen U. Clinical manifestations of Behçet's disease: an analysis of 2147 patients. *Yonsei Med J.* 1997;38:423–7.
38. Scully C, Bagan JV. Adverse drug reactions in the orofacial region. *Crit Rev Oral Biol Med.* 2004;15:221–39.
39. Bascones-Martínez A, Figuero-Ruiz E, Esparza-Gómez GC. Oral ulcers [Article in Spanish]. *Med Clin (Barc).* 2005;125:590–7.
40. Göker E, Rodenhuis S. Early onset of oral aphthous ulcers with weekly docetaxel. *Neth J Med.* 2005;63:364–6.
41. Abdollahi M, Rahimi R, Radfar M. Current opinion on drug-induced oral reactions: a comprehensive review. *J Contemp Dent Pract.* 2008;9:1–15.
42. Sasaoka T, Kato TS, Oda N, Wada K, Komamura K, Asakura M, et al. Common occurrence of everolimus-associated aphthous stomatitis in Japanese heart transplant recipients. *Transplant Proc.* 2010;42:3700–3.
43. Tan EM, Cohen AS, Fries JF, Masi AT, McShane DJ, Rothfield NF, et al. The 1982 revised criteria for the classification of systemic lupus erythematosus. *Arthritis Rheum.* 1982;25:1271–7.
44. Criteria for diagnosis of Behçet's disease. International Study Group for Behçet's Disease. *Lancet.* 1990;335:1078–80.
45. Leavitt RY, Fauci AS, Bloch DA, Michel BA, Hunder GG, Arend WP, et al. The American College of Rheumatology 1990 criteria for the classification of Wegener's granulomatosis. *Arthritis Rheum.* 1990;33:1101–7.
46. Yao T, Matsui T, Hiwatashi N. Crohn's disease in Japan: diagnostic criteria and epidemiology. *Dis Colon Rectum.* 2000;43 10 Suppl:S85–93.
47. Thomas KT, Feder Jr HM, Lawton AR, Edwards KM. Periodic fever syndrome in children. *J Pediatr.* 1999;135:15–21.
48. Willkens RF, Arnett FC, Bitter T, Calin A, Fisher LL, Ford DK, et al. Reiter's syndrome, evaluation of preliminary criteria for definite disease. *Arthritis Rheum.* 1981;24:844–9.
49. Vitali C, Bombardieri S, Jonsson R, Moutsopoulos HM, Alexander EL, Carsons SE, et al. Classification criteria for Sjögren's syndrome: a revised version of the European criteria proposed by the American-European Consensus Group. *Ann Rheum Dis.* 2002;61:554–8.
50. Moreland LW, Brick JE, Kovach RE, DiBartolomeo AG, Mullins MC. Acute febrile neutrophilic dermatosis (Sweet's syndrome): a review of the literature with emphasis on musculoskeletal manifestations. *Semin Arthritis Rheum.* 1988;17:143–55.
51. Del Pozo Losada J. Síndrome de Sweet. *Semin Fund Esp Reumatol.* 2008;9:174–83.
52. Lisciandrano D, Ranzi T, Carrassi A, Sardella A, Campanini MC, Velio P, et al. Prevalence of oral lesions in inflammatory bowel disease. *Am J Gastroenterol.* 1996;91:7–10.
53. Galbraith SS, Drolet BA, Kugathasan S, Paller AS, Esterly NB. Asymptomatic inflammatory bowel disease presenting with mucocutaneous findings. *Pediatrics.* 2005;116:e439–44.
54. Firestein GS, Gruber HE, Weisman MH, Zvaifler NJ, Barber J, O'Duffy JD. Mouth and genital ulcers with inflamed cartilage: MAGIC syndrome, Five patients with features of relapsing polychondritis and Behçet's disease. *Am J Med.* 1985;79:65–72.
55. Porter SR, Scully Cbe C. Aphthous ulcers (recurrent). *Clin Evid (Online).* 2007;pii:1303. Available from: <http://clinicalevidence.bmj.com/ceweb/conditions/orh/1303/1303-get.pdf>.
56. Rattan J, Schneider M, Arber N, Gorsky M, Dayan D. Sucralfate suspension as a treatment of recurrent aphthous stomatitis. *J Intern Med.* 1994;236:341–3.
57. Bell J. Amlexanox for the treatment of recurrent aphthous ulcers. *Clin Drug Investing.* 2005;25:555–66.
58. Alidaee MR, Taheri A, Mansoori P, Ghodsi SZ. Silver nitrate cauterization in aphthous stomatitis: a randomized controlled trial. *Br J Dermatol.* 2005;153:521–5.
59. Arikani OK, Birol A, Tunceci F, Erkek E, Koc C. A prospective randomized controlled trial to determine if cryotherapy can reduce the pain of patients with minor form of recurrent aphthous stomatitis. *Oral Surg Oral Med Oral Pathol Oral Radiol Endod.* 2006;101:E1–5.
60. Colvard M, Kuo P. Managing aphthous ulcers: laser treatment applied. *J Am Dent Assoc.* 1991;122:51–3.
61. Brice SL. Clinical evaluation of the use of low-intensity ultrasound in the treatment of recurrent aphthous stomatitis. *Oral Surg Oral Med Oral Pathol Oral Radiol Endod.* 1997;83:14–20.
62. McPhee IT, Circus W, Farmer ED, Harkness RA, Cowley GC. Use of steroids in treatment of aphthous ulcerations. *Br Med J.* 1968;2:147–9.
63. Thornhill MH, Baccaglioni L, Theaker E, Pemberton MN. A randomized, double-blind, placebo-controlled trial of pentoxifylline for the treatment of recurrent aphthous stomatitis. *Arch Dermatol.* 2007;143:463–70.
64. Lehner T, Wilton JMA, Ivanyi L. Double blind crossover trial of levamisole in recurrent aphthous ulceration. *Lancet.* 1976;308:926–9.
65. Lynde CB, Bruce AJ, Rogers III RS. Successful treatment of complex aphthosis with colchicine and dapsone. *Arch Dermatol.* 2009;145:273–6.
66. Jacobson JM, Greenspan JS, Spritzler J, Ketter N, Fahey JL, Jackson JB, et al. Thalidomide for the treatment of oral aphthous ulcers in patients with human immunodeficiency virus infection. *N Engl J Med.* 1997;336:1487–93.
67. Hello M, Barbarot S, Bastuji-Garin S, Revuz J, Chosidow O. Use of thalidomide for severe recurrent aphthous stomatitis: a multicenter cohort analysis. *Medicine (Baltimore).* 2010;89:176–82.
68. O'Neill ID. Off-label use of biologicals in the management of inflammatory oral mucosal disease. *J Oral Pathol Med.* 2008;37:575–81.
69. Arida A, Fragiadaki K, Giavri E, Sfikakis P. Anti-TNF agents for Behçet's disease: analysis of publisher data on 369 patients. *Semin Arthritis Rheum.* 2010 Dec 16 [Epub ahead of print].
70. De Abreu MA, Hirata CH, Pimentel DR, Weckx LL. Treatment of recurrent aphthous stomatitis with clofazimine. *Oral Surg Oral Med Oral Pathol Oral Radiol Endod.* 2009;108:714–21.
71. Altenburg A, Abdel-Naser MB, Seeber H, Abdallah M, Zouboulis CC. Practical aspects of management of recurrent aphthous stomatitis. *J Eur Acad Dermatol Venereol.* 2007;21:1019–26.
72. Millán Parrilla F, Quevedo Estébanez E, Gimeno Carpio E. Tratamiento de la estomatitis aftosa recidivante. *Piel (Barc, Ed Impr).* 2010;25:463–9.