

Clinical rheumatology in images

Muscle metastasis of a coroid melanoma

Metástasis muscular de melanoma coroideo

Rosa Acebal,^a Raquel Almodóvar,^{b,*} Francisco Javier Quirós,^b Ramón Mazzuchelli,^b Pedro Zarco^b

^aMedicina Familiar y Comunitaria, Hospital Universitario Fundación Alcorcón, Madrid, Spain

^bUnidad de Reumatología, Hospital Universitario Fundación Alcorcón, Madrid, Spain

Case report

The patient was a 73-year old woman with a history of choroidal melanoma in the right eye, which was treated in 1999 with brachytherapy. In May 2008 she presented a nodule in the left

forearm of 4 months evolution. Physical examination revealed a painless nodule which seemed to depend on the extensor muscles. Blood count, biochemistry and urinalysis were normal. The ESR was 26 mm (0–20). The Rx of the forearm (Figure 1) showed a dense mass of soft tissue without bone erosion. Ultrasound (Figure 2) revealed a solid, oval tumour with internal blood flow. MRI scans (Figure 3) showed a solid mass, hyperintense on T1 and slightly hyperintense on T2 and somewhat brighter on STIR.

Diagnosis and evolution

A biopsy was performed which showed histopathological muscle metastases. This was surgically resected and did not require adjuvant treatment. At present there has been one subcutaneous preauricular recurrence, bilateral and abdominal, which is being treated with chemotherapy.

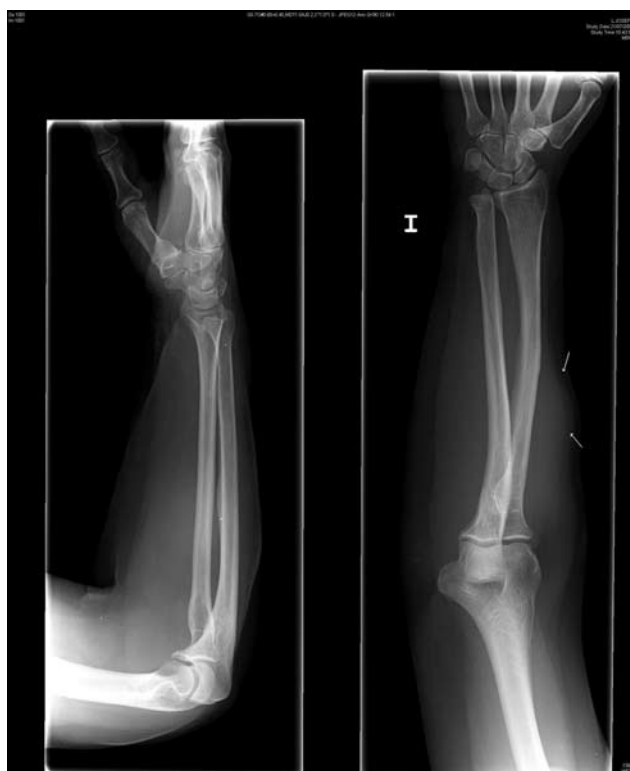

Figure 1. Left forearm Rx: Evidence of a dense mass in soft tissue, without evidence of underlying bone erosion.

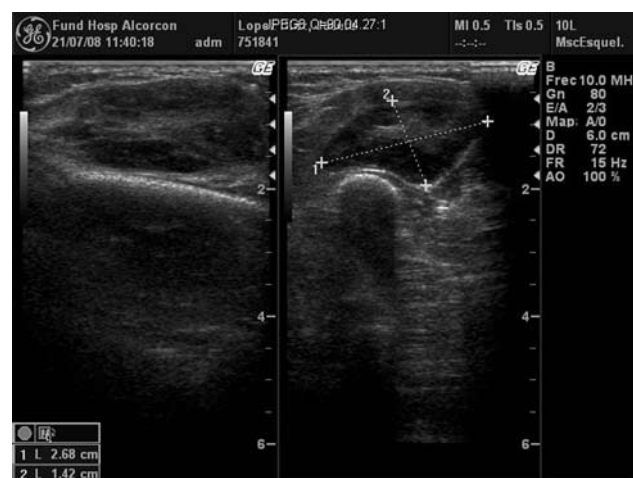


Figure 2. Left forearm ultrasound: There is a solid, oval mass, 36×26×14 mm, well circumscribed, with internal blood flow. The lateral, muscular plane of the left forearm shows a solid, oval mass of 36×26×14 mm, well circumscribed by an echogenic ring, predominantly hypoechoic with respect to the adjacent muscles, with a central hyperechoic area. The Doppler study reveals there is blood flow inside the tumour.

*Corresponding author.

E-mail address: ralmodovar@fhacorcon.es (R. Almodóvar).

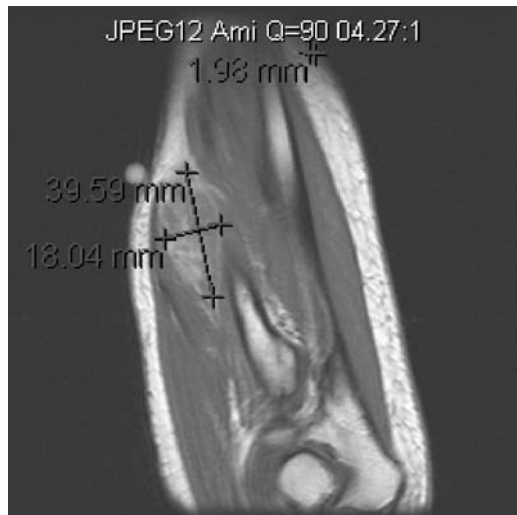


Figure 3. T1 sequence of coronal MRI scan of the left forearm with contrast: There is a solid mass of oval morphology, approximately 39x18 mm, predominantly hyperintense, with irregular enhancement of the mass and an adjacent area of oedema.

Discussion

Choroidal melanoma is the most common ocular malignancy.¹ Its incidence is around 6-7 cases per million inhabitants per year. It is clinically manifested by a detachment or haemorrhage of the retina with visual loss and/or scotomas.³ This type of tumour causes metastases in 35% of cases, despite satisfactory treatment.² They mainly settle in the liver (98%), lung (29%) and bone (17%).⁴ Only 12%

occur in skin and subcutaneous tissue. Mean survival is less than 10% at 2 years from the onset of metastasis.⁴

There are very few reported cases of muscle metastases from malignant melanomas.⁵⁻⁷ The usual clinical manifestation is a painless mass most commonly located in the psoas, iliopsoas, paravertebral and proximal muscles of the limbs.⁸ On MRI scans, the hyperintense T1 signal, due to the paramagnetic effect of melanin, is a hallmark of this entity.⁵ The definitive diagnosis is anatomopathological. From all the above, it follows that the medical history of the patient should always be taken into account, especially in the case of neoplasms.

References

1. Bell DJ, Wilson MW. Choroidal melanoma: natural history and management options. *Cancer Control*. 2004;11:296-303.
2. Servodidio CA, Abramson DH. Presenting signs and symptoms of choroidal melanoma: what do they mean? *Ann Ophthalmol*. 1992;24:190-4.
3. Schuster R, Bechrakis NE, Stroux A, Busse A, Schmittel A, Scheibenbogen C, et al. Circulating tumor cells as prognostic factor for distant metastases and survival in patients with primary uveal melanoma. *Clin Cancer Res*. 2007;13:1171-8.
4. Diener-West M, Reynolds SM, Agugliaro DJ, Caldwell R, Cumming K, Earle JD, et al; Collaborative Ocular Melanoma Study Group. Development of metastatic disease after enrollment in the COMS trials for treatment of choroidal melanoma: Collaborative Ocular Melanoma Study Group Report No. 26. *Arch Ophthalmol*. 2005;123:1639-43.
5. Yoshioka H, Itai Y, Niitsu M, Fujiwara M, Watanabe T, Satomi H, et al. Intramuscular metastasis from malignant melanoma: MR findings. *Skeletal Radiol*. 1999;28:714-6.
6. Falappa P, Pennasilico GM, Arcuri PP, Laschena F, Concolino F. Intramuscular metastases from a melanoma diagnosed by magnetic resonance. A case report. *Radiol Med*. 2000;100:62-4.
7. Viswanathan N, Khanna A. Skeletal muscle metastasis from malignant melanoma. *Br J Plast Surg*. 2005;58:855-8.
8. Damron TA, Heiner J. Distant soft tissue metastases: a series of 30 new patients and 91 cases from the literature. *Ann Surg Oncol*. 2000;7:526-34.