



Case report

Maculopathy in Patient With Systemic Lupus Erythematosus Treated With Hydroxychloroquine[☆]

Francisco Jorge Rodríguez-Hurtado,^{a,*} José Antonio Sáez-Moreno,^{b,c} José Manuel Rodríguez-Ferrer^b

^a Servicio de Oftalmología, Hospital Virgen de las Nieves, Granada, Spain

^b Laboratorio de Neurociencia Visual y Cognitiva, Universidad de Granada, Granada, Spain

^c Servicio de Neurofisiología Clínica, Hospital Universitario San Cecilio, Granada, Spain

ARTICLE INFO

Article history:

Received 9 September 2011

Accepted 8 December 2011

Available online 22 May 2012

Keywords:

Lupus erythematosus

Hydroxychloroquine

Central serous chorioretinopathy

Multifocal electroretinography

ABSTRACT

A 50-year-old woman with systemic lupus erythematosus treated for 13 years with hydroxychloroquine developed nephropathy and high blood pressure 5 years ago as well as moderate loss of vision in her right eye. Fundoscopy showed alterations of macular pigmentation only in the right eye. Visual fields 10-2 were normal in both eyes. Optical coherence tomography showed hyperreflective foveal thickening with a hyporeflective cavity underlying in the right macula, and was normal in left macula. Fluorescein angiography showed no bulls-eye pattern, but did show microaneurysms in vascular arcades. Multifocal central electroretinogram was diminished in right eye and the electroretinogram pattern was diminished in both eyes. We concluded that the alterations of the right eye were suggestive of ischemic maculopathy, not chloroquine toxicity.

© 2011 Elsevier España, S.L. All rights reserved.

Maculopatía en paciente con lupus eritematoso sistémico tratado con hidroxycloquina

RESUMEN

Una mujer de 50 años con lupus eritematoso sistémico, tratada 13 años con hidroxycloquina y desde hace 5 años con nefropatía e hipertensión arterial, refirió en la revisión periódica pérdida moderada de visión en el ojo derecho. La fundoscopia mostró solo alteraciones de la pigmentación macular en el ojo derecho. El campo visual 10-2 fue normal en ambos ojos. La tomografía de coherencia óptica mostró en la mácula derecha un engrosamiento foveal hiperreflectivo, con cavidad hiporeflectiva subyacente, y fue normal en la mácula izquierda. La angiografía fluoresceínica no mostró patrón en ojo de buey, sino microaneurismas en arcadas vasculares. El electroretinograma multifocal central estaba disminuido en el ojo derecho y el electroretinograma patrón moderadamente disminuido en ambos ojos. En conclusión, las alteraciones del ojo derecho fueron indicativas de maculopatía isquémica, pero no de toxicidad cloroquinica.

© 2011 Elsevier España, S.L. Todos los derechos reservados.

Palabras clave:

Lupus eritematoso

Hidroxycloquina

Coriorretinopatía central serosa

Electrorretinografía multifocal

Introduction

Synthetic antimalarials in the treatment of systemic lupus erythematosus (SLE) have been a major therapeutic advance and serve as immunomodulators and inhibitors of thrombosis, with few side effects, prolonging the quality of life of patients. Their withdrawal

leaves the patient with SLE at the mercy of the side effects of corticosteroids and immunosuppressants, and increases the risk of flares.¹

Hydroxychloroquine can cause severe retinal toxicity, requiring discontinuation of therapy, although there are few cases of chloroquine retinopathy, always related to very high cumulative drug dose.²

Synthetic antimalarial toxicity is detected by ophthalmic screening protocols focused on development of macular pathology.³ One must not forget that the patient with SLE is predisposed to retinal ischemia that may be confused with macular damage due to chloroquine. We present a case in which the ocular findings represented a challenge in the therapeutic decision.

[☆] Please cite this article as: Rodríguez-Hurtado FJ, et al. Maculopatía en paciente con lupus eritematoso sistémico tratado con hidroxycloquina. Reumatol Clin. 2012. doi:10.1016/j.reuma.2011.12.012

* Corresponding author.

E-mail address: frhurtado@telefonica.net (F.J. Rodríguez-Hurtado).

Macula Thickness: Macular cube 512x128

OD OS

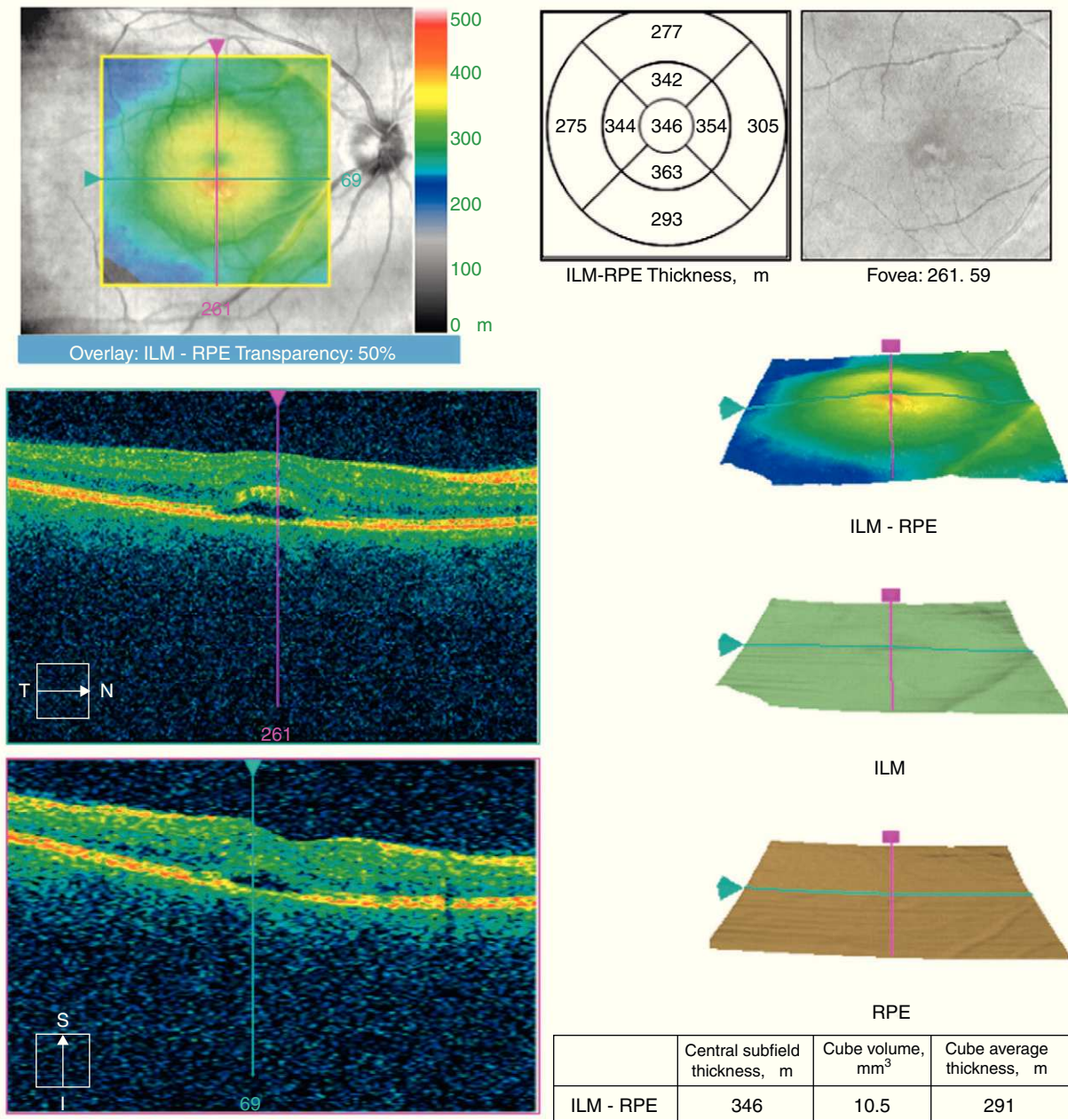


Fig. 1. Optical coherence tomography of the right eye of the patient showing discrete thickening of the fovea, with a hyporeflective space in the outer layers of the retina (arrows).

Case Report

A 50-year-old woman with SLE was treated with a umulative dose of 365 g of hydroxychloroquine for 13 years, with mild lupus nephritis and hypertension controlled 5 years prior; during her screening for ocular toxicity she presented moderate loss of vision, presenting a corrected visual acuity of 0.7 in the right eye and 1 in the left eye. In the right fundus we observed irregular areas of hyperpigmentation and depigmentation in the macula, without apparent serous uprisng, and some arcades microhemorrhages. The left fundus appeared normal. 10-2 the visual field was normal in both eyes. Optical coherence tomography (OCT) of the right eye showed hyperreflective foveal thickening and hyporeflective cavities in deep layers (Fig. 1). The OCT of the left eye was

normal. Fluorescein angiography (FA) showed no bull's-eye pattern, but microaneurysms in both eyes (not detected on funduscopy), sectoral distribution and hyper- and hypofluorescence late macular leakage (Fig. 2). In the multifocal electroretinogram (mfERG) there were low amplitude responses in both peripheral retinas, low power density in the foveal region of the right eye and normal foveolar activity in the left eye (Fig. 3). The alteration of the N95 wave of the electroretinogram pattern reflected a dysfunction of the ganglion cells of both retinas, probably causing the disease.

The neurophysiological findings, the OCT and FA suggested a vascular origin rather than a toxic effect, so it toxicity was ruled out and hydroxychloroquine retinopathy was diagnosed as lupus, recommending the maintenance of the antimalarial but with close monitoring of the patient to prevent maculopathy as a risk factor. In

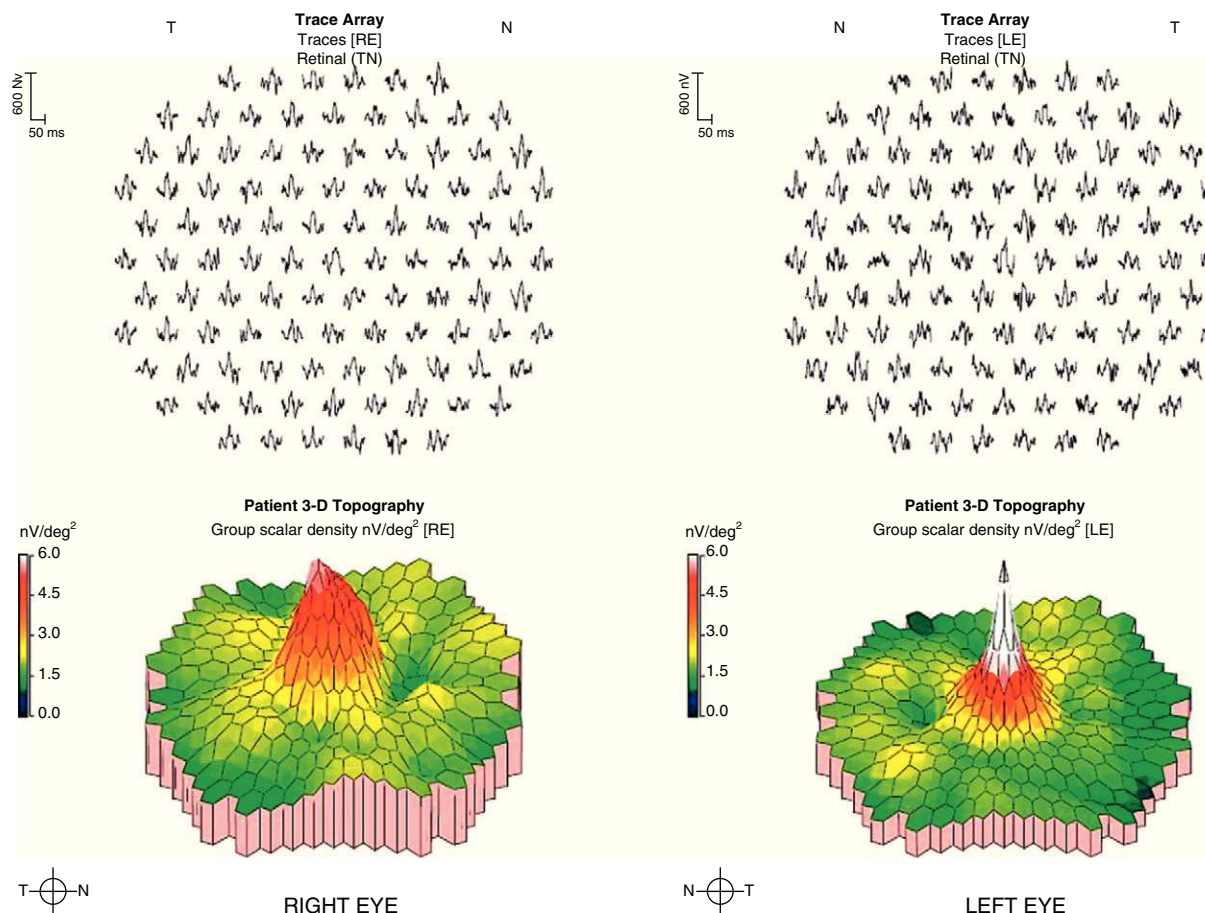


Fig. 2. Central multifocal electroretinogram with 100 hexagons. We observe a moderate decrease in the rpower density of the foveal region of the right eye (no white areas).

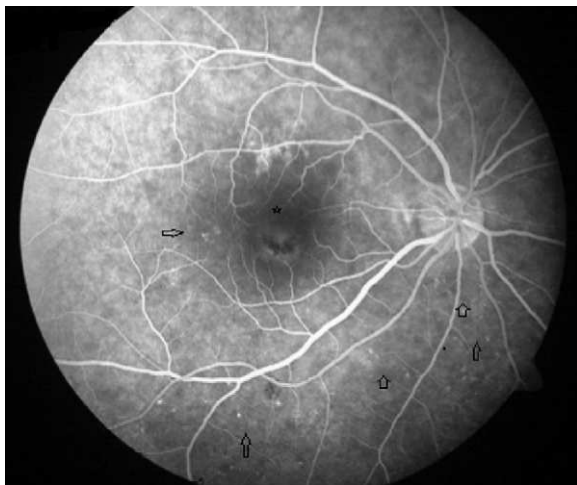


Fig. 3. Angiography of the right eye. Microaneurysms are seen in inferior temporal region and a small temporal macula area (arrows). Hypo- and hyperfluorescent images of the fovea (asterisk) are not modified during the angiogram.

subsequent visits the patient maintained her visual acuity and had improved lupus symptoms with hydroxychloroquine maintenance treatment, which confirmed the suspected end diagnosis.

Discussion

In the early alterations of the visual field as a sign of cloroquine maculopathy 10-2, central mfERG, OCT and autofluorescence

have recently been added as diagnostic tests, with their use recommended for routine screening.³ Central mfERG shows very early alterations,⁴ but its availability is scarce.

The field of view of our patient was normal in both eyes, which ruled cloroquine maculopathy. The mfERG showed macular dysfunction only in the right eye and asymmetry is rare in drug toxicity. The results of the AGF and the rest of neurophysiological studies suggested an episode of retinal ischemia. The OCT image was reminiscent of a rare form of central serous chorioretinopathy, lupus⁵ choroidopathy, while microaneurysms in cuneiform distributions were more typical of hypertensive episodes.

Faced with a maculopathy in a patient with SLE treated with hydroxychloroquine, we must not forget that they are patients exposed to thrombotic events that can generate retinal confusion, so that additional tests may be necessary to make an adequate differential diagnosis, because without maculopathy there is no need for drug withdrawal, even to assess an increase in dosage.

Ethical disclosures

Protection of human and animal subjects. The authors declare that no experiments were performed on humans or animals for this investigation.

Confidentiality of Data. The authors declare that they have followed the protocols of their work centre on the publication of patient data and that all the patients included in the study have received sufficient information and have given their informed consent in writing to participate in that study.

Right to privacy and informed consent. The authors have obtained the informed consent of the patients and /or subjects mentioned in

the article. The author for correspondence is in possession of this document.

Conflict of Interest

The authors have no disclosures to make.

References

1. Tsakonas E, Joseph L, Esdaile JM, Choquette D, Sénécal JL, Cividino A, et al. A long-term study of hydroxychloroquine withdrawal on exacerbations in systemic lupus erythematosus. *The Canadian Hydroxychloroquine Study Group. Lupus.* 1998;7:80–5.
2. Bernstein HN. Ocular safety of hydroxychloroquine. *Annals of Ophthalmology.* 1991;23:292–6.
3. Marmor MF, Kellner U, Lai TY, Lyons JS, Mieler WF, American Academy of Ophthalmology. Revised recommendations on screening for chloroquine and hydroxychloroquine retinopathy. *Ophthalmology.* 2011;118:415–22.
4. Lyons JS, Severns ML. Detection of early hydroxychloroquine retinal toxicity enhanced by ring ratio analysis of multifocal electroretinography. *American Journal of Ophthalmology.* 2007;143:801–9.
5. Cunningham Jr ET, Alfred PR, Irvine AR. Central serous chorioretinopathy in patients with systemic lupus erythematosus. *Ophthalmology.* 1996;103:2081–90.