

5. O'Riordan JL, Gallagher HL, Thompson AJ, Howard RS, Miller DH. Clinical, CSF, and MRI findings in Devic's neuromyelitis optica. *J Neurol Neurosurg Psychiatry.* 1996;60:382–7.
6. Velloso Feijoo ML, García Hernández F, Ocaña Medina C, González León R, Garrido Rasco R, Sánchez Román J. Mielitis transversa en lupus eritematoso sistémico. *Reumatol Clin.* 2007;3:73–7.
7. Bichuetti DB, De Oliveira EML, Oliveira DM, De Souza NA, Gabbai AA. Neuromyelitis optica treatment: analysis of 36 patients. *Arch Neurol.* 2010;67:1131–6.

Iñaki Hernando Rubio,\* Joaquín Belzunegui Otano, Olga Máiz Alonso, Belén Álvarez Rodríguez

*Servicio de Reumatología, Hospital Donostia, San Sebastián, Spain*

\* Corresponding author.

E-mail address: [i.hernando.rubio@gmail.com](mailto:i.hernando.rubio@gmail.com) (I. Hernando Rubio).

## Hyperparathyroidism, A Forgotten Cause of Musculoskeletal Pain<sup>☆</sup>

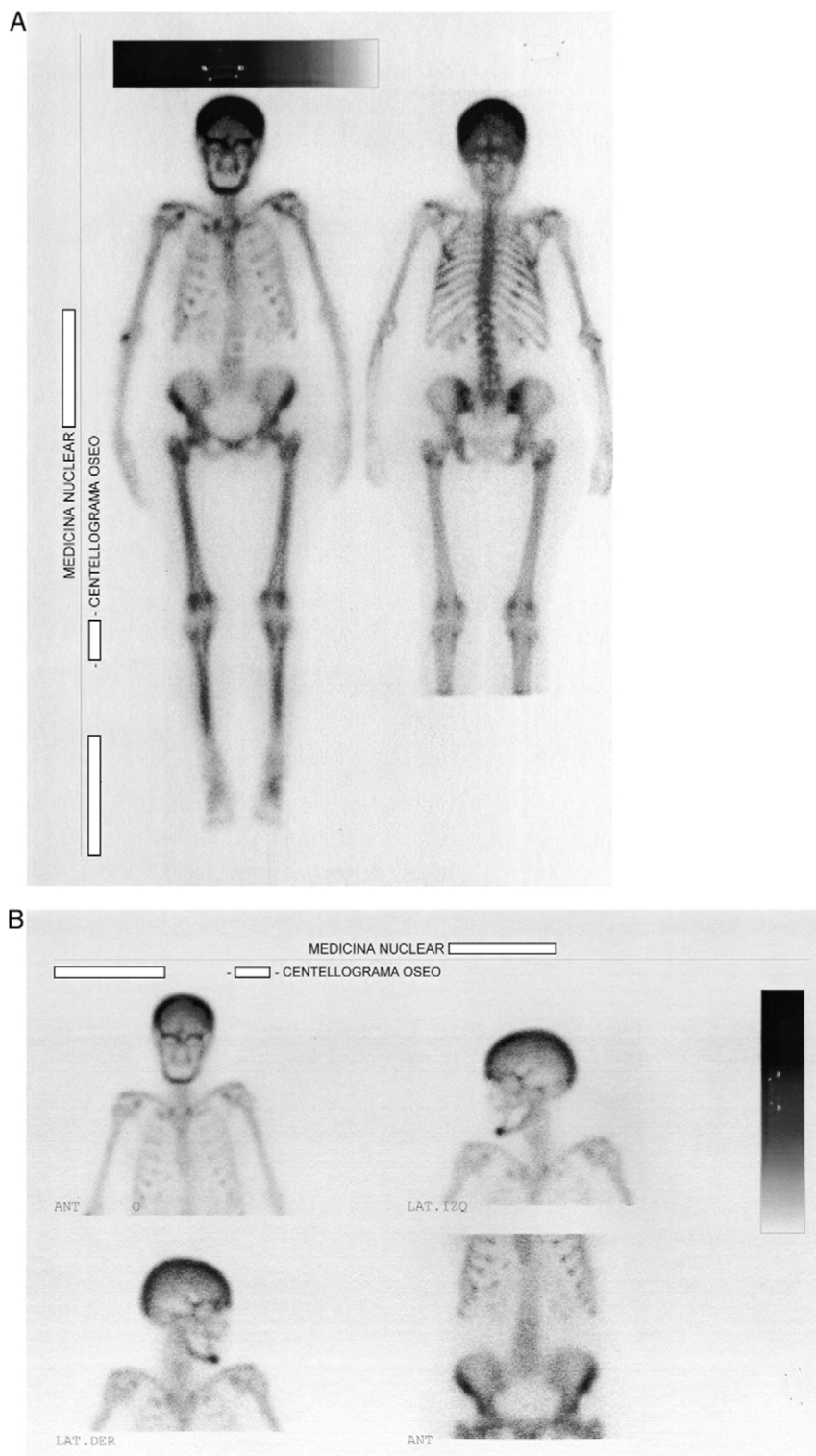
### *Hiperparatiroidismo, una causa olvidada de dolor músculo-esquelético difuso*

To the Editor,

Endocrine disorders often have rheumatic manifestations, which can sometimes be the first characteristic of the disease. Among these disorders is hyperparathyroidism, which is classically manifested by the presence of kidney stones, fractures, pancreatitis and psychiatric disorders.<sup>1</sup> A woman aged 57 was admitted due to widespread pain, sleep disturbances, headache, fatigue and loss of function of upper and lower limbs. Nine months earlier she had been diagnosed with fibromyalgia, having been treated with fluoxetine 20 mg/day and clonazepam 1 mg/day without improvement. Laboratories prior to admission showed an erythrocyte sedimentation rate (ERS) 31 mm/h, hematocrit 35%, hemoglobin 11 mg/dl, CPK 62 U/l (VN to 165), C reactive protein (–). At the time of admission, the physical examination of the patient showed no peripheral arthritis, muscle strength was normal in the neck and pelvic girdle, and she presented positive trigger points for fibromyalgia (18/18). Analysis showed ESR 49 mm/h, serum calcium 13.5 mg/l (VN 8.5–10.5), phosphate 1.9 mg/l (VN 2.4–4.1), alkaline phosphatase 900 U/l (230–460 V). Radiographs showed radiolucent lesions in the clavicle and salt and pepper lesions of the skull. The abdominal ultrasound showed a 6 mm kidney stone at the middle calyx of right kidney. The chest CT observed lytic sack lesions, and a neck tumor formation that could be from the thyroid or parathyroid. The patient underwent a bone scan with <sup>99m</sup>Tc, which showed an increased uptake in the skull, the maxillofacial region, posterior rib areas and long bones of the lower limbs (Fig. 1A and B). The levels of parathyroid hormone (PTH) were 1900 pg/ml (VN

42–72). Diagnosed with primary hyperparathyroidism, she underwent a resection of the tumor, with a pathology report parathyroid follicular adenoma. Musculoskeletal symptoms, as well as fatigue and sleep disorders, showed marked improvement after surgical treatment. Primary hyperparathyroidism is the third most frequent endocrine disorder in women between 50 and 60 years and the most common from is the single adenoma (80%–85%), followed in frequency by 4-gland parathyroid hyperplasia (10%–15%) and to a much lesser degree by parathyroid carcinomas (less than 1%); sometimes, this disorder may be part of a hereditary syndrome such as multiple endocrine neoplasia type 1 or 2.<sup>2,3</sup> Current diagnostic methods rely on elevated serum calcium levels, found in 70%–80% of patients who are asymptomatic at the time of diagnosis and have the disease detected by the incidental presence of hypercalcemia.<sup>1,2</sup> Patients may complain of nonspecific disorders, such as fatigue, depression, weakness, memory loss, sleep disturbances and altered concentration.<sup>4</sup> The presence of arthralgia and myalgia, particularly affecting the proximal muscles of the shoulder and pelvic girdles, mimicking polymyalgia rheumatica, is frequent, and arthritis can also mimic gout or pseudogout.<sup>5,6</sup> Our patient reported sleep disturbances, fatigue, strength loss of arms and legs and generalized musculoskeletal pain; symptoms did not improve with drug therapy. Other clinical manifestations are at the neuromuscular level,<sup>7</sup> paresthesias and cramps. The improvement of symptoms after excision of the adenoma suggests the causal relationship with hyperparathyroidism. Thomas and Podduturu reported a patient with a previous diagnosis of fibromyalgia who received multiple treatments with no improvement, in whom high levels of PTH were found, receiving treatment for hyperparathyroidism, which led to the resolution of pain.<sup>8</sup> In conclusion, we believe that routine determination of serum calcium and phosphorus should be performed in patients with generalized pain syndromes in which fibromyalgia or polymyalgia rheumatica is suspected.

<sup>☆</sup> Please cite this article as: Borgia AR, et al. Hiperparatiroidismo, una causa olvidada de dolor músculo-esquelético difuso. *Reumatol Clin.* 2012. <http://dx.doi.org/10.1016/j.reuma.2012.02.008>.



**Fig. 1.** (A, B) Total body bone scintigraphy with  $^{99m}\text{Tc}$  showing uptake by the skull, the maxillofacial region, the ribs and long bones.

## References

1. Blackburn M, Diamond T. Primary hyperparathyroidism and familial hyperparathyroid syndromes. *Aust Fam Physician*. 2007;36:1029–33.
2. Fraser WD. Hyperparathyroidism. *Lancet*. 2009;374:145–58.
3. Marocci C, Cetani F. Clinical practice. Primary hyperparathyroidism. *N Engl J Med*. 2011;365:2389–97.
4. Felger EA, Kandil E. Primary hyperparathyroidism. *Otolaryngol Clin North Am*. 2010;43:417–32.
5. Helliwell M. Rheumatic symptoms in primary hyperparathyroidism. *Postgrad Med J*. 1983;59:236–40.
6. Rubin MR, Silverberg SJ. Rheumatic manifestations of primary hyperparathyroidism and parathyroid hormone therapy. *Curr Rheumatol Rep*. 2002;4:179–85.

7. Turken SA, Cafferty M, Silverberg SJ, De La Cruz L, Cimino C, Lange DJ, et al. Neuro-muscular involvement in mild, asymptomatic primary hyperparathyroidism. *Am J Med.* 1989;**87**:553–7.
8. Thomas M, Podduturu VR. Hyperparathyroidism causing muscle pain: a frequently forgotten diagnosis —a case report. Poster 111 [abstract]. *Arch Phys Med Rehabil.* 2005;**86**:e25.

Ariel R. Borgia,\* Javier A. Cavallasca,  
Cecilia A. Costa, Jorge L. Musuruana

*Sección Reumatología y Enfermedades Autoinmunes Sistémicas,  
Hospital J.B. Iturraspe, Santa Fe, Argentina*

\* Corresponding author.

*E-mail address:* [reumatologia.iturraspe@gmail.com](mailto:reumatologia.iturraspe@gmail.com)

(A.R. Borgia).