

## Letters to the Editor

### Mesenteric Panniculitis in a Patient With Ankylosing Spondylitis<sup>☆</sup>

#### *Paniculitis mesentérica en un paciente con espondilitis anquilosante*

Dear Editor,

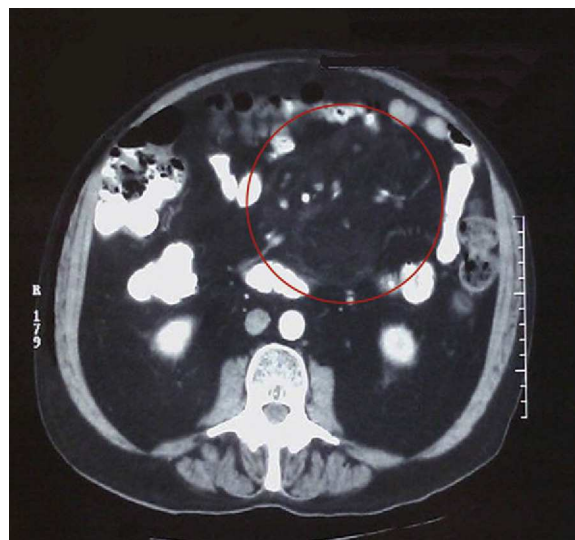
Mesenteric panniculitis is an inflammatory, chronic, and idiopathic disease that mainly affects the adipose tissue of the mesentery of the small intestine. It is considered as the inflammatory stage of a sclerosing mesenteritis, which can evolve into a third stage called retractable mesenteritis where fibrosis predominates.<sup>1</sup> Two cases have been described where mesenteric panniculitis extends into the retroperitoneum and evolves into retroperitoneal fibrosis.<sup>2</sup>

Retroperitoneal fibrosis is a histologically benign entity. Most cases are idiopathic, but they have been associated with malignancies, drugs, prior surgery and infections as well as autoimmune diseases such as ankylosing spondylitis, and are considered by some as a manifestation of extra-articular disease.<sup>3</sup>

We report the case of a 65-year-old man with ankylosing spondylitis of 17 years of evolution and repeat bilateral uveitis. His spondylitis had a progressive course, which was not being controlled with anti-inflammatory drugs, so we decided to start treatment with etanercept, which was not effective. In the last eight months he presented gradual diarrhea and abdominal pain, so his case was studied by the Department of Gastroenterology, who performed a colonoscopy discarding inflammatory bowel disease. One day before admission to the General Surgery department he presented acute abdominal pain and bilious vomiting. On examination, the abdomen was distended without signs of peritoneal irritation. He had leukocytosis with elevated acute phase reactants and X-rays showed dilation of the small bowel. We proceeded to perform abdominal CT (Fig. 1) observing the “fat ring sign” characteristic of mesenteric panniculitis, which consists of the observation of surrounding heterogeneous mesenteric masses<sup>4</sup> displacing the bowel. Faced with an episode of intestinal obstruction, fluid therapy was instituted with bowel rest, with resolution of the problem. He was subsequently followed as an outpatient; we repeated the Mantoux and Quantiferon<sup>®</sup> tests, which were negative. A year later, he remains gastrointestinally asymptomatic.

In the literature review we found only one other published case of an association between ankylosing spondylitis and mesenteric panniculitis, which was initially misdiagnosed as Crohn’s disease.

In this case the diagnosis was made through imaging, which was highly suggestive of this entity, consistent with the patient’s progress. For this reason, there was no histologic confirmation.



**Fig. 1.** CT scan of the abdomen and pelvis: marked thickening of mesenteric fat and displacement of the small intestine.

Other possibilities that should be suspected are lymphoma, liposarcoma, peritoneal carcinomatosis, carcinoid tumor, lipoma, mesenteric desmoid tumor, an IgG4 related disease, Whipple’s disease or peritoneal tuberculosis. Given the evolution of mesenteric panniculitis to retroperitoneal fibrosis,<sup>5</sup> it is possible that the association between the latter and spondylitis has mesenteric panniculitis as an intermediate link between the two. The study of new cases of an association between these entities could bring more light on this etiopathogenic possibility.

### References

1. Coulier B. Mesenteric panniculitis. *JRB-BTR*. 2001;94:229–40.
2. Brown WR, McIntyre WW, McNally PR. Sclerosing mesenteritis: a report of two cases with dramatic response to immunosuppressive agents. *VHJE*. 2003;2:2.
3. Kermani TA, Cowson CS, Achenbach SJ. Idiopathic retroperitoneal fibrosis. A retrospective review of clinical presentation, treatment and outcomes. *Mayo Clin Proc*. 2011;86:297–303.
4. Canyigit M, Koksak A, Akgoz A, Kara T, Sarishini M, Akhan O. Multidetector-row computed tomography findings of sclerosing mesenteritis with associated diseases an its prevalence. *Jpn J Radiol*. 2011;29:495–502.
5. Afeltra A, Vespasiani Genilucci UD, Rabitti C. Retroperitoneal fibrosis and ankylosing spondylitis: which links? *Semin Arthritis Rheum*. 2005;35:43–8.

Patricia Tejón Menéndez,<sup>\*</sup> Sara Alonso, Mercedes Alperi, Javier Ballina

Servicio de Reumatología, Hospital Universitario Central de Asturias, Oviedo, Spain

<sup>\*</sup> Corresponding author.

E-mail address: [patriciatejon@gmail.com](mailto:patriciatejon@gmail.com) (P. Tejón Menéndez).

<sup>☆</sup> Please cite this article as: Tejón Menéndez P, et al. Paniculitis mesentérica en un paciente con espondilitis anquilosante. *Reumatol Clin*. 2013;9:197–8.