

## Case Report

### Osteomalacia Induced by Adefovir in Patient With Hepatitis B<sup>☆</sup>

Mayra Nathali Rivas Zavaleta,\* Sonia Guayambuco Romero, Marcelo Calabozo Raluy, Fernando Pérez Ruiz

Servicio de Reumatología, Hospital Cruces, Barakaldo, Vizcaya, Spain

#### ARTICLE INFO

##### Article history:

Received 22 June 2012

Accepted 10 January 2013

Available online 20 September 2013

##### Keywords:

Osteomalacia

Adefovir

Hypophosphatemia

#### ABSTRACT

Osteomalacia is defined as a defect in mineralization of the bone matrix. We describe the case of a patient with chronic hepatitis B infection in whom treatment with adefovir induced renal phosphate loss with intense and sustained hypophosphatemia which derived in symptomatic osteomalacia.

© 2012 Elsevier España, S.L. All rights reserved.

#### Osteomalacia inducida por adefovir en paciente con hepatitis B

#### RESUMEN

La osteomalacia se define como un defecto en la mineralización de la matriz ósea. Describimos el caso de un paciente con infección crónica por virus de la hepatitis B en el que el tratamiento con adefovir indujo una pérdida renal de fosfato con hipofosfatemia intensa y mantenida que derivó en osteomalacia sintomática.

© 2012 Elsevier España, S.L. Todos los derechos reservados.

##### Palabras clave:

Osteomalacia

Adefovir

Hipofosfatemia

## Introduction

Adefovir is an antiretroviral drug used for the treatment of patients with chronic infection with hepatitis B. Among its adverse effects one finds nephrotoxicity, although this usually occurs when high doses (60–120 mg/day) are employed.<sup>1</sup> The currently recommended dose is approximately 10 mg/day PO, which minimizes the risk of nephrotoxicity in patients without a history of renal disease.<sup>2–4</sup> The case presented is that of a patient treated with adefovir at a dose of 10 mg/day which caused abnormalities in the proximal renal tubule, leading to<sup>5,6</sup> hypophosphatemic osteomalacia.

## Case Presentation

The patient was an 81 year old male with a single kidney, with chronic hepatitis B treated with adefovir for four years

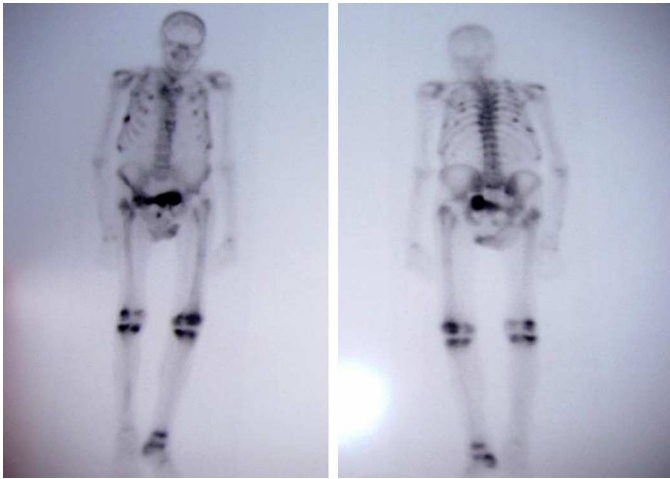
approximately at a dose of 10 mg/day. The patient had poor overall condition, fatigue, weakness, bone pain, muscle atrophy and weight loss which had lasted for a year. He had elevated alkaline phosphatase (386 U/l; normal <140 U/l) and a bone scan showed multiple pathological uptake areas (Fig. 1). With the presumptive diagnosis of Paget's disease, treatment was begun with bisphosphonates (etidronate 30 mg/day for 2 months), calcium and vitamin D, with no clinical improvement, so the patient was referred to the Rheumatology department. Laboratory results showed elevated alkaline phosphatase (329 U/L), hypoproteinemia (5.5 g/dl), hypoalbuminemia (3.3 g/dl), hypouricemia (1.5 mg/dl) with a fractional excretion of urate of 50% and hypophosphatemia (1.2 mg/dl) with tubular reabsorption of phosphate 9% (normal >80%). PTH levels were normal as was 25-hydroxycholecalciferol. Regarding renal function, creatinine was 1.13 mg/dl and the estimated glomerular filtration rate was 53 ml/min. The patient had proteinuria (1178 mg/day) and glucosuria (>100 mg/day). A chest X-ray showed rib fractures on both sides and bone scintigraphy showed multiple foci of uptake in the ribs, right sacrum, knees and right tibia.

A historical review of the analysis showed that the onset of disturbances, in particular decreasing phosphate levels, coincided with the beginning of the administration of adefovir (4 years

<sup>☆</sup> Please cite this article as: Rivas Zavaleta MN, et al. Osteomalacia inducida por adefovir en paciente con hepatitis B. Reumatol Clin. 2014;10:120–121.

\* Corresponding author.

E-mail address: [nathali.r17@hotmail.com](mailto:nathali.r17@hotmail.com) (M.N. Rivas Zavaleta).



**Fig. 1.** Bone scan with multiple foci of increased uptake on both sides of the thorax, right sacroiliac joint, pubis, both knees and right ankle.

prior). Adefovir was discontinued and the patient was treated with intravenous phosphate, presenting an increase in phosphate values to 4.1 mg/dl. He was discharged with oral phosphate at a dose of 7 g/day. In the next 6 months, there was a clear, albeit slow, clinical improvement.

## Discussion

In the case presented, laboratory abnormalities coincided with the start of the administration of adefovir and were associated with an improvement in phosphate values after drug withdrawal. Adefovir is associated with nephrotoxic effects, which are dose-dependent, leading to dysfunction of the proximal renal tubule and glomerular filtration rate.<sup>7</sup> The lowering effect of the plasma phosphate levels of adefovir has been observed in 22%–50% of patients treated with doses of 30 mg/day for at least 6 months and manifests itself as a progressive increase in serum creatinine, hypophosphatemia or both.<sup>8</sup> While use of 10 mg/day orally is not associated with significant renal dysfunction, in this case a low dose caused a decrease in tubular phosphate reabsorption and resulted in hypophosphatemia, leading to clinically manifested osteomalacia and bone pain, functional impairment and generalized muscle pain.<sup>5</sup>

Predisposing factors were the presence of a single kidney, and a moderately low glomerular filtration rate which contributed to a greater impact of the drug on renal function, as seen in previous cases.<sup>9</sup>

The pathophysiology of renal proximal tubule dysfunction caused by adefovir is due to its concentration in the mitochondria, resulting in mitochondrial toxicity and inhibition of ATP-dependent transporters in proximal tubule cells, leading to altered

phosphate reabsorption, decreasing its concentration in plasma and ultimately leading to<sup>10,11</sup> osteomalacia.

In conclusion, although low doses of adefovir are not usually associated with renal toxicity and hypophosphatemia due to renal phosphate loss, the comorbid conditions present in this case led to a situation of increased susceptibility.

## Ethical Responsibilities

**Protection of people and animals.** The authors state that no experiments were performed on humans or animals.

**Data confidentiality.** The authors declare that they have followed the protocols of their workplace regarding the publication of data from patients and all patients included in the study have received sufficient information and gave their written informed consent to participate in this study.

**Right to privacy and informed consent.** The authors state that no patient data appears in this article.

## Conflict of Interest

The authors have no conflict of interest to declare.

## References

1. Servais A, Lechat P, Zahr N, Urien S, Aymard G, Jaudon MC, et al. Tubular transporters and clearance of adefovir. *Eur J Pharmacol.* 2006;540:168–74.
2. Marcellin P, Chang TT, Lim SG, Sievert W, Tong M, Arterburn S, et al. Long-term efficacy and safety of adefovir dipivoxil for the treatment of hepatitis B e antigen-positive chronic hepatitis B. *Hepatology.* 2008;48:750.
3. Fabbriani G, de Socio GV, Massarotti M, Ceriani R, Marasini B. Adefovir induced hypophosphatemic osteomalacia. *Scand J Infect Dis.* 2011;43:990–2.
4. Jung YK, Yeon JE, Choi JH, Kim CH, Jung ES, Kim JH, et al. Fanconi's syndrome associated with prolonged adefovir dipivoxil therapy in a hepatitis B virus patient. *Gut Liver.* 2010;4:389–93.
5. Peris P. Diagnóstico y tratamiento de la osteomalacia por el reumatólogo. *Reumatol Clin.* 2011;7 Suppl. 2:S22–7.
6. Bhan A, Rao AD, Rao DS. Osteomalacia as a result of vitamin D deficiency. *Endocrinol Metab Clin North Am.* 2010;39:321.
7. Verhelst D, Monge M, Meynard JL, Fouqueray B, Mougnot B, Girard PM, et al. Fanconi syndrome and renal failure induced by tenofovir: a first case report. *Am J Kidney Dis.* 2002;40:1331–3.
8. Kahn J, Lagakos S, Wulfsohn M, Cherng D, Millar M, Cherrington J, et al. Efficacy and safety of adefovir dipivoxil for the treatment of hepatitis B with antiretroviral therapy: randomized control trial. *JAMA.* 1999;282:2305–12.
9. Izzedine H, Hulot JS, Launay-Vaucher V, Marcellini P, Hadziyannis SJ, Currie G, et al. Adefovir Dipivoxil International 437 Study Group; Adefovir Dipivoxil International 438 Study Group. Renal safety of adefovir dipivoxil in patients with chronic hepatitis B: two double-blind, randomized, placebo-controlled studies. *Kidney Int.* 2004;66:1153–8.
10. Murer H. Homer Smith Award. Cellular mechanisms in proximal tubular Pi reabsorption: some answers and more questions. *J Am Soc Nephrol.* 1992;2:1649.
11. Minemura M, Tokimitsu Y, Tajiri K, Nakayama Y, Kawai K, Kudo H, et al. Development of osteomalacia in a post-liver transplant patient receiving adefovir dipivoxil. *World J Hepatol.* 2010;2:442–6.