

## Absence of Radiographic Progression at Two Years in a Cohort of Patients With Non-radiographic Axial Spondyloarthritis Treated With TNF- $\alpha$ Blockers<sup>☆</sup>

### *Ausencia de progresión radiológica a los 2 años en una cohorte de pacientes con espondiloartritis axial no radiológica tratados con terapia anti-TNF- $\alpha$*

To the Editor,

It has been shown that no anti-TNF biologic drug inhibits or retards radiographic progression at 2 years in patients with ankylosing spondylitis (who met the New York criteria) when compared with historical cohorts such as OASIS.<sup>1–3</sup> There are no published studies evaluating the effect of biologic therapy on structural progression in patients with non-radiographic axial spondyloarthritis. In studies evaluating radiological progression, patients do not receive anti-TNF- $\alpha$  or do it in a very small percentage. In 2 recent GESPIC cohort studies that assess the progression in the spine and sacroiliac joints of 95 patients with non-radiographic axial spondyloarthritis, only one patient received biological therapy. In these studies, 10.5% of patients showed progression of sacroiliitis and 7.4%, had spinal progression at 2 years follow-up.<sup>4,5</sup>

The aim of this study was to evaluate the radiological progression in spine and sacroiliac joints at 2 years in a cohort of patients with non radiographic axial spondyloarthritis treated with anti-TNF- $\alpha$ .

After a systematic review of medical records, we selected all patients with non radiological axial spondyloarthritis in our service and biological treatment with anti-TNF drugs at a standard dose for a minimum of two years and who had a baseline simple X-ray of the spine (cervical and lumbar lateral projection) and pelvis (anteroposterior view), and a follow-up X-ray 2 years later under the same treatment.

All selected patients, 19, fulfilled the ASAS classification criteria for axial spondyloarthritis,<sup>6</sup> but did not meet the New York radiological criteria for ankylosing spondylitis<sup>7</sup> (bilateral sacroiliitis at least grade 2 or unilateral grade 3–4). The 19 patients met the 2 entrace criteria (back pain  $\geq$  three months and age of onset <45 years), 13 (65%) met the HLAB27 criteria and 6 (35%) the imaging, and thus, had acute inflammation on MRI, indicating sacroiliitis.

We excluded patients with cutaneous psoriasis and inflammatory bowel disease.

Twelve patients received adalimumab, 2 infliximab, and 5 etanercept. Only 2 patients (10.5%) received concomitant therapy with NSAIDs for 3 or more months.

The baseline characteristics of the patients are shown in Table 1. Two trained readers, JL and MA, examined the spinal radiographs according to the Stoke Ankylosing Spondylitis Spine Score (mSASSS)<sup>8</sup> and the sacroiliac joint x rays according to the grading system of the modified New York criteria for ankylosing spondylitis<sup>7</sup> in chronological order (baseline and follow-up at 2 years with the same biological treatment).

The intraclass correlation coefficients (ICC) for baseline rates were 1 in mSASSS and 0.4 index in grading the sacroiliac index and the ICC for the change rates were 1 in both reading systems.

The mSASSS index was zero units at baseline and at 2 years of treatment in all patients (none developed structural lesions in the spine).

**Table 1**

Baseline Characteristics of Patients With Non-Radiographic Axial Spondyloarthritis.

Parameters	Patients with non-radiographic axial spondyloarthritis (n=19)
Age, mean $\pm$ SD (years)	32.9 $\pm$ 7.17
Duration of symptoms, mean $\pm$ SD (years)	5.89 $\pm$ 5.11
Male gender, n (%)	10 (52.6%)
HLAB27+, n (%)	15 (78.9%)
Smokers, n (%)	7 (36.8%)
Peripheral arthritis, n (%)	16 (84.2%)
Enthesitis, n (%)	7 (36.8%)
Dactylitis, n (%)	1 (5.2%)
Uveitis, n (%)	5 (26.3%)
Family history of spondylitis, n (%)	7 (36.8%)
BASDAI>4, n (%)	19 (100%)
PCR>0.6 mg/dl, n (%)	9 (47.4%)
ESR>20 mm/h, n (%)	8 (42.1%)
Structural damage defined in sacroiliac joints (grade I unilateral or bilateral sacroiliitis and/or unilateral grade II), n (%)	9 (47.4%)
Defined spinal structural damage (mSASSS $\geq$ 1), n (%)	0 (0%)

There was no sacroiliac radiological progression in any patient. None of the 19 patients in the cohort met the New York criteria for ankylosing spondylitis after 2 years of biological therapy with anti-TNF- $\alpha$ .

In conclusion, none of the patients in our cohort with non radiographic axial spondyloarthritis showed radiographic progression in the spine or sacroiliac joints after 2 years of treatment with anti-TNF, unlike other non-radiological spondylitis cohorts without biological therapy.

In the first GESPIC cohort study, assessing sacroiliac radiographic progression at 2 years, the only predictor of radiographic progression were baseline CRP levels.<sup>4</sup> In our cohort, 47.4% of patients had CRP levels greater than 0.6 mg/dl. In this study by Poddubnyy et al.,<sup>4</sup> the high level of CRP was also a significant predictor of progression of non-radiological spondylitis to ankylosing spondylitis and the presence of structural damage defined at baseline was also associated with greater progression to ankylosing spondylitis, although not statistically significant. In another study, Huerta-Sil et al.,<sup>9</sup> also found that low-grade sacroiliitis was a prognostic factor for the development of spondylitis. In our cohort, 47.4% of patients had low-grade structural damage (grade I unilateral or bilateral sacroiliitis and/or unilateral grade II).

In the second GESPIC<sup>5</sup> cohort study evaluating spinal radiographic progression at 2 years, only the presence of basal syndesmophytes was a statistically significant predictor of progression in the non radiological spondylitis group, although there were radiological progression in patients with no baseline syndesmophytes (the vast majority).

In our cohort of patients, although they presented no baseline syndesmophytes, the fact that they showed no radiographic spinal or sacroiliac progression indicates that anti-TNF therapy may inhibit or delay progression in patients with axial non-radiological ankylosing spondylitis, although further studies are necessary with control groups and more patients. This data indicates the existence of a window of opportunity in which an effective treatment may alter the course of disease.

## References

1. Van der Heijde D, Landewé R, Baraliakos X, Houben H, van Tubergen A, Williamson P, et al. Radiographic findings following two years of infliximab therapy in patients with ankylosing spondylitis. *Arthritis Rheum.* 2008;**58**:3063–70.

<sup>☆</sup> Please cite this article as: Almirall M, López-Velandia JG, Maymó J. Ausencia de progresión radiológica a los 2 años en una cohorte de pacientes con espondiloartritis axial no radiológica tratados con terapia anti-TNF- $\alpha$ . *Reumatol Clin.* 2014;**10**:134–135.

2. Van der Heijde D, Landewé R, Einstein S, Ory P, Vosse D, Ni L, et al. Radiographic progression of ankylosing spondylitis after up to two years of treatment with etanercept. *Arthritis Rheum*. 2008;58:1324–31.
3. Van der Heijde D, Salonen D, Weissman BN, Landewé R, Maksymowych WP, Kupper H, et al. Assessment of radiographic progression in the spines of patients with ankylosing spondylitis treated with adalimumab for up to 2 years. *Arthritis Res Ther*. 2009;11:R127.
4. Poddubnyy D, Rudwaleit M, Haibel H, Listing J, Märker-Hermann E, Zeidler H, et al. Rates and predictors of radiographic sacroiliitis progression over 2 years in patients with axial spondyloarthritis. *Ann Rheum Dis*. 2011;70:1369–74.
5. Poddubnyy D, Haibel H, Listing J, Märker-Hermann E, Zeidler H, Braun J, et al. Baseline radiographic damage, elevated acute-phase reactant levels, and cigarette smoking status predict spinal radiographic progression in early axial spondyloarthritis. *Arthritis Rheum*. 2012;64:1388–98.
6. Rudwaleit M, van der Heijde D, Landewé R, Listing J, Akkoc N, Brandt J, et al. The development of Assessment of Spondyloarthritis International Society classification criteria for axial spondyloarthritis (part II): validation and final selection. *Ann Rheum Dis*. 2009;68:777–83.
7. Van der Linden S, Valkenburg HA, Cats A. Evaluation of diagnostic criteria for ankylosing spondylitis. A proposal for modification of the New York criteria. *Arthritis Rheum*. 1984;27:361–4.
8. Wanders AJ, Landewé RB, Spoorenberg A, Dougados M, van der Linden S, Mielants H, et al. What is the most appropriate radiologic scoring method for ankylosing spondylitis? A comparison of the available methods based on the Outcome Measures in Rheumatology Clinical Trials filter. *Arthritis Rheum*. 2004;50:2622–32.
9. Huerta-Sil G, Casasola-Vargas JC, Londoño JD, Rivas-Ruiz R, Chávez J, Pacheco-Tena C, et al. Low grade radiographic sacroiliitis as prognostic factor in patients with undifferentiated spondyloarthritis fulfilling diagnostic criteria for ankylosing spondylitis throughout follow up. *Ann Rheum Dis*. 2006;65:642–6.

Miriam Almirall,\* Josue Guillermo López-Velandia, Joan Maymó

Servicio de Reumatología, Parc de Salut Mar, Barcelona, Spain

\* Corresponding author.

E-mail address: [reu0802@parcdesalutmar.cat](mailto:reu0802@parcdesalutmar.cat) (M. Almirall).

19 March 2013 24 April 2013

### Humeral Artery Thrombosis Simulating an Elbow Monoarthritis in a Woman With Primary Antiphospholipid Syndrome (Hughes Syndrome)<sup>☆</sup>

#### *Trombosis de la arteria humeral simulando una monoartritis de codo en una paciente con síndrome antifosfolipídico primario (síndrome de Hughes)*

Dear Editor:

Antiphospholipid syndrome is defined as a hypercoagulability state with episodic arterial or venous thrombosis and recurrent fetal loss in the presence of antiphospholipid antibodies.<sup>1,2</sup> Arterial thrombosis is less common than venous thrombosis and peripheral arteries are only affected in 25% of events.<sup>3</sup> Among the peripheral arterial thrombosis, upper limbs are only affected in 2.7% of cases.<sup>4</sup>

We present the case of a patient with left humeral artery thrombosis and antiphospholipid syndrome, who presented with atypical symptoms. The patient, a 66-year-old woman with a history of smoking (30 packs/year) and with mild hypertriglyceridemia, came to the clinic due to urgent pain, swelling and functional impairment of the left elbow which began acutely seven days prior, associated with a decrease in the hand on the same side, with no fever or other clinical manifestations. Upon examination we found a swollen and functionally limited elbow (flexion 40°) with erythema and increased local temperature. The fingers felt cold and there was a reduction in the radial pulse compared to the contralateral side, but with good capillary flow. Laboratory analysis showed: CRP 115 mg/dl; D dimer 469 ng/ml; fibrinogen 550 mg/dl; leucocytes  $13.4 \times 10^9/l$  ( $10.8 \times 10^9/l$ ). An echographic study was performed ruling out joint affection but showing the existence of a hypoechoic, heterogeneous thickening of the extensor-supinator muscles (Fig. 1). A Doppler study showed an occlusion of the humeral artery at the elbow flexure. Vascular surgeons, who began treatment with cilostazole, low molecular weight heparin and aspirin, confirmed these findings. When searching for the underlying cause we found the presence of posi-

tive lupus anticoagulant in two separate determinations 3 months apart, with negative anticardiolipin and anti-b2-glycoprotein 1 antibodies. With the diagnosis of thrombosis of the humeral artery in the context of antiphospholipid syndrome we recommended oral anticoagulation with acenocoumarin, with a good progression.

Acute arterial thrombosis is the sudden interruption of blood supply due to the obstruction of the artery that irrigates a specific territory, due to prior stenosis or the existence of an aneurysm at that level, generally having a precipitating factor (hypercoagulability, low cardiac output, etc.). It is clinically manifested as intense pain, pallor, coldness and loss of distal strength, with abolished distal pulse. In our patient, in addition to the poor frequency with which humeral artery occurs, most of the typical signs of acute arterial thrombosis were absent and rather simulated an acute elbow arthritis. When reviewing the literature we have only found descriptions of pain and impairment of the elbow when humeral artery thrombosis is associated to suprachondileal fractures,<sup>5,6</sup> as opposed to our case.

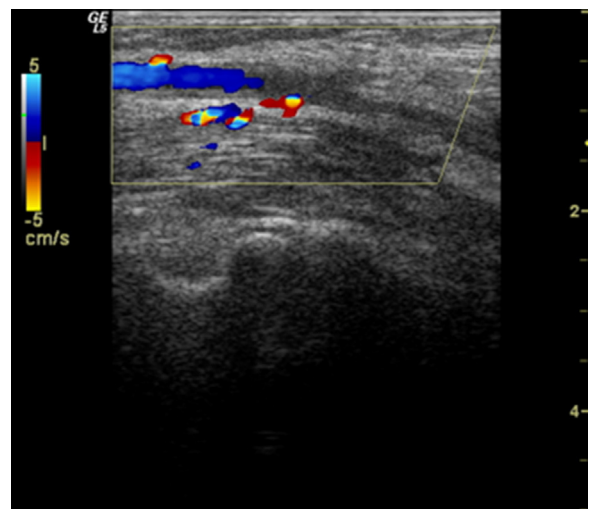


Fig. 1. Image of humeral artery thrombosis.

<sup>☆</sup> Please cite this article as: Feced Olmos CM, Alegre Sancho JJ, Ivorra Cortés J, Zaragoza García JM. Trombosis de la arteria humeral simulando una monoartritis de codo en una paciente con síndrome antifosfolipídico primario (síndrome de Hughes). *Reumatol Clin*. 2014;10:135–136.