

Images in Clinical Rheumatology

Reactive Periostitis of the Hand[☆]

Periostitis reactiva de la mano

María Ángeles Blázquez Cañamero,* Walter Alberto Sifuentes Giraldo, Javier Bachiller Corral

Servicio de Reumatología, Hospital Universitario Ramón y Cajal, Madrid, Spain

ARTICLE INFO

Article history:

Received 8 April 2013

Accepted 29 May 2013

Available online 17 January 2014

The patient is a 29-year-old woman, who complains of swelling and pain in the fifth finger of the left hand lasting for 3 months. She had no medical history and no previous trauma of the referred finger. On examination, she presented a tumor of 1.5 cm × 0.5 cm on the tip of the finger and the subungual region, of indurated consistency which adhered to deep planes, with mild erythema and tenderness. Radiological studies showed a well-circumscribed, nodular ossified lesion with irregular borders, adhered to the 1 periosteum of the distal phalanx, without erosion of the cortex (Fig. 1). Laboratory studies, including biochemistry, hematology and acute phase reactants were all normal. Excision of the lesion was performed and the histopathological study revealed fibrous tissue and fibroblasts with prominent nuclei without atypia in its periphery, and immature osteoid deposits surrounded by an osteoblastic rim in the central area (Fig. 2). These findings were consistent with the diagnosis of florid reactive periostitis of the hand (FRPH). There was no recurrence of the lesion.

FRPH is a rare benign entity characterized by a lush production of osteoblastic proliferative fibrous stroma in the periosteum of the fingers.¹ Its pathogenesis is unknown but is considered to correspond more to a reactive process than to a neoplasm, with a history of trauma being present in up to 50% of cases.² Although it was described in 1933³ there still is confusion in the literature caused by different denominations, including *paraostal fasciitis*, *ossifying fasciitis*, *fibro-osseous pseudotumor*, *pseudomalignant bone tumor of the soft tissue of the fingers* and *nodular fasciitis*, with FRPH being the accepted term.^{2,4} It is most frequently located in the proximal phalanx, followed by the middle phalanx, metacarpal joints and distal phalanx; it is rare in the first two fingers. It usually occurs in women during the second and third decades of life, and is clinically

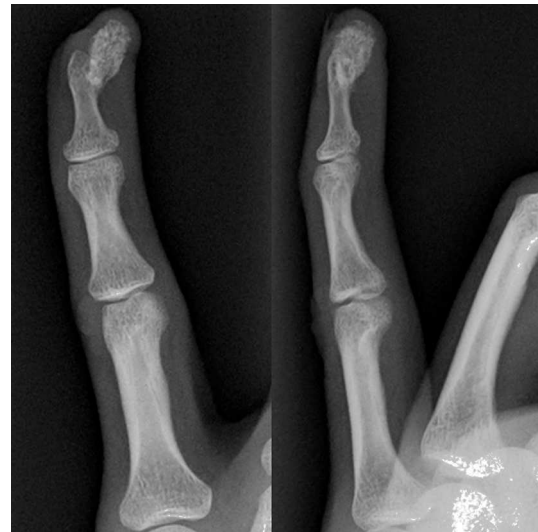

Fig. 1. Anteroposterior (A) and lateral (B) X-rays of the fifth finger of the left hand showing an ossified nodular lesion attached to the periosteum of the distal phalanx without cortical erosion.

characterized by swelling, pain and erythema of the affected finger.^{2,5} Radiographs show increased soft tissue and periosteal new bone formation, which may have a lamellar or mature bone⁵ appearance. The cortex is usually intact, although erosions have been occasionally described.⁶ The differential diagnosis includes infections (septic tenosynovitis, soft tissue abscess with bone involvement, cortical osteomyelitis), myositis ossificans, benign tumors such as giant cell tendon sheath tumors and osteochondroma, and malignant ones such as the paraostal and periosteal osteosarcoma, synovial sarcoma and periosteal chondrosarcoma.^{1,5} The recommended treatment is local excision, which is curative in most cases.⁵ In conclusion, although FRPH is an uncommon lesion,

[☆] Please cite this article as: Blázquez Cañamero MÁ, et al. Periostitis reactiva florida de la mano. Reumatol Clin. 2014;10:262–263.

* Corresponding author.

E-mail address: mariblazquez@gmail.com (M.Á. Blázquez Cañamero).

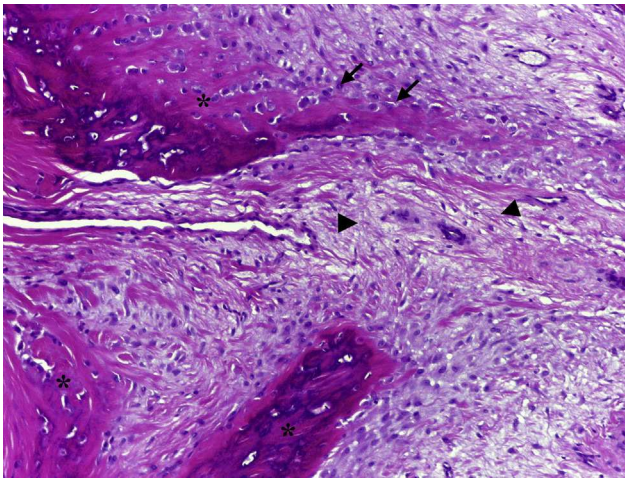


Fig. 2. Photomicrograph of the lesion in which the production of immature osteoid (asterisk) is observed, with abundant osteoblasts (arrows) originating from a fibrous stroma (arrowheads) (hematoxylin–eosin, 10 \times).

it should be taken into account because it can simulate other more serious conditions such as malignant bone neoplasms.

Ethical Responsibilities

Protection of people and animals. The authors declare that no experiments have been performed on humans or animals.

Data confidentiality. The authors declare that they have followed the protocols of their workplace regarding the publication of data from patients and that all patients included in the study have received sufficient information and have given their written informed consent to participate in the study.

Right to privacy and informed consent. The authors have obtained informed patients and/or subjects referred to in the article. This document is in the possession of the corresponding author.

Conflict of Interest

The authors declare no conflicts of interest.

References

1. Valencia González J, Leyva Rodríguez F, Gómez Bajo G, López Barea F, Casado Pérez C. Periostitis reactiva florida: caso clínico y actualización del tema. *Cir Plást Iberolatinoam.* 2009;35:61–8.
2. Rogers GF, Brzeziński MA. Florid reactive periostitis of the middle phalanx: a case report and review of the literature. *J Hand Surg Am.* 1999;24:1014–8.
3. Mallory TB. A group of metaplastic and neoplastic bone- and cartilage-containing tumors of soft parts. *Am J Pathol.* 1933;9:765–76.3.
4. Solana J, Bosch M, Español I. Florid reactive periostitis of the thumb: a case report and review of the literature. *Chir Main.* 2003;22:99–103.
5. Vinglas R, Schnall SB. Florid reactive periostitis of the hand. *Am J Orthop (Belle Mead NJ).* 2010;39:396–8.
6. Jambhekar NA, Desai SS, Puri A, Agarwal M. Florid reactive periostitis of the hands. *Skeletal Radiol.* 2004;33:663–5.