



Review Article

Usefulness of Ultrasonography in the Assessment of Peripheral Entesis in Spondyloarthritis[☆]

M. Cristina Mata Arnaiz,^{a,*} Eugenio de Miguel Mendieta^b^a Sección de Reumatología, Hospital Comarcal de Laredo, Laredo, Cantabria, Spain^b Servicio de Reumatología, Hospital Universitario La Paz, Madrid, Spain

ARTICLE INFO

Article history:

Received 18 August 2013

Accepted 11 November 2013

Available online 12 February 2014

Keywords:

Entesis

Spondyloarthritis

Ultrasound

ABSTRACT

Enthesitis is one of the characteristic etiopathogenic manifestations of spondyloarthritis. However, in clinical practice, its presence often goes unnoticed because of the lack of precision and sensitivity of physical examination to detect it. Viable, valid and reliable imaging tests are needed for early diagnosis, as well as a good sensitivity to change to monitor therapeutic response. In this paper we review the most relevant aspects of current knowledge of the entesis and discuss the validity of ultrasound for assessing enthesitis in spondyloarthritis and its sensitivity to change to monitor therapeutic response.

© 2013 Elsevier España, S.L. All rights reserved.

Utilidad de la ecografía en la evaluación de las entesis periféricas en las espondiloartritis

RESUMEN

La inflamación de la entesis es una de las manifestaciones etiopatogénicas características de las espondiloartritis. Sin embargo, en la práctica clínica, su presencia pasa muchas veces desapercibida debido a la falta de precisión y de sensibilidad de la exploración física para detectarla. Son necesarias pruebas de imagen viables, válidas y fiables para un diagnóstico precoz, y con buena sensibilidad al cambio para monitorizar respuesta terapéutica. En este trabajo, se revisan los aspectos más relevantes de los conocimientos actuales de la entesis y se analiza la validez de la ecografía para valorar entesitis en pacientes con espondiloartritis, así como su sensibilidad al cambio para monitorizar respuesta terapéutica.

© 2013 Elsevier España, S.L. Todos los derechos reservados.

Palabras clave:

Entesis

Espondiloartritis

Ecografía

Introduction

The entesis is considered the target tissue for inflammation in spondyloarthritis (SpA) and is key in the pathogenesis of this group of diseases. From a comparative point of view, we can say that the entesis is for SpA what the synovium is in rheumatoid arthritis (RA). RA is characterized by both arthritis and tenosynovitis, with entesis involvement being non-existent or very minor. However, in SpA inflammation occurs both in entheses and in the

synovial tissue. McGonagle has shown that synovitis that occurs in patients with SpA is secondary to the release of proinflammatory cytokines from the entheses, unlike RA, where a primary autoimmune synovitis¹ is produced. This hypothesis is based on studies of magnetic resonance imaging (MRI) of the knee comparing patients with RA and SpA; patients with SpA had enthesitis and synovitis in the same joint, while patients with RA only had synovitis.²

The concept of SpA as a group appears in 1958, advocated by the theory of “separatists”, who begin to see it as its own entity, on the basis of common clinical features in the patients with this condition which clearly differed from RA.³ However, it was not until 10 years later, in 1970, when the involvement of entheses was first described in the pathogenesis of SpA.⁴ Subsequently, it has been demonstrated that inflammation of the entesis is responsible for many of the symptoms, and explains the multitude of locations of pain in these patients. Thus, at an axial level, it is responsible for inflammatory back pain, sacroiliac pain, chest pain, stiffness and

[☆] Please cite this article as: Mata Arnaiz MC, de Miguel Mendieta E. Utilidad de la ecografía en la evaluación de las entesis periféricas en las espondiloartritis. Reumatol Clin. 2014;10:113–119.

* Corresponding author.

E-mail addresses: cmataa@medynet.com (M.C. Mata Arnaiz), eugenio.demiguel@gmail.com (E. de Miguel Mendieta).

functional limitation and, at a peripheral level, is responsible for plantar fasciitis and Achilles tendinitis as the peripheral entheses most commonly described as affected, and is even implicated in the onychopathy shown by patients with psoriatic arthritis (PsA).⁵

In 1990, Bernard Amor for the first time explicitly collected the involvement of the peripheral entheses as a sign or symptom in the clinical history: “heel pain or pain of other well-defined entheses” in their ranking criteria for the diagnosis of SpA. Later, in 1991, the European Group for the Study of SpA included enthesopathy again as one more “item” on their ranking criteria. However, until the development of modern imaging techniques, especially MRI and ultrasound, the diagnosis of enthesitis has been underestimated, mainly by the lack of sensitivity of the clinical examination for their detection. Thus, the involvement of the entheses has not been properly included in either the evaluation or diagnosis of SpA until today. However, things are changing with the increasingly widespread practice of ultrasound among rheumatologists.^{6,7}

Throughout this article, we will review how ultrasound opens new perspectives and possibilities in the field of SpA.

Definition and Overview of Entheses

Enthesis is defined as the region where a tendon, ligament, joint capsule, fascia or muscle attaches to the bone. It is a transition tissue whose function, besides being a soft tissue anchor, is to transfer the stress in these areas of attachment to the adjacent bone, and vice versa.

Histologically, Benjamin et al.⁸ distinguished 2 types of entheses in relation to the tissue they have in the anchorage zone: the fibrous entheses, which binds metaphysis and diaphysis of long bones, and fibrocartilage entheses, which joins epiphysis and apophysis of long bones, short bones of the hands and feet, and spine. The most common, and the ones of interest because they represent the target organ involvement in SpA, are fibrocartilaginous entheses, although it is unclear if the phenomenon of enthesitis only affects these.

The fibrocartilaginous entheses include 4 histologically distinct areas: (1) a fibrous zone composed of fibers of type 2 collagen and in which versican is the predominant extracellular matrix proteoglycan, (2) uncalcified fibrocartilage zone, in which aggrecan prevails as the extracellular *matrix proteoglycan*, (3) calcified fibrocartilage area and zone and (4) subchondral bone.

The calcified fibrocartilage zone (*zone 2*) of variable thickness and devoid of vessels, is theoretically where entheses injury initially occurs and where the inflammation extends to the synovium and adjacent bone tissue.¹ Nutrition is believed to come from the entheses vessels in the bone marrow, tendon fibrous region and through the adjacent fat and connective tissue.

In 2001, Benjamin and McGonagle introduced the concept of ‘enthesal body’,^{9,10} considering the entheses as a body, formed by different tissues, and defining it as a “*collection of related tissues in and around the entheses, which serve the common function of dissipating tension.*” This attempts to explain why the entheses inflammation experienced by patients diagnosed with diffuse SpA is associated with changes in the surrounding tissues, both soft tissue (bursitis, edema of subcutaneous tissue) and bony unions (erosions, enthesophytes).¹¹

The nail findings (onychopathy) displayed on the SpA are an extension of the changes that occur in the entheses of the distal interphalangeal joints into the matrix and nail bed, as has been shown by MRI.^{5,12}

Furthermore, the synovial tissue of the bursa with the entheses forms the so-called “entheso-synovial complex”. Healthy entheses, in its fibrocartilage area, is avascular and presents low cell density and no inflammatory cells. Instead, the synovium is a vascularized

structure and contains a resident population of immune cells and, therefore, the capacity for hyperplasia and immune response. Moreover, adipose tissue has a *proprioceptive* function by monitoring changes in the angle of insertion of the entheses, an *immune* function, due to its high content of macrophages, and a *nociceptive* function, participating in the painful enthesal disease.

“Enthesopathy” and “Enthesitis”

The term “enthesopathy” refers to the structural alteration of the entheses by mechanical, traumatic, metabolic or even inflammatory causes, while the concept of ‘enthesitis’ is used when there is active inflammation of the entheses, as in SpA, although inflammatory changes may also occur in other, not necessarily inflammatory, conditions. Enthesitis is part of the clinical spectrum of SpA, in all subtypes: ankylosing spondylitis (AS), SpA, Reiter’s syndrome, SpA associated with inflammatory bowel disease, juvenile SpA and, more recently, axial and peripheral SpA, and in almost all patients although, in the literature, the percentage of patients with clinical manifestations of enthesitis is variable (10%–60%).

Clinical Evaluation of Enthesis

The prevalence of enthesitis in SpA is not easy to determine for 2 main reasons: on one hand, the possible subclinical involvement of the entheses and, on the other, the diagnostic difficulty of the clinical examination, due to the absence of visible inflammatory signs. Still, indices have been developed to clinically assess entheses in patients with SpA.

There are 3 validated indices for AS (Mander entheses Index [MEI], Maastricht Ankylosing Spondylitis enthesitis [MASES] and Major) and 2 indices validated for PsA (Gladman and Leeds). The MEI, published by Mander in 1987, evaluates 66 entheses, establishing a pressure pain, ranking making it difficult to apply when in clinical practice.¹³ Subsequently the MASES index was published, a simplification of the above, assessing the presence or absence of pain in 13 entheses. The Major index includes 12 entheses in their assessment: iliac, trochanter, epicondyles, epitrochlear, Achilles and plantar fascia. The Gladman index assesses eight entheses: rotator cuff, anterior tibial tuberosity, Achilles and plantar fascia; Leeds includes 6 entheses in the evaluation: Achilles, medial femoral condyle and epicondyle. The examination is performed by applying constant pressure with the fingertips on the entheses, which leads to loss of objectivity according to the pain threshold, considering it is not the same for each patient.

Evaluation of Enthesis Through Imaging

The reliability and accuracy of the clinical examination to assess entheses are not satisfactory, so imaging techniques have potential use in their objective assessment. X-rays and computed tomography only detect and evaluate structural bone changes that correspond to past episodes of activity or injury and do not inform us of the presence of inflammatory activity in entheses at the time of examination. Thus, imaging tests such as MRI and, more recently, ultrasound, have been employed for the diagnosis of active disease in patients with SpA.

MRI has been used in SpA, mainly to assess axial involvement: cervical, dorsal, lumbar and sacroiliac joints. It allows early visualization of Romanus lesions in the spine and enthesitic interspinous and supraspinal ligament injuries, but mostly it has been validated in sacroiliitis. In the swollen entheses, what is detected by NMR is subcutaneous tissue or soft tissue edema (perienthesitic edema) and bone edema; less frequently it detects entheses edema through their connection between fibroblasts and collagen fibers in the

Table 1
Advantages of Ultrasound in the Examination of the Musculoskeletal System.

Technical advantages	Clinical advantages
<ul style="list-style-type: none"> • No radiation • Cheap • Manageable • Reproducible • Very good acceptance 	<ul style="list-style-type: none"> • Real-time image • Improves the sensitivity of the clinical examination • Detection of subclinical synovitis/enthesitis • Early detection of erosions • Improved effectiveness of infiltrations

fibrous part of the enthesis. For this reason, MRI is insensitive and nonspecific for assessing enthesitis.

However, considering that, until relatively recently, treatment options were limited in SpA, it was not necessary to develop a new imaging technique to assess disease activity and to assess response to treatment.

Ultrasound has a number of technical advantages; it does not emit radiation, it is economical, manageable, reproducible, has very good acceptance by patients and clinicians as well as some clinical advantages, because it offers a real-time image and the ability to evaluate multiple locations during the same examination, improves the sensitivity of the clinical examination in detecting synovitis and enthesitis and likewise improves the sensitivity of plain X-rays in detecting erosions. On the other hand, it is able to adequately guide aspirations and injections, increasing their effectiveness (Table 1). Among the limitations attributed to this method are the time spent although, with practice, this is significantly reduced, and the limited visualization of some locations.

In SpA, in addition to assessing joint involvement, ultrasound is used to assess entheses^{14,15} and is also starting to be used to assess sacroiliac joints. Although its application in SpA is recent, it has already proven superior in terms of sensitivity to clinical examination for detecting enthesitis and¹⁶ has revealed a high

frequency of abnormalities in asymptomatic patients with subclinical enthesitis,¹⁷ which makes it a potential tool for a good objective assessment of patients with SpA.

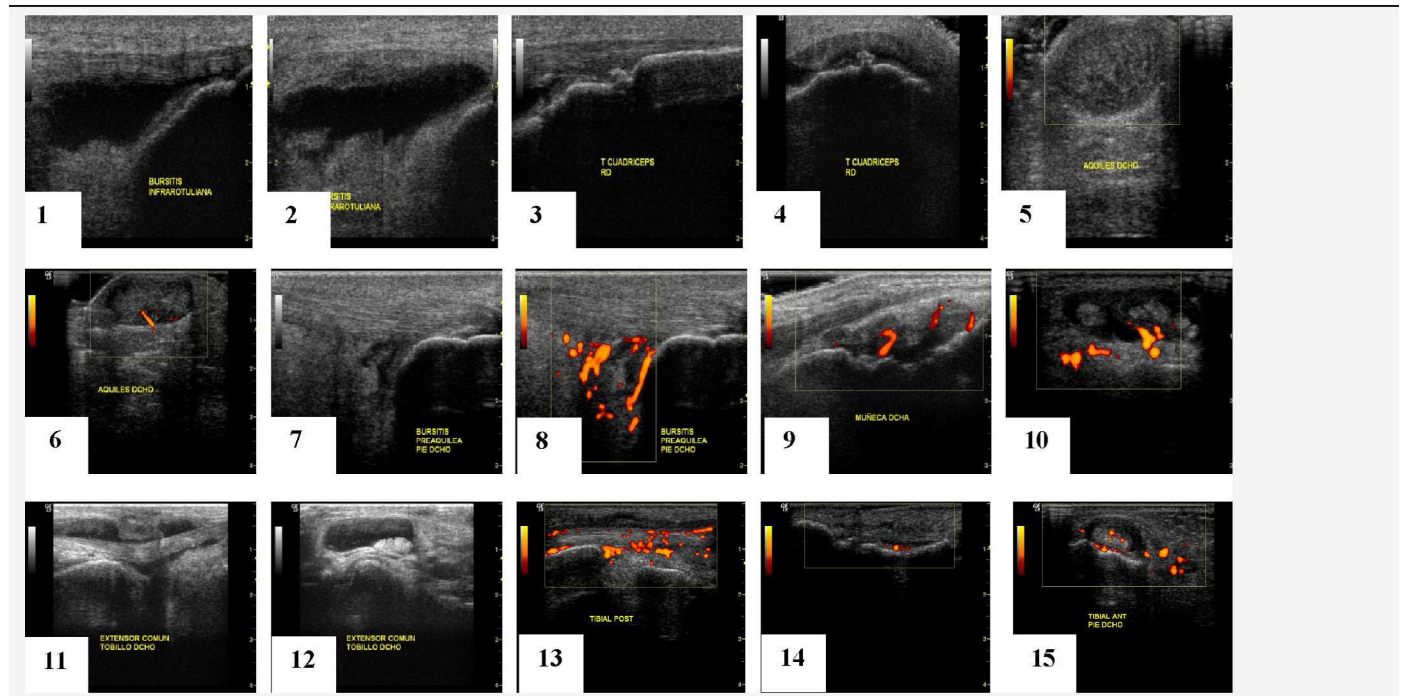
A variety of ultrasound findings in B (grayscale) mode have been described, in peripheral enthesitis of patients with SpA: bursitis, enthesophytes, loss of normal fibrillar echotexture, echogenicity loss, edema of subcutaneous tissue, thickening of the enthesis, bone erosions^{18,19} (Table 2), some of them considered activity lesions, as well as other chronic changes, although this classification of enthesis lesions has not yet been validated in any paper.

Moreover, the Doppler function allows for the detection of hyperemia or pathological vascularization in both the synovium and synovial sheath of tendons, bursae and entheses.²⁰

Evolution of Ultrasound in Spondyloarthritis

In order to perform a standardized assessment of joint ultrasound, it is essential to define and validate ultrasound concepts (Table 3). The Outcome Measures in Rheumatology Working Group (OMERACT) was created to identify, standardize and validate measurement tools, as well as clinically important definitions to be included in clinical trials in rheumatic diseases. Their approach is to apply the so-called 'OMERACT filter' based in turn on that described by Bombardier and Tugwell in 1982,²¹ which simplifies the methodology into 3 basic concepts: truth, discrimination and feasibility; the latter includes the concepts of reliability and sensitivity to change (Table 4).

The application of ultrasound for assessing peripheral arthritis in patients with SpA adopted the same definition and validity concepts used in patients with RA (OMERACT 8), later also validated in SpA.²² Thus, in ultrasound findings of synovitis, tenosynovitis and

Table 2
Lesions Detected by Ultrasound in the Peripheral Affection of Patients With SpA.

Synovitis (9).
Bursitis (1,2,7,8).
Tendinitis/tenosynovitis (5,6,10–15) enthesitis (14).
Cortical bone alterations (erosions, irregularities enthesophytes) (3,4).
Vascularization (Doppler function) (6,8–10,13–15).

Table 3
Standardized Definitions of Joint Ultrasound (OMERACT 7).²³

<i>Synovial hypertrophy</i> : altered nondisplaceable intraarticular tissue, poorly compressible and hypoechoic ^a may show Doppler signal
<i>Synovial fluid</i> : altered hypoechoic intraarticular tissue ^a displaceable, compressible and without Doppler signal
<i>Tenosynovitis</i> : hypoechoic or anechoic thickened tissue with or without synovial fluid within the tendon sheath, seen in two perpendicular planes, which can show Doppler signal
<i>Erosion</i> : disruption of cortical bone seen in two perpendicular planes

Source: Wakefield et al.²³

^a With respect to the subcutaneous fat, but may also be iso or hypoechoic.

erosions in SpA, the same definitions apply than for ultrasound in RA and other inflammatory arthritis (OMERACT 7)²³ (Table 3).

However, in defining the enthesal involvement of patients with SpA, ultrasound has had to start from scratch and the existing evidence created in recent years has led to a progressive and steady acceleration of knowledge.

First, ultrasound has been shown to be a tool with good sensitivity and specificity for the diagnosis of enthesitis.^{16–18} There are enthesitis studies on ultrasound since 1994,¹⁹ but starting in 2002 they began to increase in number and quality of publications. Above all, the description of the features of enthesitis significantly improved in the studies published since 2005, due to the technological advancement of ultrasound equipment, as well as the publication of the first definition of enthesopathy by the OMERACT group. Hypoechoic alterations (loss of normal fibrillar architecture) and/or thickening of the ligament or tendon at its bony insertion (which may occasionally contain hyperechoic foci suggestive of calcification), seen in two perpendicular planes, and which may show, or not, Doppler signal and/bone changes including enthesophytes, erosions and irregularities.

In addition to those described in this definition, there are other basic ultrasound lesions, such as bursitis and alteration of fibrocartilage, probably involved in the pathogenesis of the disease which have led to publications.^{24,25}

Multiple studies have demonstrated *the validity aspect* of ultrasonography for assessing enthesitis,^{14–17,26} as it is also a technique capable of detecting various enthesitis lesions occurring in patients with SpA (thickness, echostructure, edema, bursitis, erosions,

enthesophytes, Doppler signal, tendon ruptures) and in different locations likely to be affected, demonstrating also its *content validity*.²⁶

There are fewer studies that have demonstrated construct^{27–29} and criterion validity.³⁰ Construct validity has been demonstrated obtaining a good correlation between ultrasound and clinical history and examination, both for chronic and acute enthesitis in patients with SpA.²⁹ But, the gold standard for enthesitis is histology which, for obvious reasons, cannot be performed in patients. In an attempt to demonstrate *criterion validity* by correlating ultrasound with what actually happens histologically, McGonagle et al. compared the outcome of³⁰ sonographically evaluating the Achilles entheses of patients with SpA with the histological findings of elderly cadavers, noting in both groups that erosions appear in the most proximal part of the entheses, where there is a greater amount of fibrocartilage and enthesophytes appear in the most distal portion, where the fibrocartilage amount is smaller. Another demonstrated feature has been moderate to excellent inter- and intraobserver *reliability* in the evaluation of Achilles enthesitis in patients with SpA, for all the enthesal findings described in the OMERACT definition except for hypoechoic lesions and cortical irregularities, probably due to lack of standardization of these lesions.¹⁸

There is emerging work demonstrating *sensitivity to change* of ultrasound in examining the progression of SpA, as well as in monitoring response to treatment as we discussed in the section on monitoring.

The first extensive description of ultrasound of enthesitis involvement was performed by Lehtinen et al.¹⁹ in 1994, followed by the description given by Balint et al. in 2002¹⁴; both authors describe the findings in B mode and conclude that there is a high frequency of incidental findings, i.e. patients diagnosed with SpA without enthesal symptoms yet who showed alterations in the enthesitis evaluated by ultrasound or, which is the same, had a subclinical enthesopathy. But, although ultrasound B mode is useful for detecting enthesopathy, it is not so much in revealing active inflammation.

In 2003, D'Agostino et al. described and published a paper on the utility of Power Doppler function to evaluate hyperemia and neovascularization in the entheses, which is indicative of inflammatory activity. For these authors, in addition, the location of the Doppler signal is a specific finding of SpA, as evidenced by comparing patients with this condition to a control group that included patients with RA and patients with low back pain. Patients with SpA had Doppler signals at the enthesitis insertion into cortical bone, whereas the control group presented a peritendinitis Doppler signal, especially of the retrocalcaneal bursa in patients with RA.¹⁵ However, Doppler of the enthesitis has failed to demonstrate criterion validity in the absence of a 'gold standard' or feasible comparison considering that MRI has a low sensitivity for detecting edema in the enthesitis and histology is not feasible for ethical reasons.

Indices for Sonographic Assessment of Enteses

The enthesitis ultrasound can be performed on a particular enthesitis according to the area reported by the patient as painful in the history, or through a more comprehensive assessment examining several entheses. In the literature, various ultrasound enthesal indices are collected, some using only the B or grayscale mode and incorporating the latest Doppler function. Table 5 describes the main features of ultrasound indices used to assess entheses in patients with SpA.

The first and most reproduced published study is called *the Guess Index*, developed by Balint et al.¹⁴ It evaluates four elementary

Table 4
Characteristics of Measuring Instruments.

Term	Definition
<i>Reliability</i>	Accurate, error-free, providing the same result if repeated several times under the same conditions
<i>Feasibility</i>	Simple, easy, accepted by patients and investigators
<i>Validity</i>	Capable or worthy of being accepted, veracity
Face validity	It seems that the instrument is able to measure what we want to measure
In content	Contains elements necessary to measure what we want to measure
Construct	The data obtained from applying the instrument reflect the theory or theoretical construct, correlates with other measures or variables accepted as true
Criterion	The instrument has good sensitivity and specificity when compared to a 'gold standard' whose validity has been demonstrated
<i>Sensitivity to change (Responsiveness)</i>	Instrument's ability to detect real changes

Table 5
Description of the Characteristics of Different Indices to Assess Ultrasound Enthesis.

	Guess (<i>Balint</i>)	D'Agostino doppler	SEI		MASEI
Evaluated entheses	Quadriceps Proximal patellar Achilles distal patellar Plantar fascia	Guess + anterior tibial, lateral epicondyle, medial epicondyle	Guess		Guess + triceps
Basic lesions	Thickness ^a Enthesophytes Erosion Bursitis (if applicable)	Guess + Doppler	Acute (SEI-A) ↑ thickness ↓ echogenicity Edema Bursitis (if applicable)	Chronic (SEI-C) ↓ thickness Calcifications Tendon ruptures Bone erosions	Thickness ^a Enthesophytes/calcifications Erosion Bursitis Structural Changes Doppler
Score	Absent = 0 Present = 1 Min–max.: 0–36	Staging 1 2a 2b 3a 3b	Absent = 0 Present = 1 SEI-A min–max.: 0–36 SEI-C min–max.: 0–40 Top score = 76		↑ thickness (no = 0, yes = 1) Enthesophytes/calcifications (0, 1, 2 or 3 ^b) Erosions (no = 0, yes = 3) Bursitis (no = 0, yes = 1) Structural changes (no = 0, yes = 1) Doppler ^c (no = 0, yes = 3) Min–max. = 0–136

^a Increase in thickness if: plantar fascia ≥ 4.4 mm; Achilles ≥ 5.29 mm, patellar (proximal, distal) ≥ 4 mm; quadriceps ≥ 6.1 mm; triceps ≥ 4.3 mm.

^b 0, absent; 1, ≤ 5 mm; 2, 5–10 mm; 3, ≥ 10 mm.

^c Today, there is no semiquantitative method in entheses, not least because the sensitivity of the equipment is still very low and vascularization is much lower than in synovitis.

lesions (thickness, enthesophytes, erosions and bursitis) bilaterally on 5 entheses of the lower extremity, using only B-mode demonstrating that ultrasound exceeds physical examination in sensitivity to assess enthesitis. D'Agostino et al. introduced the Doppler function in the assessment of entheses,¹⁵ noting that ultrasound is a useful technique to assess both elementary enthesitis lesions, to detect inflammatory activity in patients with SpA. It establishes five evolutionary stages in the involvement of the entheses (Table 6).

Both indices (Guess and D'Agostino) are preliminary and predate the definition of enthesopathy proposed by OMERACT.²³ The Spanish enthesitis index (SEI Index) is an extension of the elementary lesions of the Guess index, which also evaluates decreased echogenicity, tendon ruptures, decreased thickness and edema; seeks to identify lesions consistent with active inflammation (SEI-A) and chronicity (SEI-C), based on the opinion of the authors, and does not use Doppler¹⁶; correlations of this index with other outcome variables used in SpA are poor or do not reach significance, especially in the activity index.

The Madrid Sonographic enthesitis Index (*MASEI Index*) is the most complete so far and the only one based on the OMERACT definition of enthesopathy. It has demonstrated higher sensitivity (83.3%) and specificity (82.8%) in the diagnosis of SpA in patients who present a score ≥ 18 .¹⁷

There is only one published work in which *Doppler ultrasound evaluated through the MASES clinical index is performed*, which assesses 13 entheses,³¹ but the results were not good; it showed that clinical examination was more sensitive than ultrasound in most entheses, except for Achilles entheses, probably

because for the rest of the entheses evaluated by this index, ultrasound windows used were not standardized or were easily reproducible.

Although bursitis is not included in the OMERACT definition of enthesopathy, all published indices ultrasound searched for this lesion. However, none included fibrocartilage lesions as elemental alterations, probably limited by ultrasound equipment used in their evaluation and due to its recent description. This article also did not demonstrate a high sensitivity and specificity in the classification of patients with SpA.

Enthesis Ultrasound to Monitor Response to Biological Treatments

Although the use of ultrasound in SpA lags behind its use in RA, it is proving valid for the diagnosis of enthesitis and some study results also demonstrate its validity for monitoring progress and response to treatment.

Therapeutic options are limited for enthesitis: NSAIDs, local injections and, more recently, tumor necrosis factor (TNF) antagonist drugs have shown efficacy as measured by clinical examination, MRI and ultrasound.

Some studies have evaluated the sensitivity to change of ultrasound in enthesal manifestations of patients with SpA treated with sulfasalazine, with no differences at 6–12 months of treatment, probably not for lack of discriminant validity of the technique, but ineffectiveness of the drug for this condition.^{32,33}

In another recent study in which the sensitivity to change of ultrasonography in Achilles enthesitis (grayscale and power Doppler signal) of AS patients treated with an TNF antagonist drug (etanercept, infliximab or adalimumab) was evaluated, all ultrasound findings improved after 2 months of anti-TNF therapy,³⁴ although the results are poor.

But the best study to evaluate the response to treatment of various enthesal lesions is probably that published by Naredo et al.³⁵ It evaluated, on one hand, lesions considered inflammatory (hypoechoogenicity, thickening, power Doppler signal) and, on the other hand, structural lesions considered due to damage or chronic (enthesophytes and erosions). The described inflammatory lesions

Table 6
Ultrasound Staging Index by D'Agostino.

1 Vascularization in the cortical union without lesions in B mode
2a Edema associated vascularization and/or decreased binding in cortical echogenicity in B mode
2b findings in B mode of stage 2 without vascularization
3a stage 2A + erosions or entheses calcifications and optional associated bursitis
3b stage 3 findings in B mode without vascularization

as well as the bursitis adjacent to the enthesis showed significant improvement after 6 months of anti-TNF therapy (infliximab, etanercept or adalimumab), while chronic lesions worsened despite anti-TNF therapy.

However, a study published subsequently demonstrated that enthesal erosions in patients with SpA³⁶ are reversible and therefore should not be considered as a chronic structural lesion in these patients. In addition, ultrasound demonstrated sensitivity to change and therefore it is a useful tool for assessing Achilles enthesitis erosions in patients with SpA.

In conclusion, we can say that enthesitis is a key event in the clinical expression of SpA, but the physical exploration of the entheses lacks sensitivity, accuracy and reliability, which is a clear deficiency in the clinical assessment of these patients. For this reason, the use of imaging techniques to increase their accuracy and detect subclinical enthesitis becomes necessary. In this sense, ultrasound is gaining on MRI, mainly not only for its technical advantages, but also because it is demonstrating reliability, validity and, more recently, sensitivity to change. Much has been advanced and in a relatively short time, but for ultrasound to be useful in clinical practice it is necessary to validate and agree on enthesal ultrasound indices.

Ethical Responsibilities

Protection of persons and animals. The authors state that no experiments were performed on persons or animals for this study.

Data confidentiality. The authors state that they have followed their workplace protocols regarding the publication of patient data and all patients included in the study have received enough information and have given their written informed consent to participate in the study.

Right to privacy and informed consent. The authors state that they have obtained informed consent from patients and/or subjects referred to in this article. This document is in the possession of the corresponding author.

Conflict of Interest

This article summarizes the final work of the first author in the Master of Spondylarthritis of the European University of Madrid, sponsored by Abbvie.

References

- McGonagle D, Gibbon W, Emery P. Classification of inflammatory arthritis by entesitis. *Lancet*. 1998;352:1137–40.
- McGonagle D, Benjamin M, Marzo-Ortega H, Emery P. Advances in the understanding of enthesal inflammation. *Curr Rheumatol Rep*. 2002;4:500–6.
- McEwen C, Ziff M, Carmel P, Ditata D, Tanner M. The relationship to rheumatoid arthritis of the so-called variants. *Arthritis Rheum*. 1958;1:481–9.
- Ball J. Entesopathy of rheumatoid and ankylosing spondylitis. *Ann Rheum Dis*. 1971;30:213–23.
- McGonagle D. Entesitis: an autoinflammatory lesion linking nail and joint involvement in psoriatic disease. *J Eur Acad Dermatol Venereol*. 2009;23:9–13.
- De Miguel E, Andreu JL, Naredo E, Möller I, Grupo de Trabajo de Ecografía de la Sociedad Española de Reumatología (ECOSER). Situación de la ecografía en la reumatología española 2012. *Reumatol Clin*. 2012;8:310–4.
- De Miguel E, Andreu JL, Naredo E, Möller I, Grupo de Trabajo de Ecografía de la Sociedad Española de Reumatología (ECOSER). La ecografía en reumatología: dónde estamos y hacia dónde nos dirigimos. *Reumatol Clin*. 2013. <http://dx.doi.org/10.1016/j.reuma.2013.04.005> [in press].
- Benjamin M, Toumi H, Ralphs JR, Vides G, Best TM, Milz S. Where tendons and ligaments met bone: attachment sites (entheses) in relation with exercise and/or mechanical load. *J Anat*. 2006;208:471–90.
- Benjamin M, McGonagle D. The anatomical basis for disease localization in seronegative spondyloarthropathy at entheses and related sites. *J Anat*. 2001;199:503–26.
- Benjamin M, Moriggl B, Brenner E, Emery P, McGonagle D, Redman S. The entheses organ concept. Why enthesopathies may not present as focal insertional disorders. *Arthritis Rheum*. 2004;50:3306–13.
- McGonagle D, Wakefield RJ, Tan AL, D'Agostino MA, Toumi H, Hayashi K, et al. Distinct topography of erosion and new bone formation in Achilles tendon entesitis: implications for understanding the link between inflammation and bone formation in spondyloarthritis. *Arthritis Rheum*. 2008;58:2694–9.
- Tan AL, Benjamin M, Toumi H, Grainger AJ, Tanner SF, Emery P, et al. The relationship between the extensor tendon entheses and the nail in distal interphalangeal joint disease in psoriatic arthritis: a high-resolution MRI and histological study. *Rheumatology*. 2007;46:253–6.
- Mander M, Simpson J, McLellan A, Walker D, Goodcare J, Dick WC. Studies with an entheses index as a method of clinical assessment in ankylosing spondylitis. *Ann Rheum Dis*. 1987;46:197–202.
- Balint PV, Kane D, Wilson H, McInnes IB, Sturrock RD. Ultrasonography of enthesal insertions in the lower limb in spondyloarthropathy. *Ann Rheum Dis*. 2002;61:905–10.
- D'Agostino MA, Said-Nahal R, Hacquard-Bouder C, Brasseur JL, Dougados M, Breban M. Assessment of peripheral enthesitis in the spondyloarthropathies by ultrasonography combined with power Doppler. *Arthritis Rheum*. 2003;48:523–33.
- Alcalde M, Acebes JC, Cruz M, González-Hombrado L, Herrero-Beaumont G, Sánchez-Peranute O. A Sonographic Entesitic Index of lower limbs is a valuable tool in the assessment of ankylosing spondylitis. *Ann Rheum Dis*. 2007;66:1015–9.
- De Miguel E, Cobo T, Muñoz-Fernández S, Naredo E, Usón J, Acebes JC, et al. Validity of entheses ultrasound assessment in spondyloarthropathy. *Ann Rheum Dis*. 2009;68:169–74.
- Filippucci E, Aydin SZ, Karadağ O, Salaffi F, Gutierrez M, Direskeneli H, et al. Reliability of high-resolution ultrasonography in the assessment of Achilles tendon entesopathy in seronegative spondyloarthropathies. *Ann Rheum Dis*. 2009;68:1850–5.
- Lehtinen A, Taavitsainen M, Leirisalo-Repo M. Sonographic analysis of entesopathy in the lower extremities of patients with spondyloarthropathy. *Clin Exp Rheumatol*. 1994;12:143–8.
- Walther M, Harms H, Krenn V, Radke S, Faehndrich TP, Gohlke F. Correlation of power Doppler sonography with vascularity of the synovial tissue of the knee joint in patients with osteoarthritis and rheumatoid arthritis. *Arthritis Rheum*. 2001;44:331–8.
- Bombardier C, Tugwell P. A methodological framework to develop and select indices for clinical trials: statistical and judgmental approaches. *J Rheumatol*. 1982;9:753–7.
- Joshua F, Lassere M, Bruyn GA, Szkudlarek M, Naredo E, Schmidt WA, et al. Summary findings of a systematic review of the ultrasound assessment of synovitis. *J Rheumatol*. 2007;34:839–47.
- Wakefield R, Balint PV, Szkudlarek M, Filippucci E, Backhaus M, D'Agostino MA, et al. Musculoskeletal ultrasound including definitions for ultrasonographic pathology. *J Rheumatol*. 2005;32:2485–7.
- Falcao S, de Miguel E, Castillo-Gallego C, Peiteado D, Branco J, Martín Mola E. Entesitis ultrasound: the importance of the bursa in spondyloarthritis. *Clin Exp Rheumatol*. 2013;31:422–7.
- Aydin SZ, Bas E, Basci O, Filippucci E, Wakefield R, Çelikel Ç, et al. Validation of ultrasound imaging for Achilles enthesal fibrocartilage in bovines and description of changes in humans with spondyloarthritis. *Ann Rheum Dis*. 2010;69:2165–8.
- Gandjbakhch F, Terslev L, Joshua F, Wakefield RJ, Naredo E, D'Agostino MA. Ultrasound in the evaluation of entesitis: status and perspectives. *Arthritis Res Ther*. 2011;13:R188.
- Hatemi G, Fresko I, Tascilar K, Yazici H. Increased entesopathy among Beçhet' syndrome patients with acne and arthritis: an ultrasonography study. *Arthritis Rheum*. 2008;58:1539–45.
- Gisoni P, Tinazzi I, El-Dalati G, Gallo M, Biasi D, Barbara LM, et al. Lower limb entesopathy in patients with psoriasis without clinical signs of arthropathy: a hospital-based case-control study. *Ann Rheum Dis*. 2008;67:26–30.
- Klauser AS, Wipfler E, Dejaco C, Moriggl B, Duftner C, Schirmer M. Diagnostic values of history and clinical examination to predict ultrasound signs of chronic and acute entesitis. *Clin Exp Rheumatol*. 2008;26:548–53.
- McGonagle D, Wakefield RJ, Tan AL, D'Agostino MA, Toumi H, Hayashi K, et al. Distinct topography of erosion and new bone formation in achilles tendon entesitis: implications for understanding the link between inflammation and bone formation in spondyloarthritis. *Arthritis Rheum*. 2008;58:2694–9.
- Kiris A, Kaya A, Ozgocmen S, Kocakoc E. Assessment of entesitis in ankylosing spondylitis by power Doppler ultrasonography. *Skeletal Radiol*. 2006;35:522–8.
- Lehtinen A, Leirisalo-Repo M, Taavitsainen M. Persistence of entesopathic changes in patients with spondylarthropathy during a 6-month follow-up. *Clin Exp Rheumatol*. 1995;13:733–6.
- Genc H, Duyur Cakit B, Nacir B, Saracoglu M, Kacar M, Erdem HR. The effects of sulfasalazine treatment on diseases. *Clin Rheumatol*. 2007;26:1104–10.

34. Aydin SZ, Karadag O, Filippucci E, Atagunduz P, Akdogan A, Kalyoncu U, et al. Monitoring Achilles entesitis in ankylosing spondylitis during TNF- α antagonist therapy: an ultrasound study. *Rheumatology*. 2010;49:578–82.
35. Naredo E, Batlle-Gualda E, Luz García-Vivar M, García-Aparicio AM, Fernández-Sueiro JL, Fernández-Prada M, et al. Power Doppler ultrasonography assessment of entheses in spondyloarthropathies: response to therapy of enthesal abnormalities. *J Rheumatol*. 2010;37:2110–7.
36. De Miguel E, Falcao S, Castillo C, Plasencia C, Gracia M, Branco JC, et al. Enthesis erosion in spondyloarthritis is not a persistent structural lesion. *Ann Rheum Dis*. 2011;70:2008–10.