

Case Report

Sternoclavicular Septic Arthritis: A Series of 5 Cases and Review of the Literature[☆]



Carlos Guillén Astete,^{a,b,*} Yolanda Aranda García,^a Cristina de la Casa Resino,^a María Carpena Zafrilla,^a Adela Braña Cardeñosa,^a Fernando Roldan Moll,^a César Carballo,^a Antonio Zea Mendoza^b

^a Servicio de Urgencias, Hospital Universitario Ramón y Cajal, Madrid, Spain

^b Servicio de Reumatología, Hospital Universitario Ramón y Cajal, Madrid, Spain

ARTICLE INFO

Article history:

Received 10 January 2014

Accepted 21 March 2014

Available online 25 June 2014

Keywords:

Infectious arthritis
Septic arthritis
Sternoclavicular joint

ABSTRACT

Infectious arthritis is a medical emergency whose prognosis, in terms of general morbidity and the final functionality of the joint, depends on rapid diagnosis and treatment. The sternoclavicular joint is an area of low prevalence of this type of arthritis, although its frequency is often concentrated in immunosuppressed patients, users of parenteral drugs or after traumatic events. We present a series of 5 microbiologically documented cases of sternoclavicular septic arthritis, 3 of which occurred in immunocompetent patients, and a short review of this pathology.

© 2014 Elsevier España, S.L.U. All rights reserved.

Artritis infecciosa esternoclavicular: serie de 5 casos y revisión de la literatura

RESUMEN

La artritis infecciosa es una urgencia médica de cuyo rápido diagnóstico depende el pronóstico a corto y medio plazo del estado general del paciente y de la funcionalidad final de la articulación. La articulación esternoclavicular es una región de baja prevalencia de este tipo de artritis, aunque su frecuencia se suele concentrar en pacientes inmunosuprimidos, usuarios de drogas parenterales o tras procedimientos traumáticos. Presentamos una serie de 5 casos microbiológicamente documentados de artritis infecciosa esternoclavicular, 3 de los cuales se presentaron en pacientes inmunocompetentes, y una revisión de esta peculiar enfermedad.

© 2014 Elsevier España, S.L.U. Todos los derechos reservados.

Palabras clave:

Artritis infecciosa
Artritis séptica
Articulación esternoclavicular

Introduction

Septic arthritis of native joints (NJSAs) often poses a diagnostic problem as its cardinal clinical semiology is comparable to that of other forms of arthritis.^{1,2} Also, certain topographical locations make it difficult to recognize because of the poorly distensible nature of some synovial joints, low inflammatory permeability or because they are certainly uncommon. This is the case of septic

arthritis of a sternoclavicular joint, in which infectious disease is considered very rare,^{1,3} and which, moreover, has been associated with immunosuppression situations, neoplasia or secondary metabolic deficiency states.^{2–6}

Clinical Observation

We present a series of 5 cases of sternoclavicular NJSAs diagnosed in the emergency department of our hospital between 2012 and 2013, but none of which have been previously included in other series (Table 1).

Case 1. Male, 45 years. He consulted for clavicular pain of 2 weeks duration and fever of recent onset with pain and sternoclavicular swelling. Ultrasonography showed capsular distension with intraarticular and periarticular power Doppler signal (PDS). The patient was successfully treated with cloxacillin for 6 weeks and

[☆] Please cite this article as: Guillén Astete C, Aranda García Y, de la Casa Resino C, Carpena Zafrilla M, Braña Cardeñosa A, Roldan Moll F, et al. Artritis infecciosa esternoclavicular: serie de 5 casos y revisión de la literatura. Reumatol Clin. 2015;11:48–51.

* Corresponding author.

E-mail address: cguillen.hrc@salud.madrid.org (C. Guillén Astete).

Table 1
Demographic Overview, Additional Tests and Management-Development.

Patient	Gender and age (years)	Comorbidities	Point of entry	Time since onset of symptoms
1	Male, 45	None	Unidentified	14 days
2	Male, 56	Hypertension	Unidentified	21 days
3	Female, 55	Hypertension, chronic renal insufficiency (CrCl 50 mg/dL)	Hematogenous, lower respiratory infection	19 days
4	Male, 75	Hypertension, prostate adenocarcinoma, bone metastases	Unidentified	15 days
5	Male, 55	Hyperferritinemia, hypercholesterolemia	Unidentified	4 days

Patient	Leukocytes (% neutrophils)	CRP (mg/L)	X ray of sternoclavicular joint	Ultrasound	CT
1	12,500 (80)	240	No findings	Distension of the joint capsule, PDS signal (+ + + / + + +)	Sternoclavicular arthritis, sternal osteomyelitis
2	16,800 (85)	188	Not performed	Distension of the joint capsule, PD signal (+ + / + +)	Sternoclavicular arthritis, sternal and clavicular osteomyelitis, sternohyoid myositis and clavicular body of the sternocleidomastoid
3	13,400 (85)	211	Irregularities in the clavicular cortical side	Distension of the capsule, cortical irregularity, negative PD signal	Sternoclavicular arthritis, myositis of the sternocleidomastoid clavicular body
4	12,300 (86.1)	290	Not performed	Not performed	Sternoclavicular joint arthritis with effusion without cortical damage. Myositis in the sternocleidomastoid, platysma and prelaryngeal muscles and subcutaneous tissue
5	7,550 (78.3)	391	Not performed	Distension of the capsule, positive PD signal, presence of periarticular subcutaneous abscess	Sternoclavicular joint arthritis with effusion. Involvement of the clavicular sternocleidomastoid branch. Subcutaneous abscess at the joint surface

Patient	Germ isolated	Intravenous treatment	Oral treatment	Progression
1	<i>Staphylococcus aureus</i>	Cloxacillin, 6 wk	Amoxicillin, 4 wk	Rapid improvement of the general state and fever on the third day. Complete functional recovery
2	<i>Staphylococcus aureus</i>	Vancomycin 4 wk	Amoxicillin, 4 wk	Required surgical debridement. Subsequently, good evolution. Required physiotherapy due to limitation of external rotation of the shoulder and neck with contralateral lateralization
3	<i>Streptococcus pneumoniae</i>	Cloxacillin, 6 wk	Cloxacillin, 6 wk	Required surgical debridement. Subsequently, good performance. Required physiotherapy due to limitation of cervical extension and intermediate degrees of rotation in contralateral direction to the lesion
4	<i>Staphylococcus aureus</i>	Vancomycin metronidazole + 3 wk	Vancomycin metronidazole + 6 wk	Favorable recovery
5	<i>Staphylococcus aureus</i>	Cloxacillin 16 days	Clindamycin, 8 wk	Required surgical debridement. Good progression afterward

CrCl: creatinine clearance of 24 h; HT: hypertension; CRP: C-reactive protein; PD: power Doppler signal; CT: computed tomography.

then amoxicillin for 4 weeks. *Staphylococcus aureus* was isolated both in the synovial fluid (SF) and in the blood culture.

Case 2. Male, 56 years. He consulted for clavicular and cervical pain of 3 weeks of evolution. The point of entry was not identified. One day before admission the patient had high fever and severe fatigue. In the ER we detected fever, tachycardia, and malaise, with a normal blood pressure. On ultrasound we found capsular distension of the sternoclavicular joint with intraarticular PDS (+) identified as well as in the territory of the clavicular sternocleidomastoid. Computed tomography (CT) showed myositis of the sternohyoid and the distal medial clavicular fibers of the sternocleidomastoid branch. It required surgical lavage. *Staphylococcus aureus* was isolated in blood cultures and SF.

Case 3. 55-year-old woman, who had a mechanic shoulder pain radiating to the collarbone since 19 days earlier. She had been hospitalized about five days ago for pneumonia and, postdischarge, consulted for progressive shoulder pain and fever in the past 2 days, with no respiratory symptoms. Ultrasonography showed

capsular distension, cortical irregularities on both sides, with PDS (–) intraarticularly and PDS (+/+ + +) in the fibers of the clavicular sternocleidomastoid body. Surgical lavage was performed and treatment was started with cloxacillin, with a good response. SF Cultures showed *Streptococcus pneumoniae*.

Case 4. Male 75 years, allergic to beta-lactams, diagnosed with actinic proctitis. He consulted for rectal bleeding, fever of 39 °C and pain in the cervical region for 2 days. In the ER he developed erythema and edema, as well as pain on palpation of the anterior cervical region. A cervical CT angiography determined swelling of the sternoclavicular joint and the sternocleidomastoid, with protrusion into the premediastinic space (Fig. 1) contacting the brachiocephalic vein. In the SF, *Staphylococcus aureus* was isolated.

Case 5. Male 55 years. He consulted for a painful swelling of the left chest, of 24 h of evolution. Four days before he consulted for atraumatic left shoulder pain. He presented erythematous and painful swelling of the sternoclavicular joint, fluctuating and with sharp edges. Ultrasonography showed capsular distension and PDS

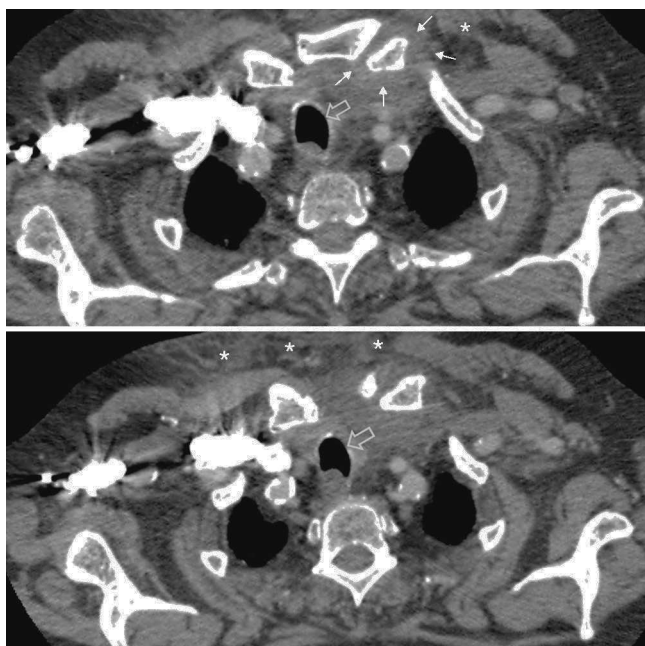


Fig. 1. Case 4. Two sequential sections of the upper thoracic CT. Limits of the articular capsule (white arrows), involvement of subcutaneous soft tissue (asterisks) and deviation of the airway (open arrow) can be seen.

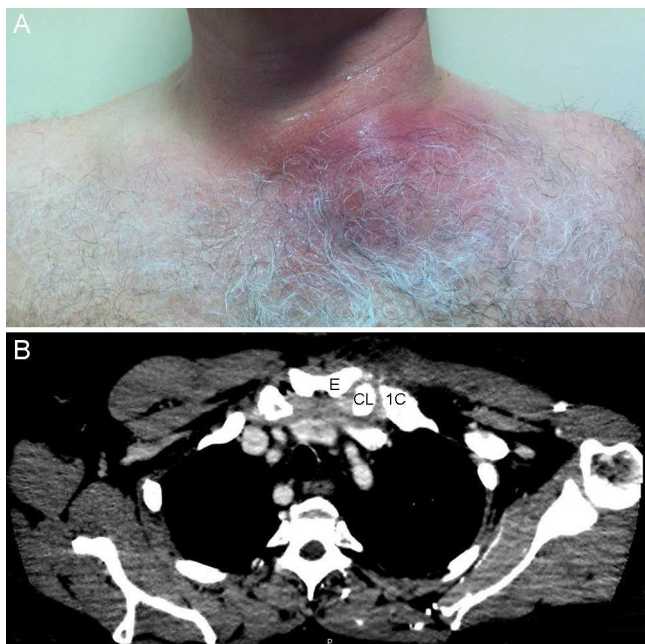


Fig. 2. Case 5. (A) outward appearance. (B) CT of the thorax, showing the sternoclavicular joint capsular distention and inflammatory contents inside. (C) clavicle; (E) sternum; (1C) first rib.

(+) both intracapsular as extracapsularly. A superficial abscess of the joint was also identified. A CT scan confirmed the findings and also detected involvement of the distal clavicular sternocleidomastoid body (Fig. 2). Surgical drainage was required. *S. aureus* was isolated in the culture.

Discussion and Conclusions

Sternoclavicular NJSA is an uncommon disease, in both immunocompetent and immunosuppressed patients.^{1,7} The largest

collection of the world's scientific literature includes 170 cases from more than 70 studies published between 1970 and 2004.⁶ Another more recent compilation published in 2004 collected 15 cases, documented between 1989 and 2012.⁵ It is usually described in the fourth to fifth decade of life, like other atypical location NJSA.^{1,4,6} The risk factors identified in the literature are: intravenous drug use, infections at a distance, diabetes mellitus, local trauma, central line infection, chronic renal failure, alcoholism, HIV infection, neoplastic disease and cirrhosis.^{1–3} Usually it is clinically insidious and can be confused with mechanical neck pain or shoulder pain with clavicular irradiation.¹ In our series, the diagnosis is established after the second week of the onset of symptoms, with the exception of case 4. The most commonly used test for diagnosis was ultrasonography, although confirmation and assessment of the cortical scope required a CT. The most common complication in our series was myositis, a situation that requires surgical debridement, prolonged hospital stays and physical therapy due to residual functional limitation. Osteomyelitis has also been reported in other series.⁸ In ours, osteomyelitis was described mainly in patients with PDS (+) an intraarticular, sonographic sign denoting intense hyperemia.⁹

The sternoclavicular joint is poorly vascularized, so antibiotic treatment is usually prolonged and management follows a pattern similar to empirical antibiotic therapy of infections of the more common joints affected.^{2,3}

In general terms, the clinical onset in immunocompromised patients is no different from the one presented in immunocompetent patients. In our series, we have seen striking differences in the presentation of clinical symptoms: insidious, referred pain to the neck or shoulder, and fever.^{1,3} In this sense, we conclude that the situation of immunocompetence should neither rule out the diagnosis nor defer empiric treatment of suspected sternoclavicular NJSA.

Ethical Responsibilities

Protection of people and animals. The authors declare that this research did not perform experiments on humans or animals.

Data confidentiality. The authors declare that they have followed the protocols of their workplace regarding the publication of data from patients, and all patients included in the study have received sufficient information and gave written informed consent to participate in the study.

Right to privacy and informed consent. The authors have obtained informed consent from patients and/or subjects referred to in the article. This document is in the possession of the corresponding author.

Conflict of Interest

The authors have no disclosures to make.

References

1. Womack J. Septic arthritis of the sternoclavicular joint. *J Am Board Fam Med.* 2012;25:908–12.
2. Yood RA, Goldenberg DL. Sternoclavicular joint arthritis. *Arthritis Rheum.* 1980;23:232–9.
3. Ross JJ, Shamsuddin H. Sternoclavicular septic arthritis: review of 180 cases. *Medicine (Baltimore).* 2004;83:139–48.
4. Hermet M, Minichiello E, Flipo RM, Dubost JJ, Allanore Y, Ziza JM, et al. Infectious sacroiliitis: a retrospective, multicentre study of 39 adults. *BMC Infect Dis.* 2012;12:305.

5. Martínez-Morillo M, Mateo Soria L, Riveros Frutos A, Tejera Segura B, Holgado Pérez S, Olivé Marqués A. Septic arthritis of the acromioclavicular joint: an uncommon location. *Reumatol Clin.* 2014;10:37–42.
6. Ross JJ, Hu LT. Septic arthritis of the pubic symphysis: review of 100 cases. *Medicine (Baltimore).* 2003;82:340–5.
7. Gupta MN, Sturrock RD, Field M. A prospective 2-year study of 75 patients with adult-onset septic arthritis. *Rheumatology (Oxford).* 2001;40:24–30.
8. Weston VC, Jones AC, Bradbury N, Fawthrop F, Doherty M. Clinical features and outcome of septic arthritis in a single UK Health District 1982–1991. *Ann Rheum Dis.* 1999;58:214–9.
9. Brown AK, O'Connor PJ, Roberts TE, Wakefield RJ, Karim Z, Emery P. Recommendations for musculoskeletal ultrasonography by rheumatologists: setting global standards for best practice by expert consensus. *Arthritis Rheum.* 2005;53:83–92.