

Images in Clinical Rheumatology

Isolated Splenic Sarcoidosis[☆]



Sarcoidosis esplénica aislada

Antonio Ruiz Serrato,^{a,*} M. Ángeles Guerrero León,^a Juan Jiménez Martín,^b Desirée Gómez Lora^a

^a Servicio de Medicina Interna, Hospital de Antequera, Málaga, Spain

^b Servicio de Anatomía Patológica, Hospital de Antequera, Málaga, Spain

ARTICLE INFO

Article history:

Received 3 December 2013

Accepted 16 January 2014

Available online 28 September 2014

A 37-year-old Caucasian woman, with no medical history of interest was seen at the clinic. She had presented epigastric and left hypochondrial mild, intermittent pain for years, with a daily frequency and with no relation to meals, having no other associated systemic symptoms. Physical examination was normal. Laboratory studies showed normal acute phase reactants, peripheral blood smear and angiotensin converting enzyme, as well as proteins and autoimmunity, infectious disease (including hydatidosis) and a Mantoux test. Chest and abdomen test, gastrointestinal tran-

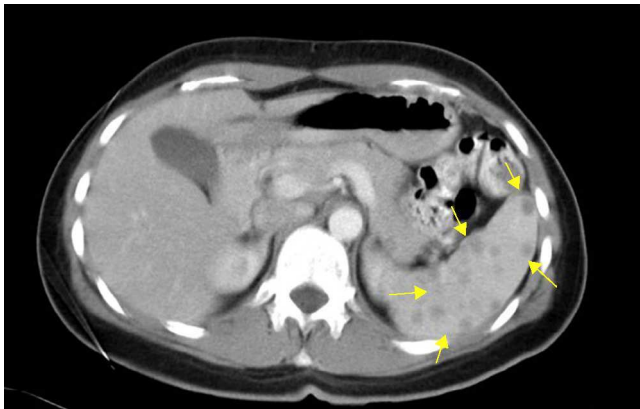


Fig. 1. Abdominal contrast CT scan, which shows multiple spleen lesions with no contrast uptake (arrows).

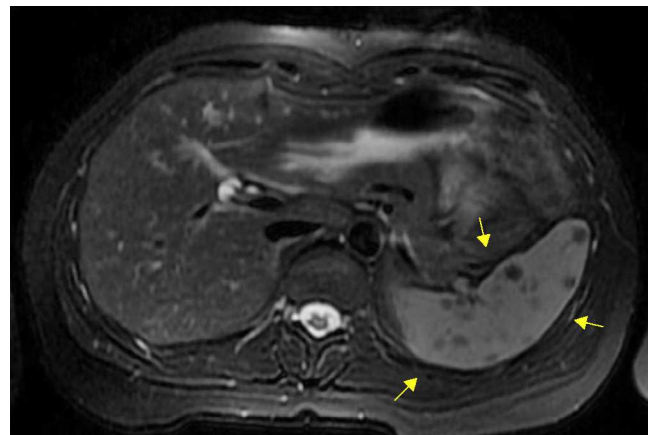


Fig. 2. Abdominal MIR with gadolinium center in T2 showing splenic lesions (arrows).

sit images and electrocardiogram were all normal. An abdominal ultrasound and thoracoabdominal computed tomography showed multiple splenic lesions measuring 7–9 mm in diameter, with no spleen enlargement (Fig. 1). The abdominal magnetic resonance showed multiple lesions on the spleen, hypointense in T2 and isointense in T1, with homogeneous and late enhancement upon contrast, with a diameter under 1 cm (Fig. 2). Due to the persistence of left hypochondrial pain as well as the diagnostic uncertainty, a laparoscopic splenectomy was programmed. Macroscopically, the spleen presented multiple external and intraparenchymal nodules of a white-fibrous aspect and with a diameter under 1 cm; microbiological tests were negative and the lesions were histologically compatible with non-casefying epithelioid granulomas (Fig. 3). After the uncomplicated splenectomy, the patient remained asymptomatic and with no treatment during follow-up.

[☆] Please cite this article as: Ruiz Serrato A, Guerrero León MÁ, Jiménez Martín J, Gómez Lora D. Sarcoidosis esplénica aislada. Reumatol Clin. 2015;11:54–55.

* Corresponding author.

E-mail address: ito.ruizserrato@gmail.com (A. Ruiz Serrato).

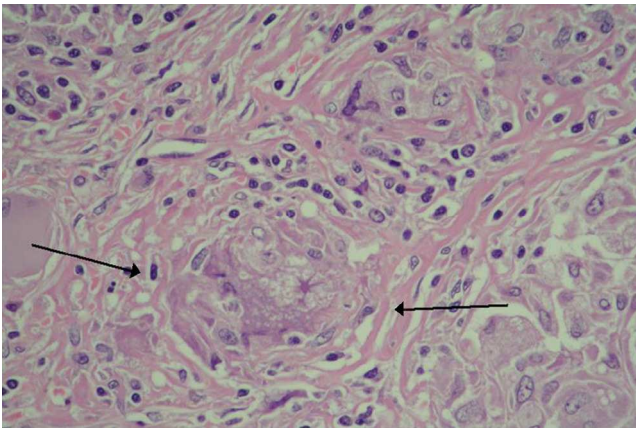


Fig. 3. Microscopic histology of the spleen with non-caseating granulomas (arrows).

Sarcoidosis is a granulomatous multisystemic disease of unknown etiology.¹ More than 90% of affected patients have pulmonary manifestations at the moment of diagnosis.² The extrapulmonary multiorganism affection is frequent, with the spleen involved in 10% in imaging studies and up to 40% in autopsies,³ being asymptomatic only in 5%–7%.⁴ However, because the affection is exclusively splenic, as was seen in our patient, it is extraordinarily infrequent, and we consider it relevant to present because the correlation between clinical, imaging and histological testing has been seldom reported in previous case publications.^{5,6}

Ethical disclosures

Protection of human and animal subjects. The authors declare that no experiments were performed on humans or animals for this study.

Confidentiality of data. The authors declare that they have followed the protocols of their work center on the publication of patient data.

Right to privacy and informed consent. The authors declare that no patient data appear in this article.

Conflict of Interest

The authors state no conflicts of interest.

References

1. Iannuzzi MC, Rybicki BA, Teirstein AS. Sarcoidosis. *N Engl J Med.* 2007;357:2153–65.
2. Vardhanabhuti V, Venkatanarasimha N, Bhatnagar G, Maviki M, Iyengar S, Adams WM, et al. Extra-pulmonary manifestations of sarcoidosis. *Clin Radiol.* 2012;67:263–76.
3. Iwai K, Tachibana T, Takemura T, Matsui Y, Kitaichi M, Kawabata Y. Pathological studies on sarcoidosis autopsy. I. Epidemiological features of 320 cases in Japan. *Acta Pathol Jpn.* 1993;43:372–6.
4. Zia H, Zemon H, Brody F. Laparoscopic splenectomy for isolated sarcoidosis of the spleen. *J Laparoendosc Adv Surg Tech A.* 2005;15:160–2.
5. Kay S. Sarcoidosis of the spleen; report of 4 cases with a 23-year follow up in one case. *Am J Pathol.* 1950;26:427–43.
6. Wang YT, Han YP, Xu H, Chen HZ, Sheng K, Li Q. Splenic sarcoidosis: a case report and review of literature. *Zhonghua Nei Ke Za Zhi.* 2009;48:367–70.