



Images in Clinical Rheumatology

Ultrasonography as a Diagnostic Tool for Skin Metastasis of a Prostate Adenocarcinoma[☆]



Ecografía en el diagnóstico de metástasis cutánea de adenocarcinoma de próstata

Hèctor Corominas,* Paula Estrada, Delia Reina, Dacia Cerdà-Gabaroí

Servei de Reumatologia, Hospital Moisès Broggi/Hospital General de L'Hospitalet, Consorci Sanitari Integral (CSI), Sant Joan Despí/L'Hospitalet, Barcelona, Spain

ARTICLE INFO

Article history:

Received 20 January 2015

Accepted 2 March 2015

Available online 8 December 2015

Case Report

The patient was a 53-year-old man with no significant medical history. He presented with a painless mass in anterior forearm, reporting no previous injury. Physical examination confirmed the presence of a hard, immobile mass measuring less than 1 cm. He came to the rheumatologic examination room, where he underwent soft tissue ultrasound (Toshiba Aplio^{®300}). A round mass measuring less than 1 cm was observed. It was iso/hypoechoic on gray scale images, was moderately well-defined, and was joined to a vessel that fed it (Fig. 1). On color Doppler, there was high echo intensity throughout the entire lesion, more intense on the periphery (Figs. 2 and 3). As there were findings that raised suspicion, such as heterogeneity, the marked vascularity and the marked Doppler signal (grade 3), magnetic resonance imaging was performed. This study revealed a round, well-defined form measuring 1 cm, with hyperintensity on T1-weighted images, which pointed to a metastatic lesion (Fig. 4).

Diagnosis and Course

While the clinical picture was being completed on the basis of the constitutional symptoms, a biopsy of the skin lesion was carried out. The analysis of 4 tissue cores, measuring 0.4, 1.2, 1 and 0.9 cm in length, respectively, and 0.1 cm in diameter,

[☆] Please cite this article as: Corominas H, Estrada P, Reina D, Cerdà-Gabaroí D. Ecografía en el diagnóstico de metástasis cutánea de adenocarcinoma de próstata. Reumatol Clin. 2016;12:54–56.

* Corresponding author.

E-mail address: vancor@yahoo.com (H. Corominas).

confirmed the presence of infiltration of the fibromuscular tissue by prostate-specific antigen (PSA)-positive metastatic adenocarcinoma cells. In addition, laboratory tests revealed a PSA level of 13 ng/mL, and transrectal ultrasound-guided biopsy of the prostate confirmed prostatic adenocarcinoma with distant cutaneous metastasis.

Comment/discussion

After skin cancer, adenocarcinoma of the prostate represents the most common type of cancer in men and the second most common cause of death due to cancer. Death is often associated with metastatic disease which, in the case of prostatic adenocarcinoma, typically involves the bones and lymph nodes. It rarely affects the skin.^{1,2} Although the medical history and physical examination, laboratory tests and routine pathology may indicate the prostate as the origin of the metastatic disease, immunohistochemistry for PSA is often used to aid in establishing the diagnosis.³

This case is useful in clinical practice in rheumatology because: (1) the images can raise suspicion for the seriousness of a nodular lesion smaller than 1 cm because of its vascularity and heterogeneity; (2) it highlights the importance of the rheumatologic examination room in the diagnosis of soft tissue tumors (benign or malignant) that rheumatologists should not disregard; (3) cutaneous metastases of prostatic adenocarcinoma are very uncommon and, in this case, soft tissue ultrasound helped to orientate the extensive study of the neoplastic disease; and (4) it is essential to identify the lesions on the basis of their ultrasonographic appearance and, when in doubt, the study should be extended to include magnetic resonance imaging.⁴

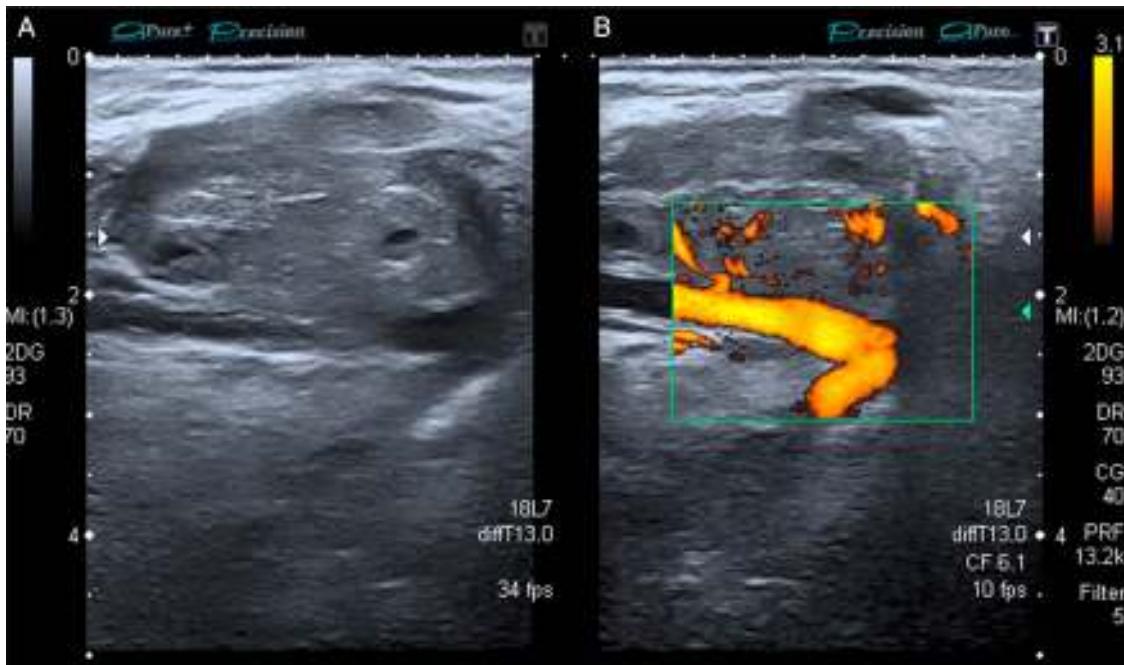


Figure 1. (A) Gray scale iso/hypoechoic image of a round, heterogeneous and moderately well-defined lesion. (B) Image with Doppler signal activated showing the vessel that feeds the metastatic lesion.

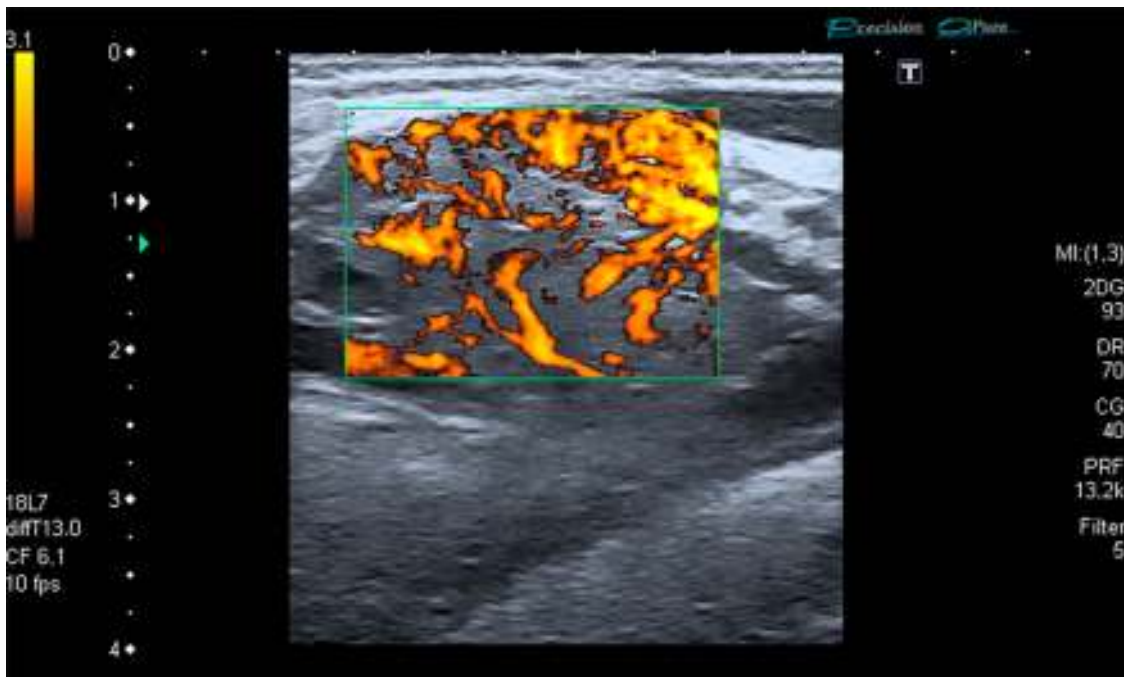


Figure 2. Color Doppler image showing the hypervascularity of the highly heterogeneous lesion, findings that rule out malignancy.

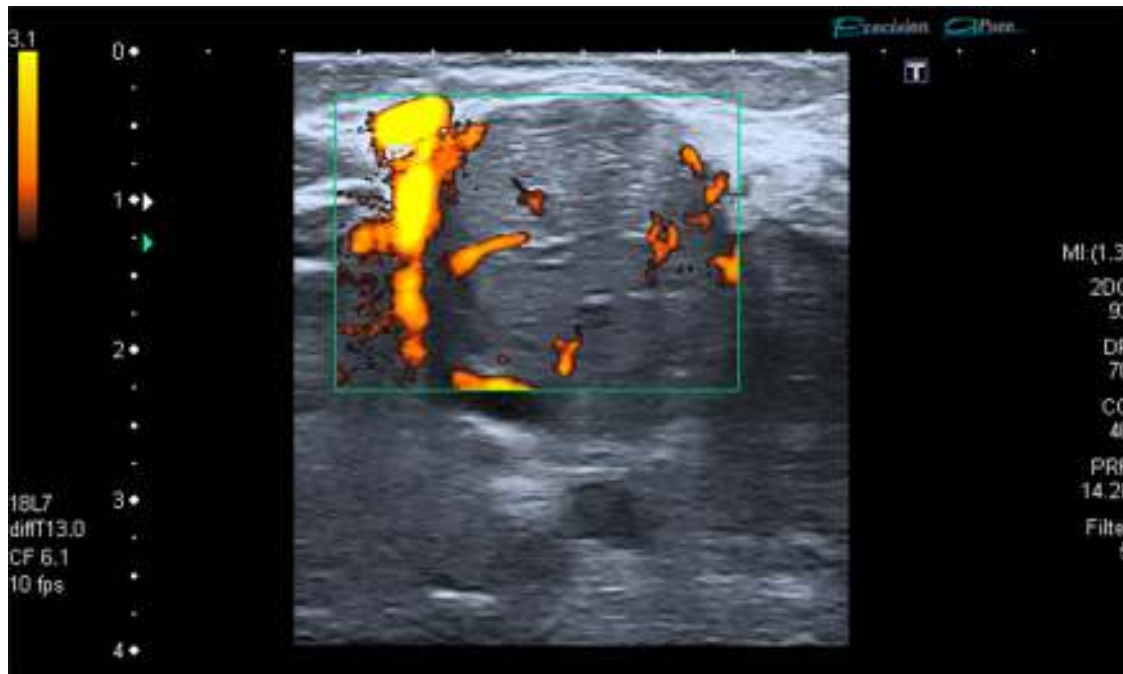


Figure 3. Doppler image showing a round form and grade 1 signal in the lesion and hypervascularity due to an adjacent vessel.

Ethical Disclosures

Protection of human and animal subjects. The authors declare that no experiments were performed on humans or animals for this study.

Confidentiality of data. The authors declare that they have followed the protocols of their work center on the publication of patient data.

Right to privacy and informed consent. The authors declare that no patient data appear in this article.

Conflicts of Interest

The authors declare they have no conflicts of interest.

References

1. Rattanasirivilai A, Kurban A, Lenzy YM, Yaar R. Cutaneous metastasis of prostatic adenocarcinoma: a cautionary tale. *J Cutan Pathol.* 2011;38:521–4.
2. Riley S, Wah T. Cutaneous metastasis of esophageal adenocarcinoma with an unusual presentation. *J Clin Ultrasound.* 2007;35:289–92.
3. He D, Zeng J, Li X, Wu K, Wu D, He H, et al. Priapism as the initial manifestation of a penile and lower limb cutaneous metastasis of prostate adenocarcinoma with low serum PSA level. *J Androl.* 2012;33:1160–4.
4. Nalbant S, Corominas H, Hsu B, Chen LX, Schumacher HR, Kitumnuaypong T. Ultrasonography for assessment of subcutaneous nodules. *J Rheumatol.* 2003;30:1191–5.

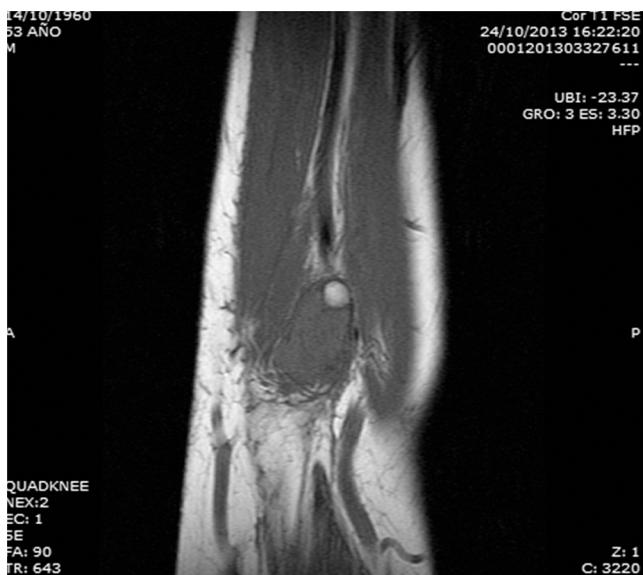

Figure 4. T1-weighted magnetic resonance image (sagittal plane) of the forearm. Round, well-defined iso/hyperintense mass in the muscle of right forearm, with chemical shift artifact with fat saturation.