

## Letters to the Editor

### Polyostotic fibrous dysplasia. Important facts that the rheumatologist should know<sup>☆</sup>



#### Displasia fibrosa poliostrófica. Datos importantes que el reumatólogo debe conocer

To the Editor,

Fibrous dysplasia is a monostotic or polyostotic bone growth disorder caused by mosaicism involving the mesenchymal tissue. The presenting signs include pain and spontaneous fractures. Last year, Meneses et al. described a case in this journal<sup>1</sup> and, in this letter, we report another.

A year ago, a 36-year-old man was referred to us with pain and a significant increase in his alkaline phosphatase levels: 658 U/l (normal range: 40–130). He had never been examined by a rheumatologist, despite the fact that he had been diagnosed as having polyostotic fibrous dysplasia at the age of 5 years. He had undergone cranioplasty twice for cranial volume reduction and decompression surgery on another 2 occasions to relieve pressure on the left optic nerve. He had had a clavicular fracture and, shortly before our first encounter, fracture of left femur, without previous trauma, but with the fracture line over preexisting osseous cystic lesions. The examination revealed a head circumference of 67 cm, hypertelorism and thoracolumbar scoliosis, with a lump in left costal region that was painful on palpation. Moreover, he presented with right-sided coxa vara and leg length discrepancy. The patient was treated with pamidronate (180 mg/iv every 6 months), which relieved his symptoms and reduced his alkaline phosphatase level by over 20% to 390 U/l.

This disease is caused by a point mutation (activation of the *GNAS1* gene) in part of the bone tissue.<sup>2,3</sup> It is characterized by the coexistence of cells having the genetic alteration and normal cells (mosaicism). This mutation induces an expansion of osteoprogenitor cells and their accumulation in the bone marrow spaces, provoking localized hematopoietic tissue loss and bone marrow fibrosis. The collagen shows changes in orientation and biochemical composition. Markers of bone remodeling may be elevated, as occurred in our patient. It is usually asymptomatic and the diagnosis is incidental, although there may be pain, swelling, deformity and/or neurological involvement. Seventy percent of the cases are diagnosed before the age of 30 years.<sup>4</sup> The dysplastic tissue is highly vascularized, and is prone to spontaneous bleeding with subsequent cyst formation. The bones widen and the cortical bone thins, and spontaneous fractures can occur as a complication when the condition affects weight-bearing long bones. The presence

of intralesional cystic lesions measuring over 2.5 cm in diameter increases the risk.<sup>5</sup>

It can affect several adjoining cranial bones, obliterating the sutures, compress cranial nerve pairs at their exit or affect structures of the middle ear.

The changes observed in plain radiography are variable, depending on the proportion of osseous and fibrous components of the lesion and on its location.

Treatment depends on the presenting signs, and ranges from a wait and see attitude, curettage of the lesions, correction of the deformities and nerve decompression,<sup>5</sup> to treatment with bisphosphonates in polyostotic forms with active bone remodeling markers. In the monostotic forms, complete ablation of the lesion prevents recurrence. The rate of recurrences after curettage and grafting is high, especially in children. Thus, its use on a routine basis is not recommended, and it is reserved for the decompression of nerve structures.

To this day, there is no curative treatment for this disease. Uncontrolled studies have demonstrated the utility of pamidronate,<sup>6</sup> which improves even the radiological changes and the physical aspect of the patient,<sup>7</sup> basically when the facial skeleton is affected. The use of bisphosphonates has been shown to reduce the painful symptoms, with a decrease in remodeling markers and an increase in bone mineral density, and even results in the filling of cysts and cortex thickening.<sup>8</sup> In another study, a reduced incidence of fractures was observed.<sup>9</sup>

A pediatric patient treated with denosumab because of the inefficacy of the bisphosphonates developed severe secondary effects.<sup>10</sup>

Chemotherapy and radiotherapy are not effective, and the latter can facilitate fractures and predispose the patient, albeit rarely (0.4%), to malignant transformation.<sup>4</sup>

We consider notable the delay in the referral of this patient to our department, despite the elevation of his alkaline phosphatase levels and his pain, a circumstance that suggests a lack of knowledge of the possibility of using beneficial drug therapies. The physicians who may at some time treat these patients should be aware of the risk of secondary fractures in weight-bearing bones when cystic lesions greater than 2.5 cm in diameter are observed.<sup>4</sup>

## References

1. Meneses CF, Egües A, Uriarte M, Belzuneguij. Displasia fibrosa poliostrófica: presentación de un caso. *Reumatol Clin*. 2014;10:413–5.
2. Bianco P, Riminucci M, Majolagbe A, Kuznetsov SA, Collins MT, Mankani MH, et al. Mutations of the *GNAS1* gene, stromal cell dysfunction, and osteomalacic changes in non-McCune-Albright fibrous dysplasia of bone. *J Bone Miner Res*. 2000;15:120–8.
3. Alonso G, Muñoz-Torres M. Fibrous dysplasia of bone in a young male. *Endocrinol Nutr*. 2009;56:195–200.
4. DiCaprio MR, Enneking WF. Fibrous dysplasia. Pathophysiology, evaluation, and treatment. *J Bone Joint Surg Am*. 2005;87:1848–64.
5. Ippolito E, Bray EW, Corsi A, de Maio F, Exner UG, Robey PG, et al. Natural history and treatment of fibrous dysplasia of bone: a multicenter clinicopathologic study

<sup>☆</sup> Please cite this article as: Turrión Nieves AI, Martín Holguera R, Romero Bogado ML, Sánchez-Atrio AI. Displasia fibrosa poliostrófica. Datos importantes que el reumatólogo debe conocer. *Reumatol Clin*. 2015;11:403–404.

promoted by the European Pediatric Orthopaedic Society. *J Pediatr Orthop B*. 2003;12:155–77.

6. Chapurlat RD, Delmas PD, Liens D, Meunier PJ. Long-term effects of intravenous pamidronate in fibrous dysplasia of bone. *J Bone Miner Res*. 1997;12:1746–52.
7. Kos M, Luczak K, Godzinski J, Klempous J. Treatment of monostotic fibrous dysplasia with pamidronate. *J Craniomaxillofac Surg*. 2004;32:10–5.
8. Chapurlat RD, Huguely P, Delmas PD, Meunier PJ. Treatment of fibrous dysplasia of bone with intravenous pamidronate: long-term effectiveness and evaluation of predictors of response to treatment. *Bone*. 2004;35:235–42.
9. Lala R, Matarazzo P, Andreo M, Marzari D, Bellone J, Corrias A, et al. Bisphosphonate treatment of bone fibrous dysplasia in McCune-Albright syndrome. *J Pediatr Endocrinol Metab*. 2006;19:583–93.
10. Boyce AM, Chong WH, Yao J, Gafni RI, Kelly MH, Chamberlain CE, et al. Denosumab treatment for fibrous dysplasia. *J Bone Miner Res*. 2012;27:1462–70.

Ana Isabel Turrión Nieves,<sup>a,b,\*</sup> Rafael Martín Holguera,<sup>b</sup> María Liz Romero Bogado,<sup>a</sup> Ana Isabel Sánchez-Atrio<sup>a</sup>

<sup>a</sup> Servicio de ESI-Reumatología, Hospital Universitario Príncipe de Asturias, Departamento de Medicina especialidades médicas, Alcalá de Henares, Madrid, Spain

<sup>b</sup> Departamento de Cirugía y Ciencias Médico Sociales, Unidad docente de Anatomía y Embriología Humanas, Universidad de Alcalá de Henares, Alcalá de Henares, Madrid, Spain

\* Corresponding author.

E-mail address: [anaturrion@hotmail.com](mailto:anaturrion@hotmail.com) (A.I. Turrión Nieves).

## Amyloid Goiter as an Initial Manifestation of Systemic Amyloidosis<sup>☆</sup>



### Bocio amiloide como manifestación inicial en amiloidosis sistémica

To the Editor,

Infiltration of the thyroid gland by amyloid is a common phenomenon. However, the development of goiter and hyperthyroidism due to amyloid deposition is rare, even in patients with known amyloidosis.<sup>1,2</sup> The detection of amyloid goiter as the first manifestation of secondary systemic amyloidosis is exceptionally rare in the literature. That circumstance has led us to present this clinical report.<sup>3,4</sup>

The patient was a 41-year-old man with a history of myelomeningocele that had been treated surgically at birth, long-standing postoperative sacral ulcer and neurogenic bladder without previously known nephropathy. He was admitted to the hospital with a large goiter and a thyroid storm. He was diagnosed as having Graves–Basedow disease. After medical therapy, the decision was made to perform thyroidectomy, which resulted in the incidental histological finding of amyloid goiter. The supplemental studies aided in establishing a diagnosis of AA systemic amyloidosis, secondary to long-standing indolent sacral ulcer and stage 3 kidney disease.

Amyloid goiter is defined as the presence of an extracellular amyloid-like material that produces clinical enlargement of the gland. These depositions show the characteristic Congo red staining (Fig. 1), and also exhibit green birefringence under polarized light microscopy.<sup>4,5</sup>

The clinical picture is characterized by a rapid, progressive increase in the thyroid volume and a bilobed structure, which is what makes surgery the treatment of choice in these patients.<sup>5,6</sup>

It is important to have previously ruled out a malignant process, such as anaplastic carcinoma or lymphoma. For this purpose, fine-needle aspiration biopsy of the goiter is a highly useful technique.<sup>5,6</sup>

The patients may develop symptoms related to the neighboring structures, such as dysphagia, dyspnea and/or dysphonia. Thyroid function is usually normal. However, in a minority of the cases, coexistence of hypothyroidism or hyperthyroidism is detected.<sup>7</sup>

Amyloidosis comprises a group of diseases characterized by deposition of a protein called amyloid in the extracellular matrix.

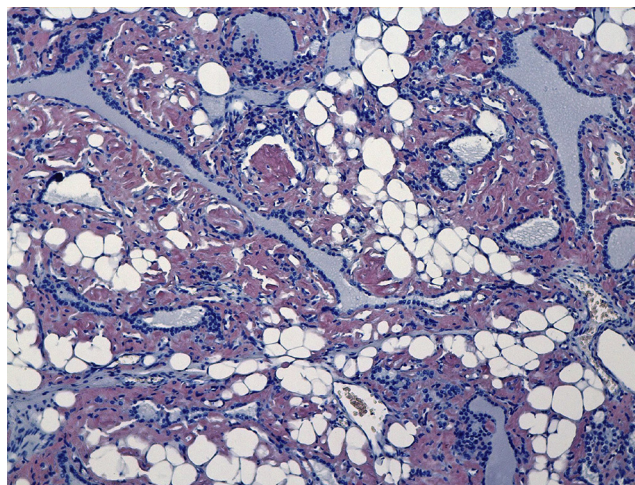


Fig. 1. Amyloid depositions showing the characteristic Congo red staining.

The most common forms of systemic amyloidosis are primary, involving light chains, and secondary, due to chronic diseases.<sup>5,8</sup> In autopsy studies, amyloid is found in the thyroids of 80% of the patients with secondary amyloidosis and 50% of those with the primary form.<sup>6</sup>

In conclusion, amyloid goiter should be suspected in those patients who have a long-standing, chronic inflammatory disease or process in whom rapid, progressive, bilobed growth of the thyroid gland is detected. Fine-needle aspiration biopsy will aid in establishing the definitive diagnosis and in ruling out other processes that could be malignant.

### Conflicts of Interest

The authors declare that they have no conflicts of interest.

### References

<sup>☆</sup> Please cite this article as: Cabreas Gómez MC, González Cabrera N, Gómez González C, Bergara Elorza S. Bocio amiloide como manifestación inicial en amiloidosis sistémica. *Reumatol Clin*. 2015;11:404–405.

1. Belmatoug N. Amylose inflammatoire. *La Revue du Practicien*. 1997;47:1777–82.
2. Kapadia HC, Desai RI, Desai IM, Parikh NR. Amyloid goiter a case report. *Indian J Pathol Microbiol*. 2001;44:147–8.