

Unilateral lymphedema as first presentation of sarcoidosis



Linfedema unilateral como primera presentación de sarcoidosis

To the Editor:

Sarcoidosis is a systemic disease characterized by the involvement of multiple tissues and organs with a non-calcified granuloma reaction, which is not yet well understood.¹ Although the exact pathogenesis of sarcoidosis is not known, it is currently accepted that, in genetically susceptible individuals, it is caused through alteration of the cellular immune response after exposure to an environmental, occupational or infectious agent.² It is presented with bilateral hilar lymphadenopathies, infiltrations in the lung, skin and eye lesions. The pathognomonic histological finding is the presence of non-calcified granulomas.³ These granulomas may form in almost any organ in the body. Sarcoidosis is one of the most important causes of granulomatous lymphadenitis.⁴ Development of lymphedema is the result of the involvement of lymph nodes and obstruction of lymphatic drainage. In this report we present a female case of sarcoidosis and ankylosing spondylitis co-occurrence that applied to our clinic with widespread lymphedema on her left leg. The patient is 50-year-old female who presented to our clinic with lymphedema and swelling started from the left inguinal region and spread to the whole left extremity. She had also complaints of inflammatory low back pain going on for the last 15 years. In her physical examination there was widespread lymphedema on her left foot, lymphadenopathies on her left inguinal region, restriction on her neck and hip range of motion and bilateral Fabere/Fadir test positivity. Laboratory studies showed erythrocyte sedimentation rate and C-reactive protein elevation, serum calcium and angiotensin converting enzyme (ACE) elevation and chronic disease anemia. There were widespread conglomerate lymphadenopathies in the left inguinal region according to the soft tissue ultrasonography examination. Thorax CT showed paratracheal, mediastinal and bilateral hilar lymphadenopathies (Fig. 1). Sacroiliac joint radiography showed bilateral joint space narrowing and sclerosis. Sacroiliac MRI scan was reported as chronic sacroiliitis with the presence of active lesions (Fig. 2). Genetic analysis showed that HLA-B27 was positive. Biopsy of the inguinal lymphadenopathies revealed granulomatous lymphadenitis and non-calcified granulomas. *M. tuberculosis* was not detected owing to her PPD was negative, acid-fast stain on tissue

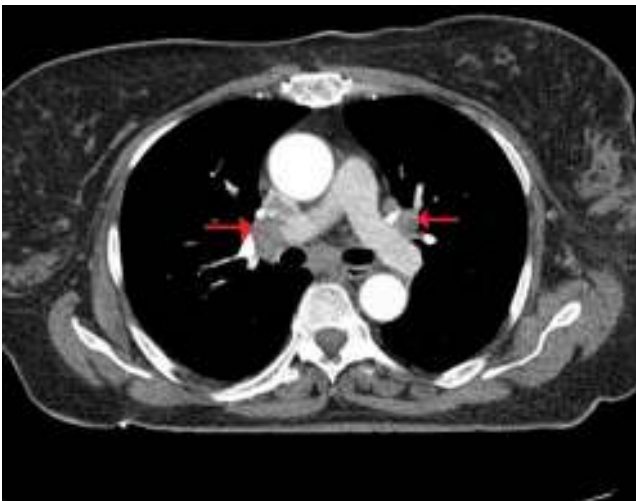

Fig. 1. Torax computed tomography showed bilateral hilar and mediastinal lymphadenopathies.

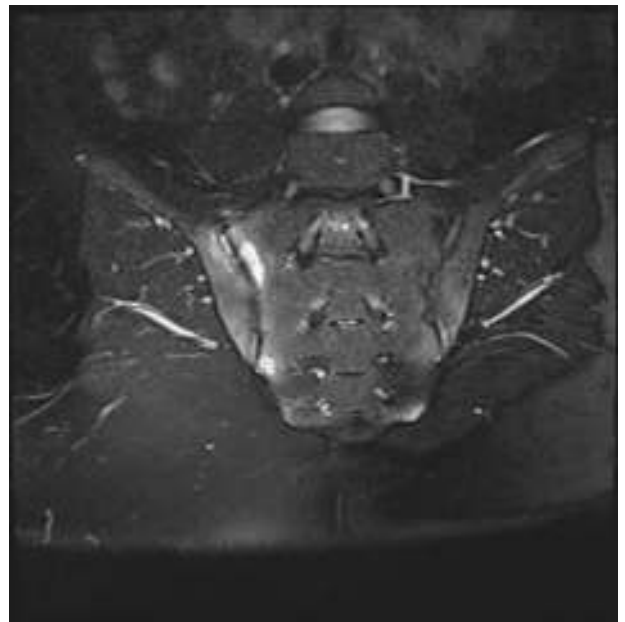


Fig. 2. Sacroiliac joints MRI showed bilateral sacroiliitis.

samples from the biopsy was negative. According to clinical, laboratory, histopathological and radiological findings, we diagnosed our patient as sarcoidosis and ankylosing spondylitis, then she received 40 mg of prednisolone per day. Lower extremity edema, inguinal lymph nodes and clinical complaints regressed during the follow up period. Control erythrocyte sedimentation rate and C-reactive protein were normal. Control thorax CT showed significant diametric regression of the hilar and bilateral mediastinal lymph nodes. Sarcoidosis may imitate different rheumatologic diseases and/or may be seen with them.⁵ Sacroiliac joint involvement is a major joint involvement of sarcoidosis and it may be seen in 6–14% of the patients which causes the diagnostic confusion with ankylosing spondylitis.^{6,7} HLA-B27 is helpful for the differential diagnosis besides the major method is the histopathological evaluation. Even if it is rare; like in our case, these two diseases may occur together. However this co-occurrence is not because of a common etiopathogenesis, but because of an incidental association. Granulomatous lymphadenitis is an important finding of sarcoidosis.⁸ The lymphadenopathies that develop in different regions cause organ and system dysfunctions. There are some reported sarcoidosis patients in the literature that were presented with lymphedema. Putkonen et al. has identified a female case that started with lower extremity lymphedema and they reported significant regression after treatment with corticosteroids.⁹ Nathan et al. reported a 32-year-old black female case that suffered from foot lymphedema going on for the last 11 years.¹⁰ As in our case, the lymphedema development on these patients feet is because of the obstruction of the lymphatic drainage due to the involvement of the lymph nodes. Chronic, asymmetric feet edema presentation without venous obstruction should always suggest the probability of sarcoid lymphadenopathy for early diagnosis and treatment of this clinical condition. In conclusion, granulomatous lymphadenitis is an important clinical presentation of sarcoidosis. Different clinical findings may occur because of the compression of the conglomerated lymph nodes. For patients presented with compressive peripheral lymphadenopathy, sarcoidosis is a disease that should be kept in mind.

References

1. Newman LS, Rose CS, Maier LA. Sarcoidosis. *N Engl J Med.* 1997;336:1224–34.

2. Hofmann S, Franke A, Fischer A, Jacobs G, Nothnagel M, Gaede KI, et al. Genome-wide association study identifies ANXA11 as a new susceptibility locus for sarcoidosis. *Nat Genet.* 2008;40:1103-6.
3. Kobak S, Sever F, Sivriköz ON, Orman M. Sarcoidosis: is it only a mimicker of primary rheumatic disease? A single center experience. *Ther Adv Musculoskelet Dis.* 2014, February;6:3-7.
4. Chatham W. Rheumatic manifestations of systemic disease: sarcoidosis. *Curr Opin Rheumatol.* 2010;22:85-90.
5. Pettersson T. Rheumatic features of sarcoidosis. *Curr Opin Rheumatol.* 1998;10:73-8.
6. Erb N, Cushley MJ, Kassimos DG, Shave RM, Kitis GD. An assessment of back pain and the prevalence of sacroiliitis in sarcoidosis. *Chest.* 2005;127:192-6.
7. Kobak S, Sever F, Ince O, Orman M. The prevalence of sacroiliitis and spondyloarthritis in patients with sarcoidosis. *Int J Rheumatol.* 2014;2014:289454.
8. Tomoda F, Oda Y, Takata M, Futamura A, Fujii N, Inoue H, et al. A rare case of sarcoidosis with bilateral leg lymphedema as an initial symptom. *Am J Med Sci.* 1999, December;318:413-4.
9. Putkonen T, Hannuksela M. Chronic lymphoedema of the lower extremities in sarcoidosis. *Duodecim.* 1967;83:86-8.
10. Nathan MP, Pinsker R, Chase PH, Elguezabel A. Sarcoidosis presenting as lymphedema. *Arch Dermatol.* 1974;109:543-4.

Senol Kobak,^{a,*} Ahmet Karaarslan,^b Hakan Aycan^b

^a Sifa University, Faculty of Medicine, Department of Rheumatology, Turkey

^b Sifa University, Faculty of Medicine, Department of Orthopedics, Turkey

* Corresponding author.

E-mail address: senolkobak@gmail.com (S. Kobak).

Calcinosis in Hands and Antisynthetase Syndrome Without Muscle Involvement[☆]



Calcinosis en manos y síndrome antisintetasa sin afectación muscular

Dear Editor,

The antisynthetase syndrome, defined in 1990,¹ is characterized by the presence of antisynthetase antibodies, inflammatory myopathy, interstitial lung disease, mechanic's hands, arthritis, fever and Raynaud's phenomenon.

We present the case of a 63-year-old housewife who had a history of type 2 diabetes, hypertension and dyslipidemia, with good control, for which she was taking metformin, enalapril and atorvastatin. There was nothing notable in her family history, she did not consume harmful substances and was not contact with animals. She was referred to us with a 2-year history of polyarthralgia at irregular intervals, with predominantly mechanical symptoms, in small joints of the hands and feet. There was no swelling, but she reported having morning stiffness in the hands that lasted approximately 2 h. In the review of organ systems for her medical history, she mentioned the development of a dry cough and dyspnea on moderate exertion since the onset of the arthralgias, as well as the appearance of Raynaud's phenomenon in her hands, without vasculitic lesions, one year earlier. Her appetite and weight had not been affected and she had no fever. Physical examination showed that her general health was good, with resting eupnea and no evidence of adenopathy or skin lesions; auscultation of heart and lungs revealed Velcro crackles down to middle lung fields, but there were no other findings; on rheumatological examination, she was found to experience pain on flexion and extension of both wrists, without synovitis, and small, cold, painless, semi-indurated lesions at some metacarpophalangeal and interphalangeal joints of the hands (Fig. 1); in the rest of the joint areas, there was no pain, limitations of the range of movement or swelling. The results of the neurovascular examination were normal, with no pain in response to pressure on the limb musculature or functional disability. The laboratory findings were as follows: complete blood count, blood biochemistry, acute phase reactants, aldolase, creatine kinase, thyroid hormones and parathyroid hormone were within normal range; the autoimmunity study only revealed positivity for anti-histidyl-tRNA synthetase antibodies (anti-Jo-1) at a high titer (rheumatoid

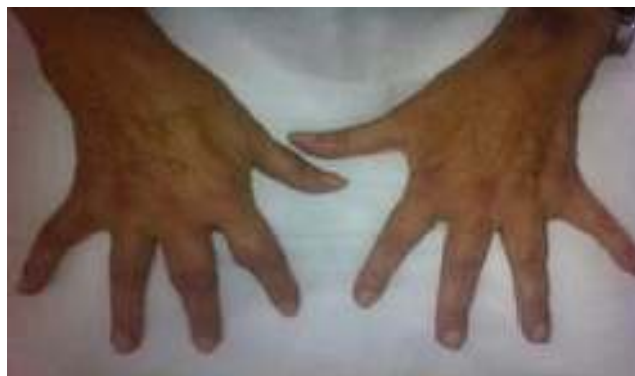

Fig. 1. Synovitis in several proximal metacarpophalangeal and interphalangeal joints.

factor and anti-cyclic citrullinated peptide, antinuclear, anti-U1-RNP, anti-Ro anti-cytoplasmic and anti-endomysium antibodies were all normal). The electromyographic study of upper and lower limbs detected no evidence of inflammatory myopathy. The imaging studies performed included: radiographies of elbows, hands (Fig. 2), pelvis, knees and feet. The only abnormal findings were calcium deposits in periarticular areas of the hands, together with osteopenia, with no evidence of erosion of any joint. High-resolution radiography and chest tomography revealed a reticular pattern compatible with interstitial pneumonia. Lung biopsy was performed, and the final diagnosis was usual fibrosing interstitial

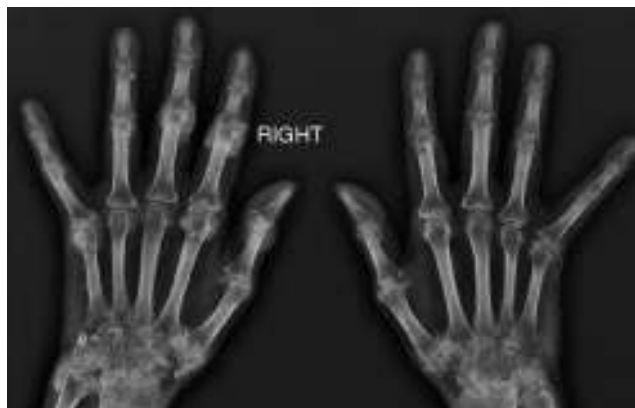

Fig. 2. Amorphous periarticular calcifications with polylobulated margins, without bone destruction, in the areas of different joints.

[☆] Please cite this article as: García Rodríguez C, Salvatierra Ossorio J, Morales Gardido P, Raya Álvarez EG. Calcinosis en manos y síndrome antisintetasa sin afectación muscular. *Reumatol Clin.* 2016;12:60-61.