



Images in Clinical Rheumatology

Metallosis as a Cause of Pain and Inflammation in a Patient With a Knee Replacement: A Case Description[☆]



Metallosis como causa de dolor e inflamación en un paciente con prótesis de rodilla: descripción de un caso

David Pescador,^a Ismael Calero-Paniagua,^{b,c,*} María Dolores Sánchez-González,^{b,c} Carlos Montilla^{b,c}

^a Servicio de Traumatología, Hospital Universitario de Salamanca, Salamanca, Spain

^b Servicio de Reumatología, Hospital Universitario de Salamanca, Salamanca, Spain

^c Instituto de Investigación Biomédica de Salamanca (IBSAL), Salamanca, Spain

ARTICLE INFO

Article history:

Received 7 February 2015

Accepted 1 April 2015

Available online 23 February 2016

A 72-year-old woman who had undergone unicompartmental arthroplasty in right knee 12 years earlier, presented with a 6-month history of pain in that knee, in the absence of fever or systemic symptoms. On physical examination, the knee was found to be swollen. Radiography revealed a prosthesis in the medial compartment, which remained unchanged since the partial knee replacement (Fig. 1). Arthrocentesis yielded a dark fluid (Fig. 2) with 150 white blood cells/ μ L (75% polymorphonuclear cells), glucose level at 90 mg/dL and proteins at 2 mg/dL. Culture of the joint fluid was negative. With the suspicion of metallosis, the patient was referred to the orthopedics department and underwent total knee replacement. The pathological study of a specimen of synovial tissue showed macrophages with a blackish pigment in the cytoplasm and lymphocytes (Figs. 3 and 4). At the present time, the patient is asymptomatic.

Metallosis is defined as a corrosion due to the erosion of metallic components, which produces particles that induce a hypersensitivity reaction. It is generally asymptomatic and the development of pain or stiffness is due to the secondary loosening of the prosthesis.¹ It may be suspected when lobulated osteolytic areas, with or without increased volume of the adjacent soft tissues, are detected on plain radiography. The differential diagnosis should include aseptic dislocation of the prosthesis and septic arthritis.² Macroscopic examination shows a black pigmentation of the joint,

together with a dark-colored synovial fluid. A microscopic study reveals metallic particles, either free or engulfed by macrophages, with a lymphocytic infiltrate that suggests an immune response.³ Treatment consists in replacement of the prosthesis and performance of synovectomy for the purpose of eliminating the metallic particles.³

Since it is not uncommon for patients who have undergone arthroplasty to consult their rheumatologists because of pain, metallosis must be taken into account. On the other hand, we should point out that this condition is extremely rare in unicompartmental knee arthroplasties.⁴

Ethical disclosures

Protection of human and animal subjects. The authors declare that the procedures followed were in accordance with the regulations of the relevant clinical research ethics committee and with those of the Code of Ethics of the World Medical Association (Declaration of Helsinki).

Confidentiality of data. The authors declare that they have followed the protocols of their work center on the publication of patient data.

Right to privacy and informed consent. The authors have obtained the written informed consent of the patients or subjects mentioned in the article. The corresponding author is in possession of this document.

[☆] Please cite this article as: Pescador D, Calero-Paniagua I, Sánchez-González MD, Montilla C. Metallosis como causa de dolor e inflamación en un paciente con prótesis de rodilla: descripción de un caso. Reumatol Clin. 2016;12:112–113.

* Corresponding author.

E-mail address: ismaelcaleropaniagua@yahoo.es (I. Calero-Paniagua).

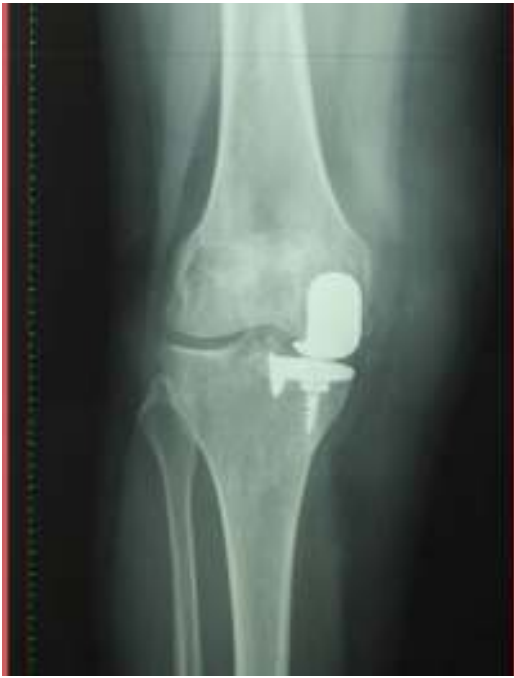

Fig. 1. Anteroposterior radiograph of right knee showing the unicompartmental prosthesis.

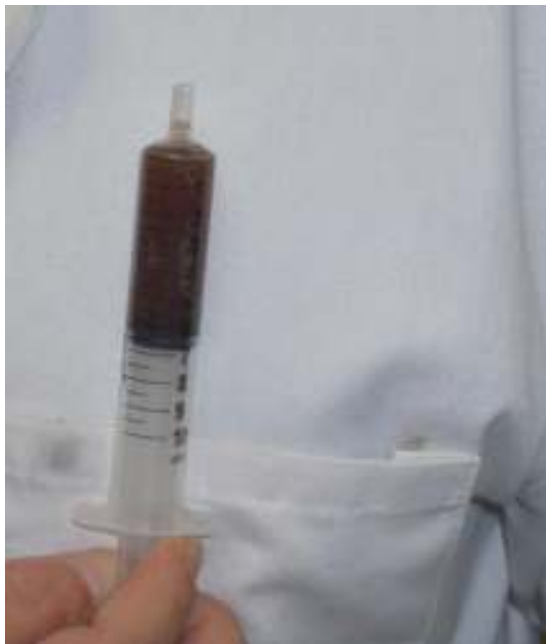

Fig. 2. Joint fluid obtained during arthrocentesis.

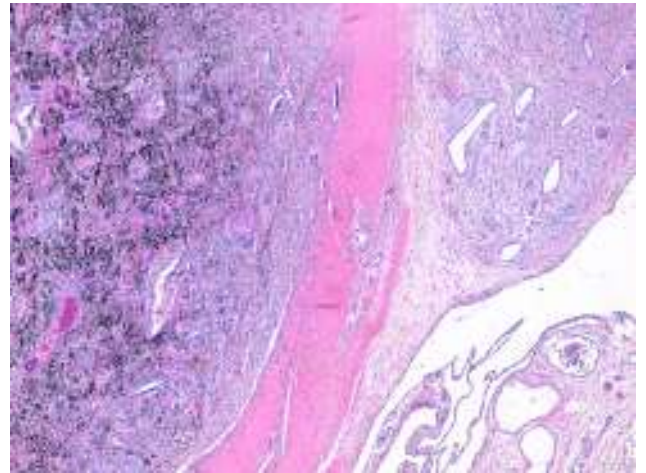


Fig. 3. Synovial biopsy: black pigment infiltrating the synovial tissue.

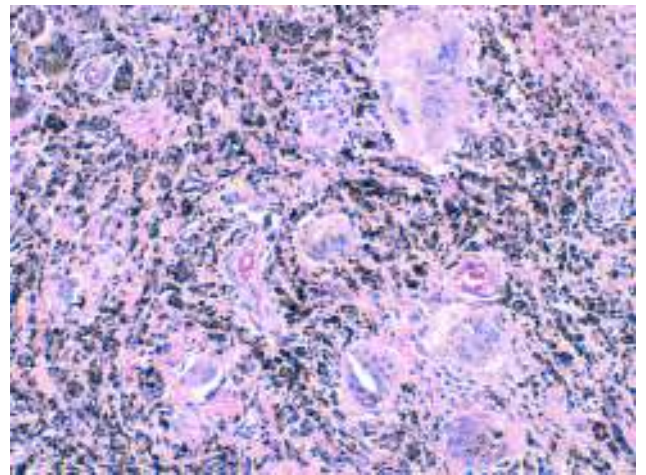


Fig. 4. Synovial biopsy: macrophages loaded with metallic pigments and lymphocytic infiltrate.

Conflicts of interest

The authors declare they have no conflicts of interest.

References

1. Wapner KL. Implications of metallic corrosion in total knee arthroplasty. *Clin Orthop Relat Res.* 1991;271:12–20.
2. McGovern TF, Moskal JT. Radiographic evaluation of periprosthetic metallosis after total knee arthroplasty. *J South Orthop Assoc.* 2002;11:18–24.
3. Bullough PG. Metallosis. *J Bone Joint Surg Br.* 1994;76:687–8.
4. Arredondo J, Worland RL, Jessup DE, Angles F. Midterm results in metal-backed patella revisions for metallosis. *Am J Orthop.* 1997;26:598–600.