



Sociedad Española  
de Reumatología -  
Colegio Mexicano  
de Reumatología

# Reumatología Clínica

www.reumatologiaclinica.org



## Case report

### Acute Pneumonitis in a Patient With Adult-Onset Disease After Tocilizumab Treatment With Good Response to Anakinra<sup>☆</sup>



Clara Sangüesa Gómez,<sup>a,\*</sup> Bryan Josué Flores Robles,<sup>a</sup> Beatriz Jara Chinarro,<sup>b</sup> María Espinosa Malpartida,<sup>a</sup> Carmen Barbadillo Mateos<sup>a</sup>

<sup>a</sup> Servicio de Reumatología, Hospital Universitario Puerta de Hierro, Majadahonda, Madrid, Spain

<sup>b</sup> Servicio de Neumología, Hospital Universitario Puerta de Hierro, Majadahonda, Madrid, Spain

#### ARTICLE INFO

##### Article history:

Received 18 April 2015

Accepted 21 August 2015

Available online 21 August 2016

##### Keywords:

Adult-onset Still's disease

Acute pneumonitis

Tocilizumab

Methotrexate

#### ABSTRACT

Pulmonary involvement in the form of acute pneumonitis in adult-onset Still's disease (AOSD) is an uncommon manifestation, with few cases reported in the literature. We report the case of a 61-year-old male with 3 years of AOSD evolution, treated with methotrexate (MTX) and half-dose corticosteroids, which debuted with symptoms of fever, dyspnea and dry cough after 3 weeks of receiving the first dose of tocilizumab (TCZ). In the follow-up study showed leukocytosis with left shift, elevated serum ferritin and C-reactive protein standard. The chest CT scan showed ground-glass pattern predominantly in central and upper lobes and the BAL shows an increase in the percentage of lymphocyte with normal subpopulations and negative cultures. MTX and TCM were suspended, prednisone was increased to 30 mg/day and within a week Anakinra 100 mg/day SC was initiated, noting in a few days a progressive clinical, analytical and radiological improvement.

© 2015 Elsevier España, S.L.U. and Sociedad Española de Reumatología y Colegio Mexicano de Reumatología. All rights reserved.

### Neumonitis aguda en un paciente con enfermedad de Still del adulto tras tratamiento con tocilizumab con buena respuesta a anakinra

#### RESUMEN

La afectación pulmonar en forma de neumonitis aguda en la enfermedad de Still del adulto (ESA) es una manifestación infrecuente, existiendo pocos casos descritos en la literatura. Presentamos el caso de un varón de 61 años con ESA de 3 años de evolución, en tratamiento con metotrexato (MTX) y corticoides a dosis medias, que comenzó con cuadro de fiebre, disnea y tos seca a las 3 semanas de recibir la primera dosis de tocilizumab (TCZ). En la analítica destacaban leucocitosis con desviación izquierda, ferritina sérica muy elevada y proteína C reactiva normal. La TAC de tórax mostró un patrón en vidrio deslustrado de predominio central y lóbulos superiores, y el BAL, un incremento del porcentaje de linfocitos, con subpoblaciones normales y cultivos negativos. Se suspendieron el MTX y el TCZ, se aumentó la prednisona a 30 mg/día y al cabo de una semana se inició anakinra 100 mg/día por vía subcutánea, observando en pocos días una mejoría progresiva espectacular clínica, analítica y radiológica.

© 2015 Elsevier España, S.L.U. y Sociedad Española de Reumatología y Colegio Mexicano de Reumatología. Todos los derechos reservados.

##### Palabras clave:

Enfermedad de Still del adulto

Neumonitis aguda

Tocilizumab

Metotrexate

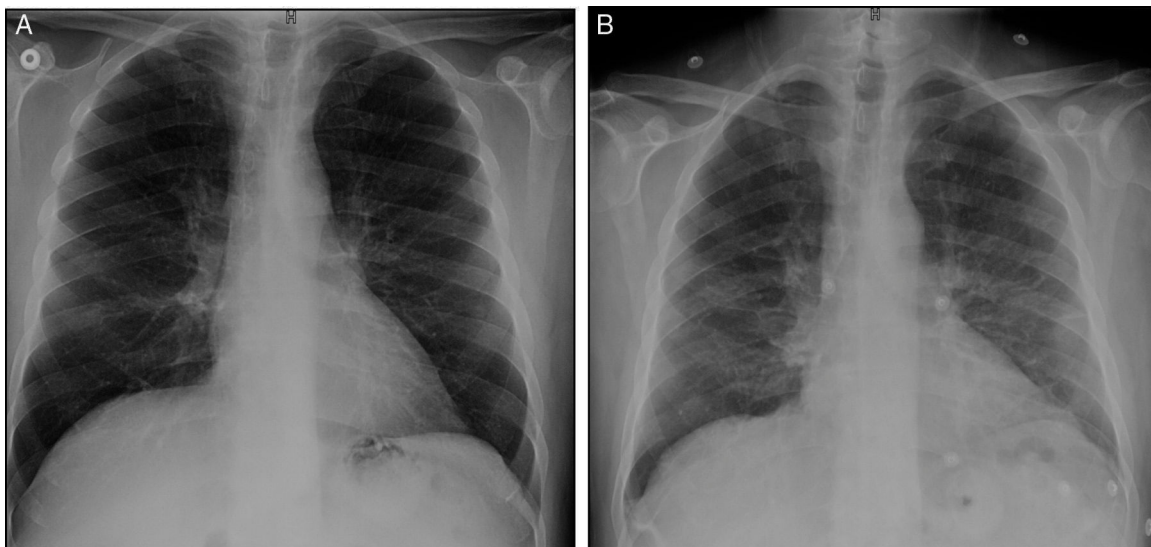
#### Introduction

Adult-onset Still's disease (AOSD) is an inflammatory disorder of unknown etiology, characterized by intermittent high fever, a salmon-colored evanescent maculopapular rash, polyarthritis or oligoarthritis, and leukocytosis. These signs are frequently accompanied by odynophagia, adenopathy, hepatosplenomegaly and pleuropericarditis. Pulmonary involvement is uncommon, with an

<sup>☆</sup> Please cite this article as: Sangüesa Gómez C, Flores Robles BJ, Jara Chinarro B, Espinosa Malpartida M, Barbadillo Mateos C. Neumonitis aguda en un paciente con enfermedad de Still del adulto tras tratamiento con tocilizumab con buena respuesta a anakinra. Reumatol Clin. 2016;12:345–347.

\* Corresponding author.

E-mail address: clararwen@hotmail.com (C. Sangüesa Gómez).

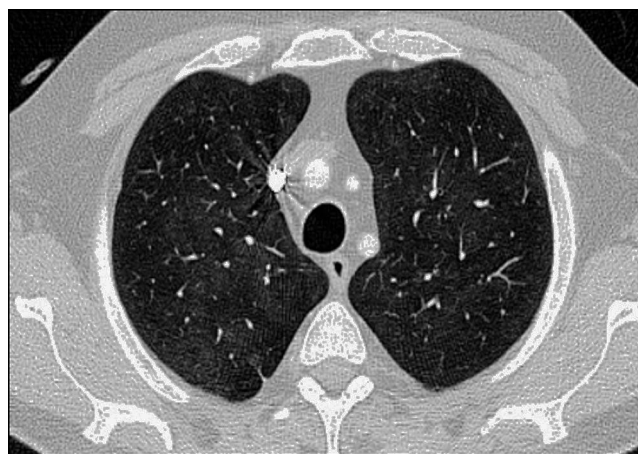

**Fig. 1.** (A) Anteroposterior chest radiograph showing a faint bilateral interstitial line. (B) Anteroposterior chest radiograph 2 days later showing a diffuse density in the region of the hilum and lung bases, and imaging of segmental atelectasis in the middle field.

estimated prevalence of between 12% and 53% for pleuritis and from 0 to 7% for interstitial pneumonia.<sup>1,2</sup>

### Case Report

The patient was a 61-year-old man with a personal history of asthma who was diagnosed with AOSD in October 2011. He was initially treated with nonsteroidal anti-inflammatory drugs (NSAID). After 1 month, glucocorticoid (GC) therapy was started because of the development of skin involvement. In March 2012, subcutaneous methotrexate (MTX) was added as a steroid-sparing agent, and was escalated up to 25 mg a week. For 2 years, a good control of the disease was achieved and maintained, making it possible to reduce the prednisone dose to 2.5 mg/day. However, in November 2014, the patient experienced a severe joint and cutaneous flare that required hospital admission and an increase in corticosteroid therapy. After 1 month, the decision was made to initiate treatment with tocilizumab (TCZ) because of persistent arthralgia, fever and neutrophilic leukocytosis with hyperferritinemia, despite the treatment with MTX and high-dose oral GC. Three weeks after receiving the first and only dose of TCZ at 8 mg/kg body weight, he presented to the outpatient clinic with dyspnea on moderate exertion. There was no evidence of infection or cardiac decompensation. The only noteworthy finding on physical examination was a baseline oxygen saturation ( $SO_2$ ) of 93%. An emergency chest radiograph (Fig. 1A) showed a faint image of bilateral interstitial involvement and the patient was referred to the emergency department. The results of the laboratory analyses performed there included a slightly decreased partial pressure of oxygen ( $PO_2$ ) (70.900 mmHg), leukocytosis ( $13.54 \times 10^3/\mu\text{L}$ ), neutrophilia ( $11.93 \times 10^3/\mu\text{L}$ ), lymphopenia ( $0.59 \times 10^3/\mu\text{L}$ ), C-reactive protein < 0.5 mg/L and elevated D-dimer (1.77  $\mu\text{g}/\text{mL}$ ). The electrocardiogram was normal. Computed tomography (CT) angiography served to rule out pulmonary thromboembolism. However, the lung window (Fig. 2) revealed an increased ground glass density, predominantly in middle and upper lobes, suggestive of alveolar inflammation. In agreement with the pulmonology department, and given that the clinical signs were mild at that time, the decision was made to carry out pulmonary function tests (PFT), to perform a clinical reevaluation over the following days and to discontinue treatment with MTX and TCZ, as we suspected their possible implication in this condition. He returned 2 days later, complaining of a



**Fig. 2.** Computer tomography showing a subtle increase in the ground glass density in upper thorax, predominantly in central and upper lobes, suggestive of an alveolar inflammatory process.

significant deterioration in his clinical status, with the development of fever and a dry cough, and was unable to complete the scheduled PFT. On the other hand, he had been taking amoxicillin/clavulanic acid for the preceding 2 days because of a dental abscess. A chest radiograph performed at that time (Fig. 1B) showed an increase in diffuse density in the region of the hilum and base of the lung. He was admitted to the hospital to complete the study and begin treatment with prednisone at 30 mg/day. The laboratory tests revealed a ferritin level of 4023 ng/mL (previously 1997 ng/mL), C-reactive protein at 17.7 mg/L, leukocytosis at  $15,280 \times 10^3/\mu\text{L}$ , neutrophils at  $12,360 \times 10^3/\mu\text{L}$  and lymphocytes at  $1870 \times 10^3/\mu\text{L}$ , there being no other noteworthy findings. Bronchoalveolar lavage revealed an increase in the percentage of lymphocytes, with normal lymphocyte subsets and negative results for cytology and cultures for fungi, cytomegalovirus, herpes, influenza/parainfluenza and adenovirus, and negative staining of acid-alcohol fast bacilli. The PFT disclosed a restrictive change with a reduced diffusing capacity (48%), which was not corrected for at alveolar volume. During his hospital stay, the patient initially required oxygen therapy at 1.5 bpm and, subsequently, treatment with subcutaneous anakinra was introduced at 100 mg/day. Within a few days, he began to show progressive

improvement in both clinical signs and laboratory results, as well as normalization of the radiographic pattern after 10 days and, after 1 month, control of ferritin and CT images.

## Discussion

The percentage of patients with AOSD exhibiting pulmonary involvement in the form of acute pneumonitis is estimated to be quite low. It is characterized by the presence of transient pulmonary infiltrates in upper and lower lobes, often associated with small pleural effusions.<sup>3</sup> An infectious process is frequently suspected from the start, especially in immunocompromised patients, as in the case we report here, because of the association with fever, dyspnea and leukocytosis. The absence of a response to antibiotic therapy and negative results in a microbiological study help to rule out this origin. On the other hand, there is a wide variety of drugs that can induce pulmonary toxicity. Thus, concomitant treatment with MTX, which our patient received, was proposed as a possible trigger for the pneumonitis. Methotrexate can produce acute or subacute pneumonitis and, less commonly, chronic pneumonitis, and the incidence of acute pneumonitis in patients being treated with MTX for rheumatic diseases is estimated to be between 0.3% and 8%.<sup>4</sup> However, the clinical manifestations (dyspnea, nonproductive cough, fever) usually develop a few days after the initiation of MTX therapy or, less frequently, weeks or months later. We should point out that the patient had been taking MTX for 3 years and had never mentioned respiratory symptoms. On the other hand, he had not shown pulmonary involvement in any of the AOSD flares that he had experienced prior to receiving TCZ, and we were able to review a previous CT study and recent chest radiographs in which no changes were observed. These facts, together with the sudden development of the symptoms following the first dose of TCZ, lead us to think of a highly relevant role of this drug in the development of the pneumonitis or even a possible paradoxical induction of a pulmonary flare of AOSD.

To our knowledge, only 8 cases of pulmonary toxicity allegedly induced by TCZ have been reported to date, most of the patients were receiving monotherapy and all of them had rheumatoid arthritis.<sup>5–9</sup> The reported pulmonary involvement was, in one case, the fatal exacerbation of interstitial lung disease associated with rheumatoid arthritis after the initiation of TCZ therapy. In one patient, *de novo* interstitial lung disease was observed and, in the other, pulmonary fibrosis. Of the 3 cases that were noninfectious, 2 of the patients received concomitant MTX, which was the case of our patient. There has been a case of allergic pneumonitis and another of organizing pneumonia with TCZ.

In short, we report lung involvement in AOSD in therapy with MTX, following treatment with TCZ, a complication that is uncommon and is presented by a satisfactory response to anakinra.

## Ethical Disclosures

**Protection of human and animal subjects.** The authors declare that no experiments were performed on humans or animals for this study.

**Confidentiality of data.** The authors declare that they have followed the protocols of their work center on the publication of patient data.

**Right to privacy and informed consent.** The authors declare that no patient data appear in this article.

## Conflicts of Interest

The authors declare they have no conflicts of interest.

## References

1. Yamaguchi M, Ohta A, Tsunematsu T, Kasukawa R, Mizushima Y, Kashiwagi H, et al. Preliminary criteria for classification of adult Still's disease. *J Rheumatol.* 1992;19:424–30.
2. Ohta A, Yamaguchi M, Tsunematsu T, Kasukawa R, Mizushima H, Kashiwagi H, et al. Adult Still's disease: a multicenter survey of Japanese patients. *J Rheumatol.* 1990;17:1058–63.
3. Cheema GS, Quismorio FP. Pulmonary involvement in adult-onset Still's disease. *Curr Opin Pulmonary Med.* 1999;5:305–9.
4. Imokawa S, Colbi TV, Leslie KO, Helmers RA. Methotrexate pneumonitis: review of the literature and histopathological findings in nine patients. *Eur Resp J.* 2000;15:373–81.
5. Nishimoto N, Yoshizaki K, Miyasaka N, Yamamoto K, Kawai S, Takeuchi T, et al. Treatment of rheumatoid arthritis with humanized anti-interleukin-6 receptor antibody: a multicenter, double-blind, placebo-controlled trial. *Arthritis Rheum.* 2004;50:1761–9.
6. Smolen JS, Beaulieu A, Rubbert-Roth A, Ramos-Remus C, Rovensky J, Alecock E, et al. Effect of interleukin-6 receptor inhibition with tocilizumab in patients with rheumatoid arthritis (OPTIONstudy): a double-blind, placebo-controlled, randomised trial. *Lancet.* 2008;371:987–97.
7. Nishimoto N, Miyasaka N, Yamamoto K, Kawai S, Takeuchi T, Azuma J, et al. Study of active controlled tocilizumab monotherapy for rheumatoid arthritis patients with an inadequate response to methotrexate (SATORI): significant reduction in disease activity and serum vascular endothelial growth factor by IL-6 receptor inhibition therapy. *Mod Rheumatol.* 2009;19:12–9.
8. Ikegawa K, Hanaoka M, Ushiki A, Yamamoto H, Kubo K. A case of organizing pneumonia induced by tocilizumab. *Intern Med.* 2011;50:2191–3.
9. Kawashiri SY, Kawakami A, Sakamoto N, Ishimatsu Y, Eguchi K. A fatal case of acute exacerbation of interstitial lung disease in a patient with rheumatoid arthritis during treatment with tocilizumab. *Rheumatol Int.* 2012;32:4023–6.