



Sociedad Española  
de Reumatología -  
Colegio Mexicano  
de Reumatología

# Reumatología Clínica

www.reumatologiaclinica.org



Images in Clinical Rheumatology

## Pyrophosphate Arthropathy Causing Shoulder Pain: Value of Ultrasound in Its Therapeutic Approach<sup>☆</sup>



Artropatía por pirofosfato cálcico como causa de hombro doloroso: valor de la ecografía en el abordaje diagnóstico

Mónica M. Román Sastre,<sup>\*</sup> M. Luisa Vega González

Servicio de Radiodiagnóstico, Hospital Clínico Universitario San Carlos, Madrid, Spain

### ARTICLE INFO

#### Article history:

Received 28 April 2015

Accepted 4 September 2015

Available online 13 October 2016

The patient was a 77-year-old woman who had been complaining of a history of several months of pain and functional impotence, due to discomfort involving the abduction and internal rotation of her right shoulder. It had improved, but had gotten worse in the last 2 weeks.

In the ultrasound performed initially to exclude involvement of the rotator cuff (Fig. 1), there are signs of supraspinatus tendinopathy, with a small partial rupture and the characteristic calcifications of pyrophosphate depositions in the acromioclavicular joint and in the cartilage of the humeral head, following its outline.

Plain radiography (Fig. 2) from that moment shows degenerative changes in the glenohumeral joint, and also reveals chondrocalcinosis of the humeral cartilage and the acromioclavicular joint.

### Discussion

The deposits of calcium pyrophosphate occur just inside or, surrounding the joints, where there are calcifications in the thickness of joint cartilages, menisci, synovial and periarticular tissues.<sup>1,2</sup>

Although, the deposit of pyrophosphate crystals has nearly no hyaline cartilage or fibrocartilage. However, areas of chondroid metaplasia have also been found to have extraarticular deposits similar to tophi, as in tendons or bursa.

However, the crystal deposits in cartilage are not made exclusively of pyrophosphate, and have been reported in the case of monosodium urate.<sup>3</sup>

These deposits (chondrocalcinosis) can be asymptomatic, become associated with degenerative joint manifestations, or produce acute episodic arthritis (pseudogout).<sup>1</sup>

They should be differentiated from calcific tendinitis, mainly through the presence in the deposit of hydroxyapatite (and, less frequently, monosodium urate or calcium pyrophosphate),<sup>3</sup> in which the crystal deposit is intratendinous, and can produce the rupture of the base of the tendon, and extend to the interior of the subacromial bursa (Fig. 3).

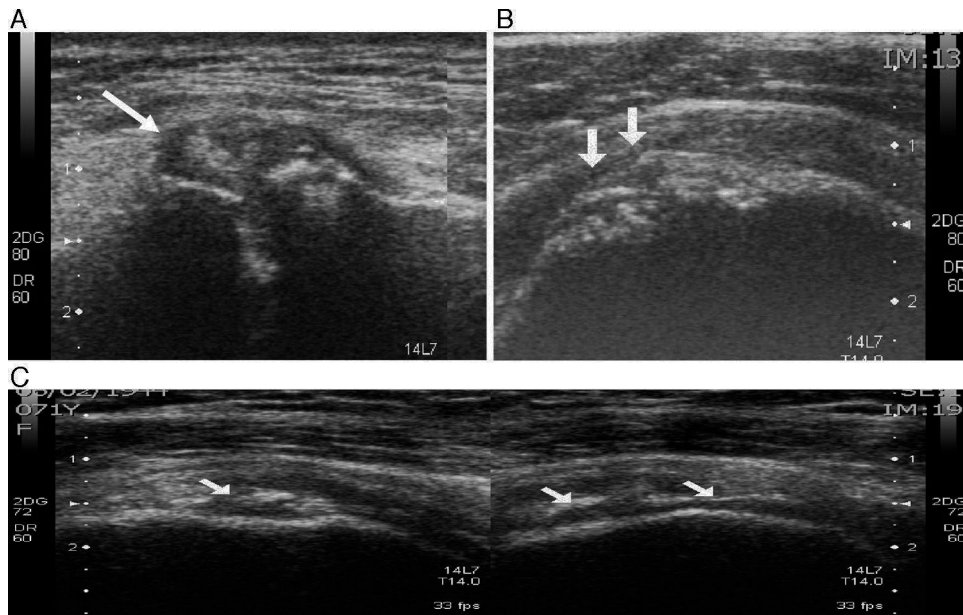
Both processes are susceptible to being diagnosed early by means of ultrasound, as the latter tends to evaluate the, characteristic site and extension of the calcifications.<sup>4,5</sup> Plain radiography, also makes it possible to differentiate the degenerative changes in the glenohumeral joint, using arthropathy for pyrophosphate and an arthropathy for a rotator cuff tear.<sup>2,4–7</sup>

The prevalence of 3.7%–17.5% for radiological chondrocalcinosis (according to the age group being used as a reference),<sup>1</sup> and the 2.7%–20% for the calcific tendinopathy.<sup>8</sup> Although, in our experience, pyrophosphate deposition (3/1) is much more probably due to the early detection of calcified acromioclavicular joint in the ultrasound.

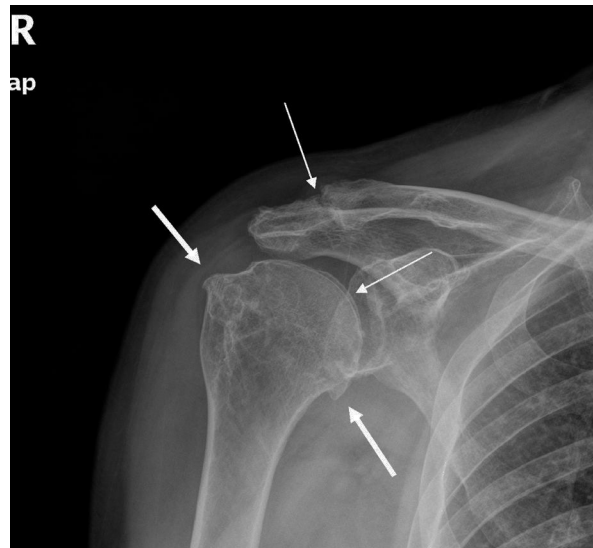
<sup>☆</sup> Please cite this article as: Román Sastre MM, Vega González ML. Artropatía por pirofosfato cálcico como causa de hombro doloroso: valor de la ecografía en el abordaje diagnóstico. Reumatol Clin. 2016;12:351–353.

<sup>\*</sup> Corresponding author.

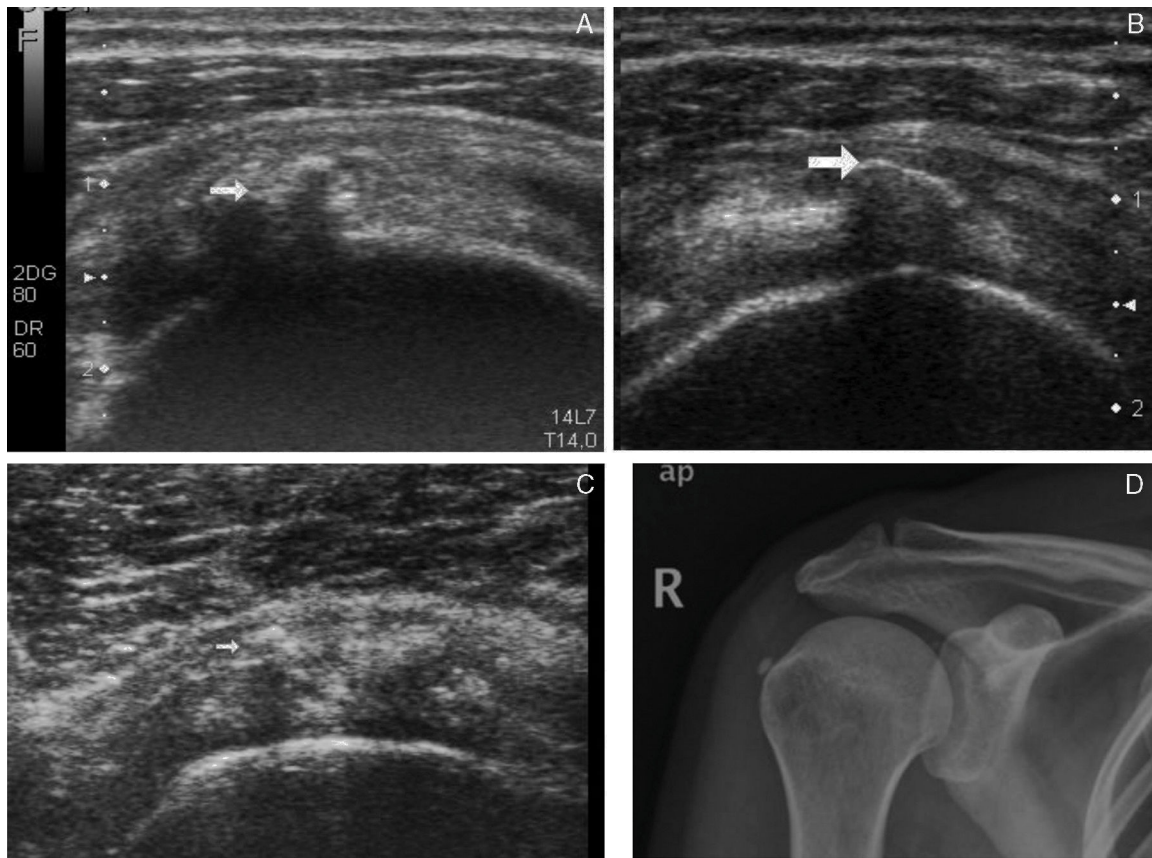
E-mail address: [monikamrs@hotmail.com](mailto:monikamrs@hotmail.com) (M.M. Román Sastre).



**Fig. 1.** (A) Joint effusion and calcifications in the acromioclavicular joint. (B) Calcifications of the humeral cartilage (chondrocalcinosis). (C) Subchondral erosions and subacute-chronic rupture of the anterior portion of the supraspinatus tendonopathy (tendinous weight loss due to compression).



**Fig. 2.** Osteophytosis of the humeral head in relation to degenerative changes in the glenohumeral joint (thick arrows). Calcification of the acromioclavicular joint and humeral cartilage (thin arrows). No tendinous calcifications or subacromial impingement are observed.



**Fig. 3.** Arthropathy for a hydroxyapatite deposit. (A) Intratendinous calcifications (see arrow). (B) Calcification in floor of the subacromial bursa. (C) Small calcifications in anterior portion of the supraspinatus tendonopathy and 1 (see arrow) in the interior of the subacromial bursa. (D) Plain radiography of tendinous calcification of supraspinatus.

### Conclusion

The clinical entity referred to as the “sore shoulder” should probably be approached by a series of specialists, because of the frequency with which the diagnosis is delayed. It can also be based on an incorrect diagnostic information, meaning that the therapeutic approach becomes more difficult. Likewise, a multitude of imaging techniques, may be requested, and some may not be necessary.

Ultrasound and radiography of the shoulder, when verified together, make it easier to approach the management of the sore shoulder. Moreover, they provide an adequate and early differential diagnosis.

### Ethical Disclosures

**Protection of human and animal subjects.** The authors declare that no experiments were performed on humans or animals for this study.

**Confidentiality of data.** The authors declare that they have followed the protocols of their work center on the publication of patient data.

**Right to privacy and informed consent.** The authors declare that no patient data appear in this article.

### Conflicts of Interest

The authors declare they have no conflicts of interest.

### References

1. Richette P, Bardi T, Doherty M. An update on the epidemiology of calcium pyrophosphate dehydrate crystal deposition disease. *Rheumatology*. 2009;48:711–5.
2. Magarelli N, Amelia R, Melillo N, Nasuto M, Cantatore F, Guglielmi G. Imaging of chondrocalcinosis: calcium pyrophosphate dehydrate (CPPD) crystal deposition disease imaging of common sites of involvement. *Clin Exp Rheumatol*. 2012;30:118–25.
3. Fodor D, Albu A, Gherman C. Crystal-associated synovitis – ultrasonographic feature and clinical correlation. *Ortop Traumatol Rehabil*. 2008;10:99–110.
4. Filippucci E, di Geso L, Girolimetti R, Grassi W. Ultra sound incristal-related arthritis. *Clin Exp Rheumatol*. 2014;32 Suppl. 80:S42–7.
5. Barskova VG, Kudaeva FM, Bozchieva LA, Smirnov AV, Volkov AV, Nasonov EL. Comparison of three imaging techniques in diagnosis of chondrocalcinosis of the knees in calcium pyrophosphate deposition disease. *Rheumatology (Oxf)*. 2013;52:1090–4.
6. MacQueen FM, Doyle A, Dalbeth N. Imaging in the crystal arthropathies. *Rheum Dis Clin North Am*. 2014;40:231–49.
7. Paparo F, Fabbro E, Ferrero G, Piccasso R, Revelli M, Camellino D, et al. Imaging Studies of crystalline arthritides. *Reumatismo*. 2012;63:263–75.
8. Ea HK, Lioté F. Diagnosis and clinical manifestations of calcium pyrophosphate and basic calcium phosphate crystal deposition diseases. *Rheum Dis Clin North Am*. 2014;40:207–29.