

2. Ramos-Casals M, Brito-Zerón P, Sisó-Almirall A, Bosch X. Primary Sjögren syndrome. *Praxis* (Bern 1994). 2012;101:1565–71.
3. Madhushankari GS, Yamunadevi A, Selvamani M, Mohan Kumar KP, Basandi PS. Halitosis – an overview: Part-I – Classification, etiology, and pathophysiology of halitosis. *J Pharm Bioallied Sci*. 2015;7 Suppl. 2:S339–43.
4. Hinchcliff M, Varga J. Systemic sclerosis/scleroderma: a treatable multisystem disease. *Am Fam Physician*. 2008;78:961–8.

Rami Qanneta

Servicio de Reumatología, Hospital Universitari Joan XXIII, Tarragona, Spain

E-mail address: rami_kanita229@hotmail.com

New Drugs in Takayasu Arteritis, Role of Tocilizumab[☆]



Nuevos fármacos en la arteritis de Takayasu, papel del tocilizumab

Dear Editor:

Evaluating Takayasu arteritis (TA), one of the so-called rare diseases, we should know that this is a granulomatous vasculitis that affects large vessels, especially the aorta and its major branches, especially in young women.¹ Given the infrequency of this disease, there are no controlled randomized studies. Thus, its treatment is based on retrospective observational studies.¹ In patients who are refractory to conventional treatment, a marked effect by biological therapies like tocilizumab was recently reported.^{1,2}

We describe the case of a 63-year-old woman who had a 4-year-history of TA. She initially presented with left suboccipital headache associated with ipsilateral episcleritis, an increase in acute-phase reactants, and physical examination showed differences in systolic arterial blood pressure of her two arms of more than 10 mmHg, as well as, weakness in her temporal, carotid and radial pulses of her left side. The diagnostic study found relevant analytical data, including her positivity for rheumatoid factor, high C-reactive protein and erythrocyte sedimentation rate, and her testing positive for anti-Sp100 and negative for: antinuclear antibodies, extractable nuclear antigen, anti-cyclic citrullinated protein antibodies, human leukocyte antigens B7 and B52 and anti-smooth muscle antibody. She underwent magnetic resonance angiography (MRA) of supraortic arteries with the following findings: 50% stenosis of right internal carotid artery, insignificant stenoses of left internal carotid artery, left external carotid artery and partially assessed subclavian arteries. Aside from MRA of aorta, which indicated stenosis proximal to the right subclavian and, with a filiform and irregular trajectory, and left subclavian stenosis. On the other hand, whole-body positron emission tomography indicated inflammatory activity at the level of the ascending aorta, aortic arch and abdominal aorta, with no evidence of involvement at other sites. Initially the patient was treated with prednisone (initial dose was 15 mg/24 h) for 2 years and azathioprine was incorporated (50 mg a day), to be discontinued because of an increase in her transaminases. Then, after only 1 year of corticosteroid therapy, mycophenolate mofetil was introduced at 1 g/12 h. She continued 1 year later in remission, but it was necessary to increase mycophenolate mofetil to 2.5 g daily. Seven months later, treatment with tocilizumab was begun, which achieved the disappearance of her clinical manifestations, together with a decrease in the prednisone dose to 10 mg/day.

[☆] Please cite this article as: Martín Guillén S, Álvarez de Cienfuegos A, Hurtado García R. Nuevos fármacos en la arteritis de Takayasu, papel del tocilizumab. *Reumatol Clin*. 2016;12:358–359.

The treatment of choice in TA is corticosteroids, although they induce an initial remission in 90% of the patients. It is estimated that approximately half of the effects will be resistant to them, and it will be necessary to add immunosuppressive agents (azathioprine, methotrexate or mycophenolate mofetil).^{2,3} Moreover, we should not forget the secondary toxicity of long-term corticosteroid therapy.⁴ The use of immunosuppressive drugs will help to decrease the corticosteroid dose to the minimum necessary.⁴ However, their effectiveness will not be completely demonstrated by randomized studies, taking into account that an estimated 33% of the patients treated will have relapses.⁵ The pathogenesis of TA involves the secretion of proinflammatory cytokines (tumor necrosis factor, interleukin [IL] 6), and it has been demonstrated that serum IL-6 levels are markers of its own activity.⁴ For this reason, tocilizumab (a monoclonal antibody that blocks IL-6 receptor) is an effective option for the treatment of refractory TA.

One of the largest long-term studies, which deals with biological therapy in TA, indicates that, whether corticosteroid-resistant or dependent, the association with immunosuppressive agents can improve the control of the disease, and even, reduces the corticosteroid dose to the minimum necessary.² However, relapses and the progression of vascular involvement persist. The use of tocilizumab in refractory TA is safe and effective. The clinical response is good (improvement in 83%), and it even enables reduction of the corticosteroid dose (up to 50%).^{2,4} Nevertheless, when the drug is discontinued, there is a reactivation of the disease, a fact that points to the need for a maintenance therapy.

Despite the good results observed with tocilizumab, studies performed to date reveal limitations. As they are retrospective, the sample size is small, and they are carried out without a control group.^{3,5} However, we can consider it an alternative to be studied in patients with TA that is difficult to control. In conclusion, this is a good therapeutic option, even in patients who are easy to manage. Nonetheless, multicenter randomized studies must be performed to confirm these findings.

References

1. Alibaz-Oner F, Direskeneli H. Update on Takayasu's arteritis. *Presse Med*. 2015;44:e259–65.
2. Mekinian A, Comarmond C, Resche-Regon M, Mirault T, Kahn JE, Lambert M, et al., French Takayasu Network. Efficacy of biological-targeted treatments in Takayasu arteritis: multicenter, retrospective study of 49 patients. *Circulation*. 2015;132:1693–700.
3. Abisror N, Mekinian A, Lavigne C, Vandenhende MA, Soussan M, Fain O, Club Rhumatismes et Inflammation, and SNFMI. Tocilizumab in refractory Takayasu arteritis: a case series and updated literature review. *Autoimmun Rev*. 2013;12:1143–9.
4. Goel R, Danda D, Kumar S, Joseph G. Rapid control of disease activity by tocilizumab in 10 “difficult-to-treat” cases of Takayasu arteritis. *Int J Rheum Dis*. 2013;16:754–61.
5. Nakaoka Y, Higuchi K, Arita Y, Otsuki M, Yamamoto K, Hashimoto-Kataoka T, et al. Tocilizumab for the treatment of patients with refractory Takayasu arteritis. *Int Heart J*. 2013;54:405–11.

Sonia Martín Guillén,^a Antonio Álvarez de Cienfuegos,^b
Roberto Hurtado García^{c,*}

^a Servicio de Medicina Interna, Hospital Vega Baja de Orihuela (Alicante), España, Residente de Medicina de Familia y Atención Comunitaria, Spain

^b Sección de Reumatología, Servicio de Medicina Interna, Hospital Vega Baja de Orihuela (Alicante), Spain

^c Servicio de Medicina Interna, Hospital Vega Baja de Orihuela (Alicante), Spain

* Corresponding author.

E-mail address: robex2@gmail.com (R. Hurtado García).

Treatment With Monoclonal Antibodies and Pregnancy in Women With Systemic Inflammatory Diseases: A Special Situation[☆]



Una situación especial: tratamiento con anticuerpos monoclonales y embarazo en mujeres con enfermedades inflamatorias sistémicas

Dear Editor:

Pregnancy is a situation of semi-allogenic immunological tolerance with regard to the fetus. The mechanisms of tolerance are described as uterine changes induced by the syncytiotrophoblast over: cytokines, T and natural killer (NK) lymphocytic subpopulations and complement, as well as the presence of human leukocyte antigen (HLA)-C class II, HLA-E and HLA-G. Moreover, systemic immunological changes are also produced: thymic involution through progesterone, decreased NK activity and a change toward an anti-inflammatory profile of cytokines (T helper cells [Th2]).¹

Monoclonal antibodies (mAb) have revolutionized the treatment of autoimmune and inflammatory diseases, so frequent among women of childbearing age. Therefore, their utilization before or during pregnancy, is sometimes proposed, as a question of clinical practice. The mAb used, at the present time, are not apt for utilization during pregnancy² and there are no controlled studies

in pregnant women. According to the United States Food and Drug Administration (FDA), these mAb are classified as category B (infliximab), as are their biosimilars, adalimumab, etanercept, golimumab and certolizumab pegol [CZP]), and as C (rituximab, tocilizumab and abatacept). There have been no significant differences in the rate of abortions among patients exposed to infliximab and naïve patients.^{3,4}

To understand the process of placental transfer of mAb would help us to evaluate the risk of beginning or maintaining their administration during pregnancy. Nutrients are transferred to the fetus through a maternal layer of syncytiotrophoblasts and another of endothelium (fetal capillaries) by simple diffusion or using transport proteins. Toxins are returned by the fetus to the maternal circulation to be eliminated. Composed of low molecular weight (<500 Da), like O₂ and amino acids, they diffuse passively through the placenta, but those with a high molecular weight require transport proteins to cross it. Immunoglobulin G (IgG) has a molecular weight of 160 kDa and crosses the placenta through the neonatal Fc receptor (FcRn) present in the syncytiotrophoblast cells.^{5,6}

The structure of most of the mAb utilized contains a constant region of IgG1 (Fc) and, during the first 20–22 weeks of pregnancy, there is a minimal active transfer because of the absence of FcRn. Transport across the placenta increases significantly toward the third trimester of the pregnancy (Fig. 1). Certolizumab pegol contains a PEGylated Fab fragment of the anti-tumor necrosis factor

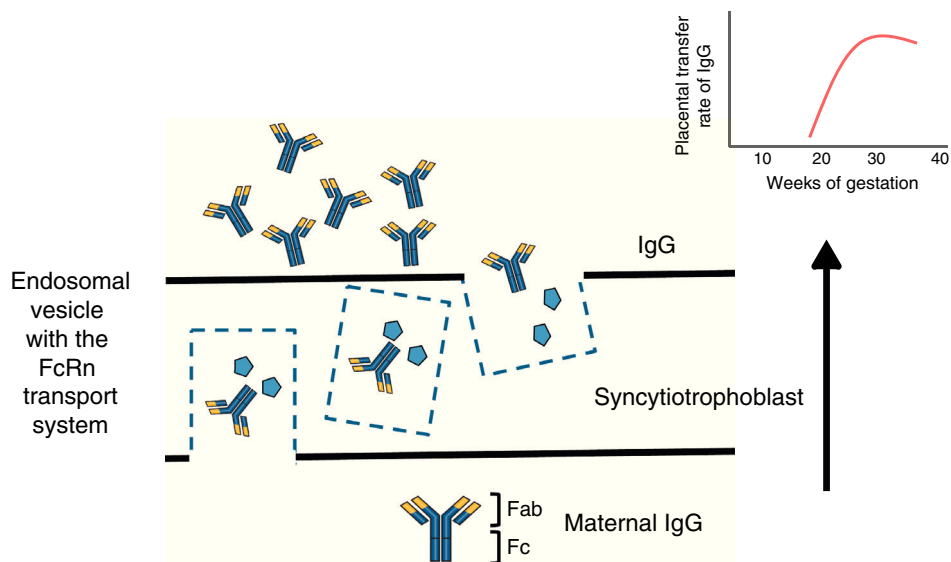


Fig. 1. Immunoglobulin G crosses the placental barrier through the FcRn transport system, present in the syncytiotrophoblast cells. Fab, variable region; Fc, constant region of the immunoglobulin; FcRn, neonatal Fc receptor; IgG, immunoglobulin G.

[☆] Please cite this article as: Valor L, Ovalles-Bonilla JG, Hernández-Flórez D, López-Longo FJ. Una situación especial: tratamiento con anticuerpos monoclonales y embarazo en mujeres con enfermedades inflamatorias sistémicas. Reumatol Clin. 2016;12:359–360.