



Sociedad Española
de Reumatología -
Colegio Mexicano
de Reumatología

Reumatología Clínica

www.reumatologiaclinica.org



Images in Clinical Rheumatology

Hydroxyapatite and Calcium Pyrophosphate Crystals Mimicking Gout in Systemic Sclerosis[☆]



Cristales de hidroxiapatita y pirofosfato de calcio imitando gota en una paciente con esclerosis sistémica

Lucio Ventura-Ríos,^{*} Diana Ferrusquia-Toriz

Laboratorio de Ultrasonido Musculoesquelético y Articular, Instituto Nacional de Rehabilitación «Luis Guillermo Ibarra Ibarra», Mexico City, Mexico

ARTICLE INFO

Article history:

Received 8 February 2016

Accepted 3 April 2016

Available online 18 March 2017

The patient was a 61-year-old woman who presented with moderate pain and functional limitation of left knee that had begun 4 months earlier. She had a 2-year history of systemic sclerosis. Physical examination revealed that the knee was swollen and warm. Her erythrocyte sedimentation rate was 47 mm/h. Radiographies of the knees were normal. Ultrasound images of the knees with power Doppler at a moderate frequency demonstrated synovitis, a double contour sign over the femoral cartilage (Fig. 1A) and calcification of the medial meniscus. Synovial fluid analysis by polarized light microscopy revealed abundant hydroxyapatite (HA) crystals (Fig. 1B), and a few consisting of calcium pyrophosphate (CP) (Fig. 1C). Hydroxyapatite crystals have been reported in

hyaline cartilage or in the synovial fluid of patients with autoimmune diseases, such as scleroderma and pseudogout.^{1,2} We have found no previous accounts of the double contour sign over the cartilage associated with HA deposition similar to that described in gout. The typical radiographic findings in pseudogout include a thin band parallel to the bony cortex, but separated from it by the hypochoic area corresponding to the cartilage.³ The association between the linear calcification of the cartilage or meniscus observed in pseudogout and HA crystals is unexpected.⁴ It could be that both HA and CP crystals contributed to the images observed. There is little information in the literature concerning the specific ultrasonographic characteristics of arthropathy related to HA. Thus,

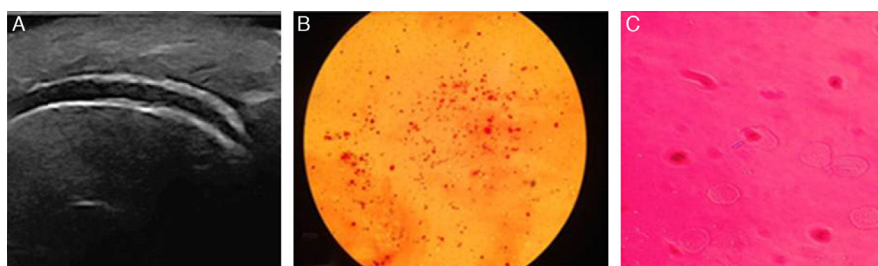


Fig. 1. (A) Longitudinal view of femoral cartilage showing the double contour sign. (B) Abundant round clusters of calcium hydroxyapatite stained with alizarin. (C) A few extracellular rectangular calcium pyrophosphate crystals showing positive birefringence seen under polarized light microscopy.

[☆] Please cite this article as: Ventura-Ríos L, Ferrusquia-Toriz D. Cristales de hidroxiapatita y pirofosfato de calcio imitando gota en una paciente con esclerosis sistémica. Reumatol Clin. 2017;13:235–236.

^{*} Corresponding author.

E-mail address: venturarioslucio@gmail.com (L. Ventura-Ríos).

it is important to analyze the synovial fluid prior to establishing the definitive diagnosis.

Ethical Disclosures

Protection of human and animal subjects. The authors declare that no experiments were performed on humans or animals for this study.

Confidentiality of data. The authors declare that no patient data appear in this article.

Right to privacy and informed consent. The authors declare that no patient data appear in this article.

Conflicts of Interest

The authors declare they have no conflicts of interest.

References

1. Filippucci E, Gutierrez E, Georgescu D, Salaffi F, Grassi W. Hyaline cartilage involvement in patients with gout and calcium pyrophosphate deposition disease. An ultrasound study. *Osteoarthr Cartilage.* 2009;17:178–81.
2. Frediani B, Filippou G, Falsetti P, Lorenzini S, Baldi F, Acciai C, et al. Diagnosis of calcium pyrophosphate dihydrate crystal deposition disease: ultrasonographic criteria proposed. *Ann Rheum Dis.* 2005;64:638–40.
3. McQueen F, Doyle A, Dalbeth N. Imaging in the crystal arthropathies. *Rheum Dis Clin N Am.* 2014;40:231–49.
4. Fodor D, Albu A, Gherman C. Crystal-associated synovitis-ultrasonographic feature and clinical correlation. *Orthop Traumatol Rehabil.* 2008;10:99–110.