



Sociedad Española
de Reumatología -
Colegio Mexicano
de Reumatología

Reumatología Clínica

www.reumatologiaclinica.org



Images in Clinical Rheumatology

Fibrodysplasia Ossificans Progressiva: Case Report of a Terminal Patient[☆]



Fibrodisplasia osificante progresiva: comunicación de un caso terminal

María del Mar Muñoz Gómez,^{a,*} Marta Novella Navarro,^a Fernando Ruiz Santiago,^b Enrique Raya Álvarez^a

^a Departamento de Reumatología, Hospital Universitario San Cecilio, Granada, Spain

^b Sección de Radiología Musculoesquelética, Hospital Universitario Virgen de las Nieves, Granada, Spain

ARTICLE INFO

Article history:

Received 5 March 2016

Accepted 22 April 2016

Available online 28 April 2017

The patient was a 29-year-old woman, with a history of type 1A diabetes and primary amenorrhea secondary to cervical agenesis. At the age of 10 years, she was examined because she had developed a tumor in the cervical region, with no previous injury; she underwent a radiological study and bone biopsy that was compatible with myositis ossificans. Over the years, large ectopic ossifications developed in her shoulders, hips, knees, ankles and paravertebral muscles, which produced a marked secondary thoracolumbar scoliosis and a considerably generalized functional limitation. A plain radiology study of the affected areas showed the existence of exuberant bone bridges at different stages of maturation, that provoked the locking and ankylosing of a number of joints, including a knee (Fig. 1), the spine (Fig. 2) and a shoulder (Fig. 3). The patient was treated with bisphosphonates and calcium supplements with vitamin D for 5 years, while she was also being followed by the rehabilitation service; however, none of these measures was capable of arresting the course of the disease, which led to the physical disability of the patient.

Fibrodysplasia ossificans progressiva is a rare disease of unknown origin that is characterized by a progressive heterotopic ossification of the muscles and other structures in which connective tissue is abundant.¹ In recent years, there has been an advance in our knowledge of the etiological and pathogenic mechanisms of this disorder, which implicates the receptor of bone morphogenetic protein (BMP), the so-called activin A type I

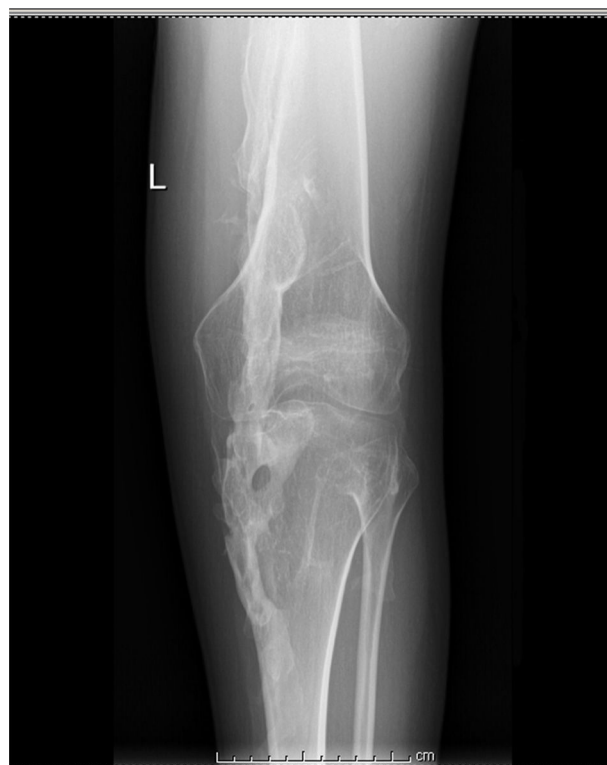

Fig. 1. Radiograph of left knee showing ankylosis secondary to bone bridges.

[☆] Please cite this article as: Muñoz Gómez MM, Novella Navarro M, Ruiz Santiago F, Raya Álvarez E. Fibrodysplasia osificante progresiva: comunicación de un caso terminal. Reumatol Clin. 2017;13:303–304.

* Corresponding author.

E-mail address: mari936@hotmail.com (M.d.M. Muñoz Gómez).

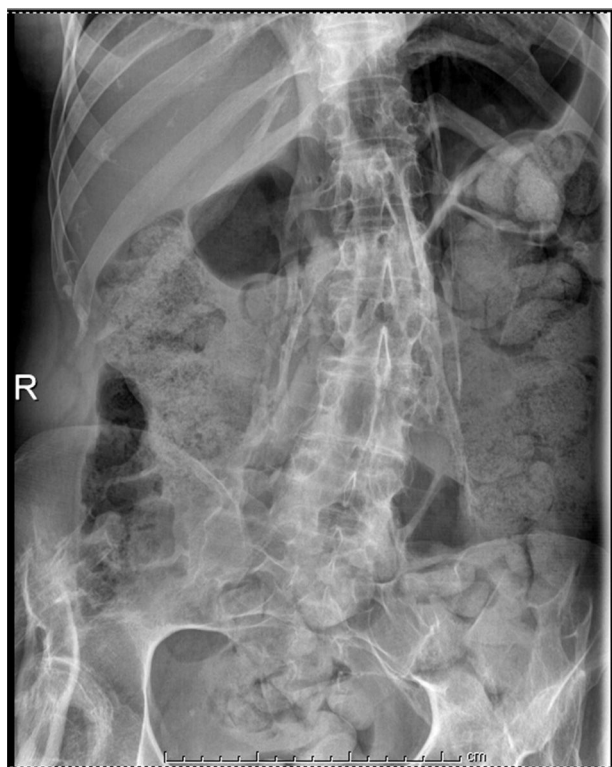


Fig. 2. Radiograph of abdomen showing paravertebral bone bridges that are also seen in right hip.

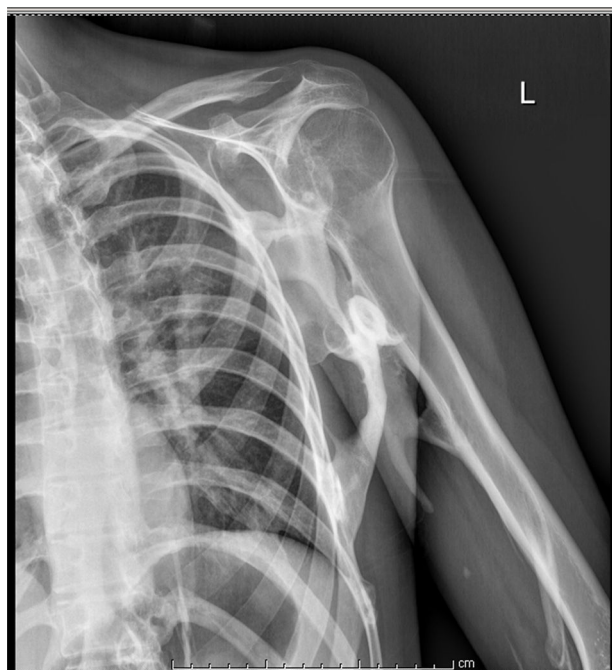

Fig. 3. Radiograph of shoulder showing a well-defined plaque of mature bone between the chest wall, humerus and scapula.

receptor/activin-like kinase 2 (AVCR1/ALK2).^{2,3} Some authors have suggested that blocking the activity of the AVCR1/ALK2 receptor through the development of therapeutic agents that behave like signal transduction inhibitors that encode these proteins may be useful.⁴ In this respect, we know that dorsomorphin, a small molecule produced by the zebrafish, inhibits BMP type I receptors (including ALK2—implicated in the etiology and pathogenesis of the disease—and other activin-like kinases like ALK3 and ALK6)⁵; however, given the lack of specificity of this molecule, further studies are needed in this line of research, as well as the development of *in vivo* models to determine the potential efficacy of this molecule in the prevention of the flares of ossification that occur in this serious disease.

Ethical Disclosures

Protection of human and animal subjects. The authors declare that no experiments were performed on humans or animals for this study.

Confidentiality of data. The authors declare that they have followed the protocols of their work center on the publication of patient data.

Right to privacy and informed consent. The authors have obtained the written informed consent of the patients or subjects mentioned in the article. The corresponding author is in possession of this document.

Conflicts of Interest

The authors declare they have no conflicts of interest.

References

1. Connor JM, Evans DA. Genetic aspects of fibrodysplasia ossificans progressiva. *J Med Genet.* 1982;19:35–9.
2. Kaplan FS, Xu M, Seemann P, Connor JM, Glaser DL, Carroll L, et al. Classic and atypical fibrodysplasia ossificans progressiva (FOP) phenotypes are caused by mutations in the bone morphogenetic protein (BMP) type I receptor ACVR1. *Hum Mutat.* 2009;30:379–90.
3. Morales-Piga A, Bachiller-Corral FJ, Sanchez-Duffhues G. Is fibrodysplasia ossificans progressiva a vascular disease. A groundbreaking pathogenic model. *Reumatol Clin.* 2014;10:389–95.
4. Pignolo RJ, Shore EM, Kaplan FS. Fibrodysplasia ossificans progressiva: diagnosis, management, and therapeutic horizons. *Pediatr Endocrinol Rev.* 2013;10 Suppl. 2:437–48.
5. Yu PB, Hong CC, Sachidanandan C, Babbitt JL, Deng DY, Hoyng SA, et al. Dorsomorphin inhibits BMP signals required for embryogenesis and iron metabolism. *Nat Chem Biol.* 2008;4:33–41.