



Sociedad Española
de Reumatología -
Colegio Mexicano
de Reumatología

Reumatología Clínica

www.reumatologiaclinica.org



Case Report

Relapsed Hydroxychloroquine Induced Thrombocytopenia in Systemic Lupus Erythematosus Patient[☆]



Vanesa Antón Vázquez,^{a,*} Luis Pascual,^a Héctor Corominas Macias,^b Isabel Giménez Torrecilla^c

^a Servicio de Medicina Interna, Hospital Moisès Broggi, Sant Joan Despí, Barcelona, Spain

^b Servicio de Reumatología, Hospital Moisès Broggi, Sant Joan Despí, Barcelona, Spain

^c Servicio de Nefrología, Hospital Moisès Broggi, Sant Joan Despí, Barcelona, Spain

ARTICLE INFO

Article history:

Received 4 March 2016

Accepted 18 April 2016

Available online 17 May 2017

Keywords:

Hydroxychloroquine

Thrombocytopenia

Systemic lupus erythematosus

ABSTRACT

Hydroxychloroquine is used in the long-term therapy of systemic lupus erythematosus (SLE). Although considered to be a safe treatment, side effects have been documented. An uncommon side effect is thrombocytopenia. In order to establish the diagnosis of thrombocytopenia secondary to Hydroxychloroquine, non-pharmacological causes must be ruled out and it is necessary to determine a recurrence after re-exposure to the drug. We present one case of severe thrombocytopenia occurring in a patient with SLE undergoing treatment with Hydroxychloroquine.

© 2016 Elsevier España, S.L.U. and Sociedad Española de Reumatología y Colegio Mexicano de Reumatología. All rights reserved.

Trombocitopenia recurrente inducida por hidroxycloquina en ausencia de actividad del lupus eritematoso sistémico

RESUMEN

La hidroxycloquina es un fármaco antimalárico, empleado como terapia a largo plazo en el lupus eritematoso sistémico (LES). A pesar de considerarse un tratamiento seguro, existen efectos adversos descritos. Uno muy infrecuente es la trombocitopenia. Para establecer el diagnóstico de trombocitopenia causada por hidroxycloquina es necesario descartar otras causas no farmacológicas y objetivar la recurrencia tras la reexposición al fármaco. Presentamos un caso de trombocitopenia severa en un paciente con LES durante el tratamiento con hidroxycloquina.

© 2016 Elsevier España, S.L.U. y Sociedad Española de Reumatología y Colegio Mexicano de Reumatología. Todos los derechos reservados.

Palabras clave:

Hidroxycloquina

Trombocitopenia

Lupus eritematoso sistémico

Introduction

The potential causes of thrombocytopenia are numerous and, depending on the mechanism of action, can be classified into 2 large groups: (1) immune-mediated—secondary to autoimmune diseases, idiopathic thrombocytopenic purpura, infections,

immunodeficiencies and drug-induced; and (2) nonimmune-mediated—drug-induced, bone marrow diseases and congenital.¹

Case Report

The patient was a 27-year-old man who had been diagnosed with systemic lupus erythematosus (SLE) 5 years earlier, as a result of an episode of immune thrombocytopenia and primary peritonitis. The diagnosis revealed antinuclear antibodies (ANA) at a titer of 1:320, negative results for anti-double strand (ds) DNA antibodies, normal levels of complement component C3 and C4, and a systemic lupus erythematosus disease activity index (SLEDAI) of 11. Despite treatment with immunosuppressive agents and maintenance with mycophenolate sodium (360 mg/12 h) and

[☆] Please cite this article as: Vázquez VA, Pascual L, Corominas Macias H, Giménez Torrecilla I. Trombocitopenia recurrente inducida por hidroxycloquina en ausencia de actividad del lupus eritematoso sistémico. Reumatol Clin. 2017;13:294–296.

* Corresponding author.

E-mail address: vanesa.anton.v@gmail.com (V.A. Vázquez).

Table 1

Platelet Count, White Blood Cells, Red Blood Cells, Anti-DNA and Complement According to Exposure to and Interruption of Hydroxychloroquine (HCQ).

	Platelets	Hemoglobin	Leukocytes	Lymphocytes	Anti-DNA	C3	C4
Baseline	$175 \times 10^9/L$	141 g/L	$9.2 \times 10^9/L$	$1.6 \times 10^9/L$	Negative	0.9	0.15
HCQ	$4 \times 10^9/L$	140 g/L	$9.4 \times 10^9/L$	$2 \times 10^9/L$	Negative	1.3	0.13
STOP HCQ	$195 \times 10^9/L$	154 g/L	$8.8 \times 10^9/L$	$1.7 \times 10^9/L$	Negative	1.5	0.22
HCQ	$5 \times 10^9/L$	153 g/L	$10 \times 10^9/L$	$1.8 \times 10^9/L$	Negative	1.1	0.19
STOP HCQ	$250 \times 10^9/L$	148 g/L	$9.5 \times 10^9/L$	$1.5 \times 10^9/L$	Negative	1.0	0.2

hydroxychloroquine (200 mg/day), the patient developed class II lupus nephritis with an activity index of 1/12 and of chronicity of 0/12. Renal biopsy was performed in June 2011: light microscopic study of 10 glomeruli showed moderate focal and segmental mesangial hypercellularity, although there were no lesions indicative of necrotic activity, karyorrhexis, crescents or fuchsinophilic deposits. Cellularity was preserved and there was no tubulointerstitial fibrosis or atrophy. Immunofluorescence of 4 glomeruli was positive, with a pure mesangial glomerular pattern. Some parame-sangial deposits were focally and segmentally isolated. There was no evidence of parietal deposits. Tests revealed IgG–/+, IgA++, C3++, C1q–/+, Kappa+/+ and Lambda+/. Negative findings in vessels, interstitium and tubules.

He had a proteinuria of 5 g/day detected in May 2015 and was admitted to the hospital for another renal biopsy. During his hospital stay, he was found to have asymptomatic thrombocytopenia, 4×10^9 cells/L, with no signs of cellular atypia, negative results on tests for antiplatelet and antihistone antibodies and a SLEDAI of 9. He began to take corticosteroids at a dose of 1 mg/kg body weight (bw)/day, with a diagnosis of autoimmune thrombocytopenia. Immunosuppressive therapy was maintained, and hydroxychloroquine, which was not prescribed, was discontinued. After 48 h, he had a rapid platelet recovery, reaching 195×10^9 cells/L. This enabled the performance of the renal biopsy, which revealed a progression of the lupus nephritis, from class II to class V (membranous glomerulonephritis). Renal biopsy was repeated in July 2015. Light microscopic study ruled out the presence of lesions indicative of proliferative glomerulonephritis; there was no tubulointerstitial fibrosis and immunofluorescence of 5 glomeruli showed a generalized, diffuse glomerular parietal pattern: IgG+++, IgA++, IgM+/-, C3+++, C1q+, Kappa+++ and Lambda+++. Findings in vessels, interstitium and tubules were negative.

At discharge, a different physician again prescribed combined therapy with mycophenolate and hydroxychloroquine (200 mg/day). The patient was readmitted 72 h after discharge due to a new episode of severe thrombocytopenia, with no signs of lupus activity (negative test for anti-dsDNA antibodies and normal C3 and C4 levels). He began to take corticosteroids again (1 mg/kg bw/day), without platelet recovery.

Given the rapid cause-and-effect relationship between hydroxychloroquine and thrombocytopenia, the drug was discontinued intentionally. Within 72 h, the platelet count reached 200×10^9 cells/L (Table 1).

During follow-up, after 1 month, the total platelet count was 250×10^9 cells/L and, in analyses performed 3 and 6 months later,

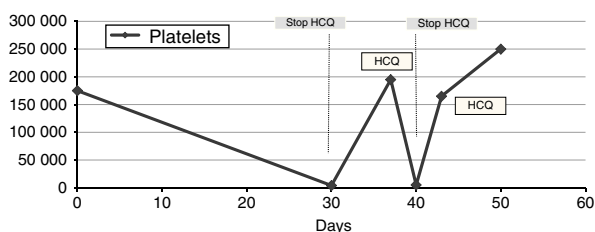


Fig. 1. Changes in platelet counts in relation to exposure to hydroxychloroquine (HCQ).

there had been no decrease (Fig. 1). He began to take tacrolimus because of the progression of nephritis.

Discussion

Drug-induced thrombocytopenia is based on the accelerated destruction of platelets that can occur via 2 different mechanisms: due to direct toxicity acting on the bone marrow or due to peripheral destruction by means of a mechanism that may or may not be immune-mediated by specific antibodies that react with the drug.^{2,3}

The drugs that have been most frequently related to the development of thrombocytopenia are cinchona alkaloids (quinine/quinidine), sulfonamides, nonsteroidal anti-inflammatory drugs, diuretics, anticonvulsants, tuberculostatic drugs and heparins.^{3,4}

The diagnosis of drug-induced thrombocytopenia is established by exclusion, by interrupting administration of the drug and by the detection of drug-dependent antibodies. The temporal relationship between the administration of the treatment and the development of thrombocytopenia is highly important, as is recurrence after re-exposure to the drug.^{4,5} In our patient, the discontinuance of the medication was used as a method of exclusion.

Reaching the definitive diagnosis in the case we report was complex, given that the first manifestation of SLE in our patient was thrombocytopenia. There is a form of clinical presentation in SLE consisting of chronic thrombocytopenia with a slight response to corticosteroids.⁶ Thus, the initial diagnostic suspicion focused on the exacerbation of the lupus activity, in a patient in whom, moreover, the disease had progressed to renal involvement.

Hydroxychloroquine is an antimalarial drug employed in the treatment of lupus and other rheumatic diseases. A number of retrospective studies have shown the efficacy of hydroxychloroquine in the treatment of the autoimmune thrombocytopenia associated with SLE. The authors recommend that the medication not to be discontinued, even in advanced stages of lupus nephritis. Nevertheless, the secondary effects of that drug include thrombocytopenia,⁷ although it is not a common adverse effect, given that there are only isolated cases reported in the literature.^{8–10}

Conclusion

Finally, we consider this case to be of clinical and practical interest, because the cause of the thrombocytopenia was related to hydroxychloroquine and not to the lupus activity, which at all times was clinically and serologically inactive, despite the severity of the thrombocytopenia.

Ethical Disclosures

Protection of human and animal subjects. The authors declare that no experiments were performed on humans or animals for this study.

Confidentiality of data. The authors declare that they have followed the protocols of their work center on the publication of patient data.

Right to privacy and informed consent. The authors have obtained the written informed consent of the patients or subjects mentioned in the article. The corresponding author is in possession of this document.

Conflicts of Interest

The authors declare they have no conflicts of interest.

References

1. Provan D, Stasi R, Newland AC, Blanchette VS, Bolton-Maggs P, Bussel JB, et al. International consensus report on the investigation and management of primary immune thrombocytopenia. *Blood*. 2010;115:168–86.
2. Aster RH, Curtis BR, McFarland JG, Bougie DW. Drug induced immune thrombocytopenia: pathogenesis, diagnosis and management. *J Thromb Haemost*. 2009;7:911–8.
3. Aster RH, Bougie DW. Drug-induced immune thrombocytopenia. *N Engl J Med*. 2007;357:580–7.
4. Ten Berg MJ, Huisman A, Souverein PC, Achinen AF, Egberts AC, van Solinge WW. Drug-induced thrombocytopenia: a population study. *Drug Saf*. 2006;29:713–21.
5. Seco-Melantuche R, Delgado-Sánchez O, Álvarez-Arroyo L. Incidencia de trombocitopenia inducida por fármacos en pacientes hospitalizados. *Farm Hosp*. 2013;37:27–34.
6. Keeling D, Isenber D. Haematological manifestations of systemic lupus erythematosus. *Blood Rev*. 1993;7:199–207.
7. Nieweg HO, Bouma HG, Devries K, Jansz A. Haematological side-effects of some anti-rheumatic drugs. *Ann Rheum Dis*. 1963;22:440–3.
8. Demir D, Öcal F, Abanoz M, Dermenci H. A case of thrombocytopenia associated with the use of hydroxychloroquine following open heart surgery. *Int J Surg Case Rep*. 2014;5:1282–4.
9. Caminal L, González A, Ferro J, Susano R. Thrombopenia secondary to hydroxychloroquine. *An Med Interna*. 1994;11:310.
10. Wijnands MJ, Allebes WA, Boerbooms AM, van de Putte LB. Thrombocytopenia due to aurothioglucose, sulphasalazine, and hydroxychloroquine. *Ann Rheum Dis*. 1990;49:798–800.