

malignancy (leukemia); these effects are potentiated with the simultaneous use of cyclosporine A. For refractory HLH, it is recommended that there be an initial induction phase (2 weeks) with etoposide, cyclosporine A and dexamethasone,^{4,5} to be followed by 6 weeks of etoposide, if necessary.⁵ The utilization of this medication is still controversial, and there is a lack of consensus as to fully recommending its use because of paradoxical effects involving myelosuppression. This alternative is recommended only in refractory cases.^{5,6} Etoposide has been previously utilized in 8 patients with MAS and induced a favorable and rapid response in each case, with no adverse effects.^{7–9}

In this instance, etoposide was added because the patient showed resistance to standard therapy. She received only 3 doses because of its high toxicity and the development of pancytopenia. The strategy we employed was successful; however, it proposes a strict control of the etoposide combined with the suggested treatment.

We presented MAS, a condition that is not very common, that was refractory to standard treatment. Thus, we opted for the use of etoposide. The patient we report progressed favorably. Nevertheless, as it is just a single case, we do not recommend generalizing this approach. The outcome can be taken into account in future studies that attempt to establish a complete scheme for the treatment of refractory reactive HLH.

References

- Torres A, Solís E, Zeferino M, Céspedes C, Sánchez B. Síndrome de activación de macrófago como manifestación inicial de lupus eritematoso sistémico severo de inicio juvenil. Respuesta favorable a ciclofosfamida. *Reumatol Clin.* 2014;10:331–5.
- Ravelli A. Macrophage activation syndrome. *Curr Opin Rheumatol.* 2002;14:548–52.
- Sawhney S, Woo P, Murray KJ. Macrophage activation syndrome: a potentially fatal complication of rheumatic disorders. *Arch Dis Child.* 2001;85:421–6.
- Bode SF, Lehmborg K, Maul-Pavicic A, Vraetz T, Janka G, Stadt UZ, et al. Recent advances in the diagnosis and treatment of hemophagocytic lymphohistiocytosis. *Arthritis Res Ther.* 2012;14:213.
- Henter JL, Horne A, Arico M, Egeler RM, Filipovich AH, Imashuku S, et al. HLH-2004: diagnostic and therapeutic guidelines for hemophagocytic lymphohistiocytosis. *Pediatr Blood Cancer.* 2007;48:124–31.
- Boom V, Anton J, Lahdenne P, Quartier P, Ravelli A, Wulffraat NM, et al. Evidence-based diagnosis and treatment of macrophage activation syndrome in systemic juvenile idiopathic arthritis. *Pediatr Rheumatol Online J.* 2015;13:55.
- Cortis E, Insalaco A. Macrophage activation syndrome in juvenile idiopathic arthritis. *Acta Paediatr Suppl.* 2006;95:38–41.
- Miettunen PM, Narendran A, Jayanthan A, Behrens EM, Cron RQ. Successful treatment of severe paediatric rheumatic disease-associated macrophage activation syndrome with interleukin-1 inhibition following conventional immunosuppressive therapy: case series with 12 patients. *Rheumatology (Oxford).* 2011;50:417–9.
- Prahalad S, Bove KE, Dickens D, Lovell DJ, Grom AA. Etanercept in the treatment of macrophage activation syndrome. *J Rheumatol.* 2001;28:2120–4.

Leslye F. Conde,^{a,*} Karla P. Aedo,^a
Tatiana Miraval-Niño de Guzmán^{a,b}

^a Escuela de Medicina, Universidad Peruana de Ciencias Aplicadas, Lima, Peru

^b Departamento de Enfermedades Sistémicas, Hospital Nacional Edgardo Rebagliati Martins, Lima, Peru

* Corresponding author.

E-mail address: leslyecondeb@gmail.com (L.F. Conde).

2173-5743/

© 2016 Elsevier España, S.L.U. and Sociedad Española de Reumatología y Colegio Mexicano de Reumatología. All rights reserved.

Osteoid Osteoma of the Knee Mimicking Juvenile Psoriatic Arthritis^{*}



Osteoma osteoide de rodilla simulando artritis psoriásica juvenil

To the Editor,

We read very attentively the letter by Moreno-Martinez et al.,¹ who describe a case of pelvic osteoid osteoma (OO), in which the clinical signs and symptoms were compatible with sacroiliitis. We would like to report another OO that developed in knee, that suggested a diagnosis of juvenile psoriatic arthritis (JPA).

A 15-year-old boy presented with an 8-month history of mechanical pain in right knee. It would be intermittent at first and later become continuous, making it difficult for him to walk, and swelling was observed in that area. The treatment consisted of nonsteroidal anti-inflammatory drugs (NSAID), initially ibuprofen, which was replaced by diclofenac, but there was no improvement. He had no history of injury, fever or constitutional symptoms, or manifestations affecting any other peripheral or axial joint or enthesitis. He had been diagnosed with guttate psoriasis at the age of 10 years, with occasional episodes until he was 13, and was treated with topical glucocorticoids; however, he had no family history of psoriasis, psoriatic arthritis, ankylosing spondylitis or inflammatory bowel disease. Physical examination revealed

muscle atrophy in distal thigh and swelling in right infrapatellar region, which was warm, and he had a limitation in last few degrees of flexion, but with no signs of joint effusion. The results of laboratory tests, including biochemical analyses, complete blood count and acute-phase reactants (erythrocyte sedimentation rate 6 mm/h, C-reactive protein 2.31 mg/dL) were normal. Human leukocyte antigen (HLA) typing revealed the presence of Cw6, DR4 and DQ8 haplotypes, but not B27, and the patient was negative for rheumatoid factor and antinuclear antibodies. Plain radiography of the knees showed a sclerotic area in the upper third of right tibia (Fig. 1A and B), which, according to computed tomography (CT), corresponded to an osteolytic lesion measuring 5 mm in diameter in anterior tibial tuberosity, with a “nidus” formed by an ossified matrix, compatible with OO (Fig. 2B and C), with extensive sclerosis of the medullary bone and a solid periosteal reaction in the adjacent cortical bone. Magnetic resonance revealed intense contrast uptake in and around the lesion, as well as in the surrounding bone edema and the Hoffa fat pad (Fig. 2C and D). Bone scintigraphy disclosed hyperemia and a focal increase in the osteogenic response in the proximal epiphysis of right tibia, with no other significant changes. The patient underwent CT-guided radiofrequency ablation, and the pain disappeared a few days after the procedure, and he recovered complete mobility 1 month later, although he had mild persistent muscle atrophy.

Osteoid osteoma is a relatively common, benign bone neoplasm that constitutes between 10% and 12% of benign bone tumors. It usually develops between the ages of 10 and 20 years (although it has been reported in smaller children), and the ratio of males-to-females is 2–3:1.^{2,3} It most often affects the lower limbs, and is

^{*} Please cite this article as: Boteanu AL, Sifuentes-Giraldo WA, Antón-Pagés F, Gámir-Gámir ML. Osteoma osteoide de rodilla simulando artritis psoriásica juvenil. *Reumatol Clin.* 2017;13:240–242.

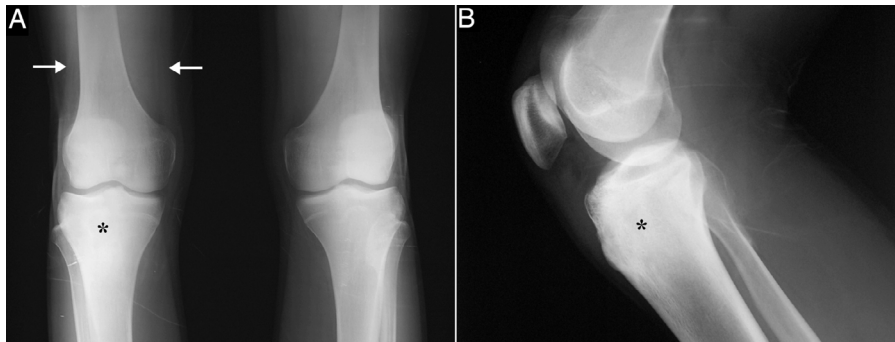


Fig. 1. Anteroposterior radiographs of both knees (A) and lateral view of right knee (B) showing sclerosis in upper third of right tibia (asterisks) with no apparent “nidus”, and a reduction in the volume of the distal third of the quadriceps due to muscle atrophy (arrows).

located in the femur and tibia in 50% to 60% of the cases, with a predilection for cortical bone, involving the diaphysis, the metaphysis or, rarely, the epiphysis.⁴ Nocturnal pain is predominant, and if it is not related to physical activity, becomes more severe during rest and is relieved by salicylates or NSAID, it is highly suggestive of OO²⁻⁴; however, when its location is juxta- or intra-articular, its presentation may be atypical and mimic other disorders, like oligoarticular juvenile idiopathic arthritis (JIA), and can be accompanied by limping, muscle atrophy, synovitis, contractures and dysmetria of the lower limbs.^{2,3,5-8} This leads to a delay in the diagnosis, que is usually more than 6 months and ranges between 13.8 and 28 months.⁹ In our patient, the diagnosis that was initially

proposed was JPA, a category of the classification of the International League of Associations for Rheumatology (ILAR) for JIA, defined as arthritis in a patient under 16 years of age, with a duration of at least 6 weeks, associated with psoriasis or with 2 of the following characteristics: dactylitis, nail pitting, onycholysis or psoriasis in a first-degree relative.¹⁰ However, the swelling observed actually corresponded to inflammatory changes in the adjacent infrapatellar fat pad (“Hoffitis”), rather than being a sign of synovitis. As the radiographic findings may also be atypical or the “nidus” not be clearly evident, CT is the best technique for detecting it in these cases.⁷⁻⁹ Thus, OO should be taken into account in the differential diagnosis of a long history of pain in a single joint, especially

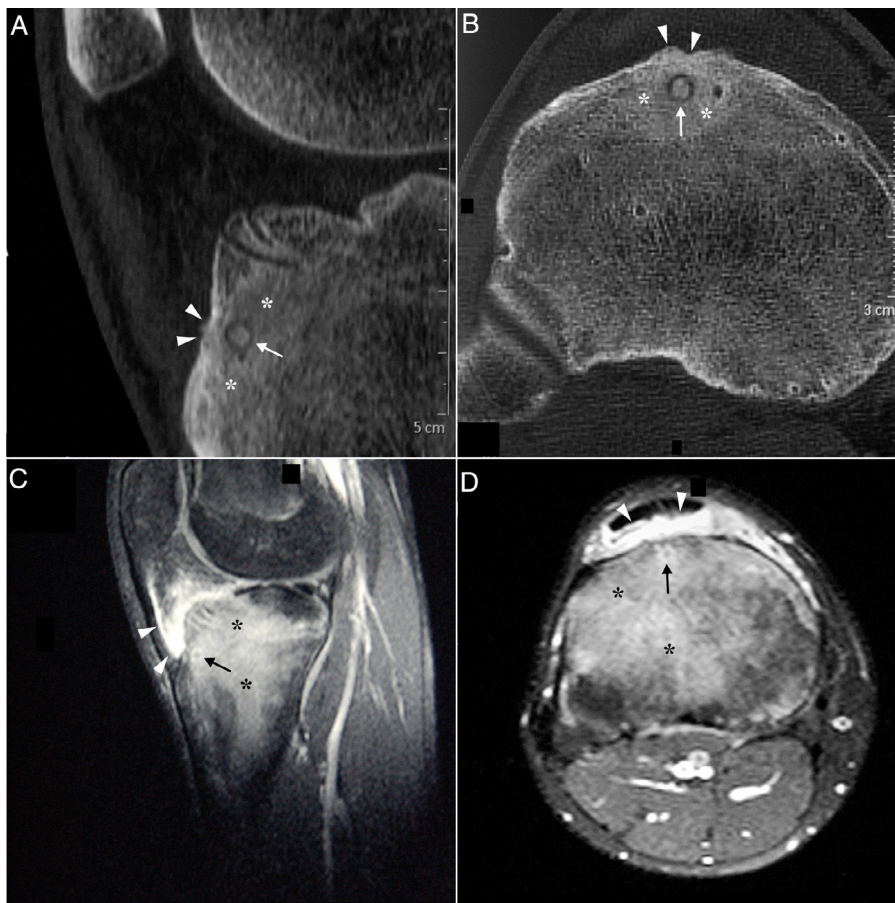


Fig. 2. Sagittal (A) and axial (B) computed tomography images of right knee showing an osteolytic lesion in the subendosteal region of the anterior tibial tuberosity, with a “nidus” formed by ossified matrix, compatible with osteoid osteoma (arrow), encircled by extensive sclerosis of the surrounding medullary bone (asterisks) and a solid periosteal reaction in the adjacent cortical bone (arrowheads). Post-gadolinium sagittal (C) and axial (D) T1-weighted spectral presaturation with inversion recovery (STIR) magnetic resonance images revealed perilesional contrast uptake in the form of a ring (arrow), and in surrounding bone edema (asterisks) and Hoffa fat pad (arrowheads).

in children and adolescents with knee pain or monoarthritis with atypical features and/or a poor response to treatment.^{5,7,9}

References

- Moreno-Martínez MJ, Moreno-Ramos MJ, Díaz-Navarro MJ, Linares-Ferrando LF. Osteoma osteoide pélvico simulando sacroileitis. *Reumatol Clin.* 2016;12:177–8.
- Allen R, Tiedemann K. Skeletal malignancies and related disorders. In: Petty R, Laxer R, Lindsley C, Wedderburn L, editors. *Textbook of Pediatric Rheumatology*. Philadelphia: Elsevier Saunders; 2016. p. 650–62.
- Massei F, Laccetta G, Barrani M, Fabbri L, Zampa V, Paolicchi A, et al. Osteoid osteoma mimicking monoarticular juvenile idiopathic arthritis in a girl. *Pediatr Int.* 2016;58:791–4.
- Kitsoulis P, Mantellos G, Vlychou M. Osteoid osteoma. *Acta Orthop Belg.* 2006;72:119–25.
- Georgoulis AD, Soucacos PN, Beris AE, Xenakis TA. Osteoid osteoma in the differential diagnosis of persistent joint pain. *Knee Surg Sports Traumatol Arthrosc.* 1995;3:125–8.
- Christodoulou A, Ploumis A, Karkavelas G, Terzidis I, Tzagias I. A rare case of juxta-articular osteoid osteoma of the calcaneus initially misdiagnosed as juvenile chronic arthritis. *Arthritis Rheum.* 2003;48:776–9.
- Traore SY, Dumitriu DI, Docquier PL. Intra-articular osteoid osteoma mimicking juvenile arthritis. *Case Rep Orthop.* 2014;2014:912609.
- Szendroi M, Köllö K, Antal I, Lakatos J, Szoke G. Intraarticular osteoid osteoma: clinical features, imaging results, and comparison with extraarticular localization. *J Rheumatol.* 2004;31:957–64.
- Bea Muñoz M, Jiménez Álvarez M, Pérez Vallina JR, Medina Sánchez M. Osteoid osteoma of the proximal femur presenting as knee pain: a well-known problem difficult to diagnose. *An Pediatr (Barc).* 2009;71:89–90 [article in Spanish].
- Petty RE, Southwood TR, Manners P, Baum J, Glass DN, Goldenberg J, et al. International League of Associations for Rheumatology classification of juvenile idiopathic arthritis: second revision, Edmonton, 2001. *J Rheumatol.* 2004;31:390–2.

Alina Lucica Boteanu,^a Walter Alberto Sifuentes-Giraldo,^{a,*}
Fred Antón-Pagés,^b María Luz Gámir-Gámir^a

^a Unidad de Reumatología Pediátrica, Hospital Universitario Ramón y Cajal, Madrid, Spain

^b Servicio de Reumatología, Complejo Asistencial Universitario de Palencia, Palencia, Spain

* Corresponding author.

E-mail address: albertosifuentesg@gmail.com

(W.A. Sifuentes-Giraldo).

2173-5743/

© 2016 Elsevier España, S.L.U. and Sociedad Española de Reumatología y Colegio Mexicano de Reumatología. All rights reserved.

A Case Report of Gaucher Disease[☆]



Enfermedad de Gaucher: a propósito de un caso

To the Editor,

Gaucher disease (GD), described in 1882 by Philippe Charles Ernest Gaucher, is a progressive, rare hereditary disease, with an autosomal recessive inheritance pattern.¹ Included in the group of lysosomal storage diseases, it is characterized as being the most prevalent, with an estimated frequency of 1 per 50,000 to 1 per 100,000 population, with the exception of the Ashkenazi Jewish ethnicity in which the incidence is estimated to be 1 per 850 births.^{2,3} It produces a deficiency in the activity of the enzyme acid β -glucosidase (GBA), provoking an accumulation of glucocerebroside in the lysosomes of different cells,⁴ causing cytopenias, hepatosplenomegaly, changes in the central nervous system (CNS) and skeletal manifestations, the latter being one of the most disabling aspects. Depending on the clinical expression, different types can be distinguished: type 1 (adult non-neuronopathic), the most common form, occurring frequently in Ashkenazi Jews, with variable manifestations, and not involving the CNS; type 2 (acute neuronopathic), infrequent, with no ethnic-related dominance, fatal after birth and involvement of the CNS; and type 3 (subacute or chronic neuronopathic),⁴ beginning during childhood, adolescence or adulthood, with involvement of the CNS. Given the variety of conditions associated with bone pain, we consider it appropriate to report the case of our patient.

The patient was a 53-year-old man with no significant family or personal history. He was being studied because of neutropenia and thrombocytopenia with a duration of 10 years, as well as bone pain that had started 3 years earlier. He reported no hemorrhagic diathesis, infections or abdominal pain. Physical examination revealed splenomegaly, but the rest was normal. The results of

laboratory tests included a leukocyte count of 3400 mm³, neutrophils at 1200/mm³ and platelets at 93,000 mm³; findings regarding hemoglobin, reticulocytes, coagulation, serum electrolytes, liver function, vitamin B₁₂, folic acid, tumor markers (carcinoembryonic antigen, alpha-fetoprotein, CA 19-9, CA 15-3, prostate-specific antigen), β_2 -microglobulin, rheumatoid factor, erythrocyte sedimentation rate, antinuclear antibodies, immunoglobulins, protein profile and lymphocyte populations were normal. Serologic tests for hepatitis B and C viruses and human immunodeficiency virus were negative. Plain radiography of distal femur and thoracolumbar spine were normal. However, lumbar magnetic resonance showed a homogeneous hypointense signal in the vertebral bodies on T1 and T2-weighted sequences. Splenomegaly was confirmed by abdominal ultrasound and osteoporosis by bone densitometry (T-score femur: -2.9 standard deviations (SD); T-score spine: -2.8 SD). Bone marrow aspirate/biopsy (BMA/BMB)

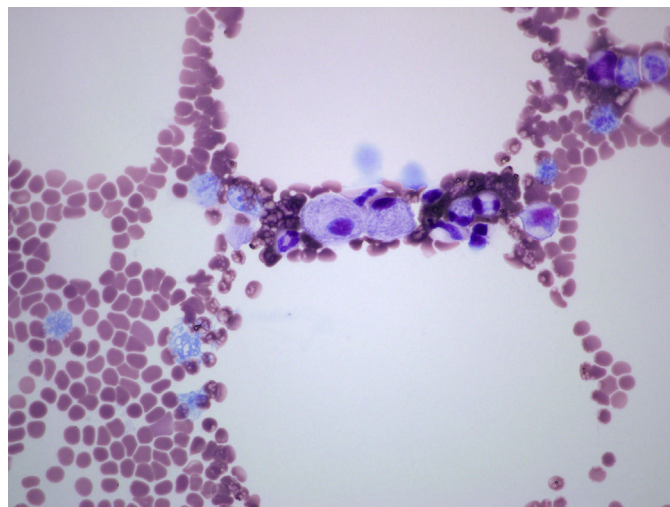


Fig. 1. Gaucher cells.

[☆] Please cite this article as: Herráez-Albendea MM, Fernández-Cofrades EG, Jarilla-Fernández MC, Jiménez-Burgos F. Enfermedad de Gaucher: a propósito de un caso. *Reumatol Clin.* 2017;13:242–243.