



Sociedad Española  
de Reumatología -  
Colegio Mexicano  
de Reumatología

# Reumatología Clínica

www.reumatologiaclinica.org



## Images in Clinical Rheumatology

### Upper Gastrointestinal Bleeding (Watermelon Stomach) in a Patient With Limited Scleroderma (CREST Syndrome)<sup>☆</sup>



### Hemorragia digestiva alta (estómago de sandía) en paciente con esclerodermia limitada (síndrome de CREST)

Ana Isabel Turrión Nieves,<sup>a,b,\*</sup> Henry Moruno Cruz,<sup>a</sup> M. Liz Romero Bogado,<sup>a</sup> Ana Perez Gómez<sup>a</sup>

<sup>a</sup> Servicio de ESI-Reumatología, Departamento de Medicina Especialidades Médicas, Hospital Universitario Príncipe de Asturias, Alcalá de Henares, Madrid, Spain

<sup>b</sup> Unidad Docente de Anatomía y Embriología Humanas, Departamento de Cirugía y Ciencias Médico Sociales, Universidad de Alcalá de Henares, Alcalá de Henares, Madrid, Spain

#### ARTICLE INFO

##### Article history:

Received 16 January 2016

Accepted 26 May 2016

Available online 13 July 2017

The patient was a 52-year-old man with a 20-year history of limited scleroderma, as well as antiphospholipid syndrome. He was positive for antinuclear antibodies (1:2560), with a centromere pattern, and for lupus anticoagulant, and was receiving oral anti-coagulants due to thrombosis in a lower limb.

He was admitted to the hospital with an episode of blood in stool and evidence of anemia. Endoscopic study revealed vascular-like lesions in antrum converging as they neared the pylorus, compatible with watermelon stomach<sup>1,2</sup> (Fig. 1). In the presence of active bleeding, he was treated with argon plasma coagulation<sup>3</sup> (Fig. 2).

Gastric antral vascular ectasia (GAVE) is a rare, but serious, cause of upper gastrointestinal bleeding (4% of all gastric hemorrhages). The endoscopic findings are characteristic: linear images, oriented radially and converging on the pylorus (watermelon stomach<sup>1,4</sup>).

This condition is associated with underlying chronic diseases, mostly with liver cirrhosis. In autoimmune diseases, it is related to the presence of Raynaud's phenomenon, and is the form most widely reported of the limited subtype of scleroderma (calcinosis, Raynaud's phenomenon, esophageal dysmotility, sclerodactyly, telangiectasia [CREST syndrome]).<sup>5,6</sup> The largest series of patients with GAVE includes 45 individuals, 62% of whom also had a connective tissue disease, predominantly with Raynaud's phenomenon (31%) and sclerodactyly (20%).<sup>7</sup>

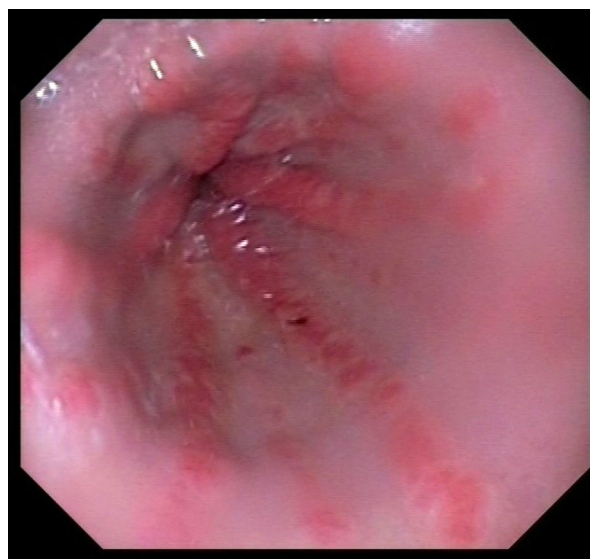


Fig. 1. Endoscopic images of gastric antral vascular ectasia.

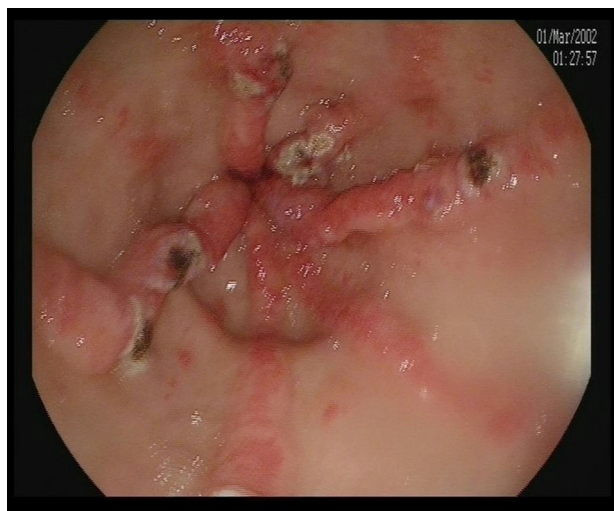
The etiology and pathogenesis of GAVE are unknown; one hypothesis is that the histological changes, especially in the lamina propria, are due to a fibromuscular proliferation, vascular dilatation and thrombosis, caused by the vascular disease associated with this condition.<sup>8</sup> It can be suspected in patients with scleroderma and iron deficiency anemia who do not respond to iron supplements.

At the present time, we are unable to avoid its development and, given the presence of bleeding, the treatment with the best results

<sup>☆</sup> Please cite this article as: Turrión Nieves AI, Moruno Cruz H, Romero Bogado ML, Perez Gómez A. Hemorragia digestiva alta (estómago *watermelon*) en paciente con esclerodermia limitada (síndrome de CREST). Reumatol Clin. 2017;13:361–362.

\* Corresponding author.

E-mail address: [anaturrion@hotmail.com](mailto:anaturrion@hotmail.com) (A.I. Turrión Nieves).



**Fig. 2.** Endoscopic image of vascular ectasia treated with argon plasma coagulation.

is endoscopic, including the use of laser ablation, argon plasma coagulation or cold. With respect to the possible surgical solution, like antrectomy, it can be utilized if other therapies fail.<sup>9,10</sup> There are medical treatments if endoscopy cannot be performed, but they are usually associated with more severe adverse effects.

#### Ethical Disclosures

**Protection of human and animal subjects.** The authors declare that no experiments were performed on humans or animals for this study.

**Confidentiality of data.** The authors declare that they have followed the protocols of their work center on the publication of patient data.

**Right to privacy and informed consent.** The authors declare that no patient data appear in this article.

#### Conflicts of Interest

The authors declare they have no conflicts of interest.

#### References

1. Elkayam O, Oumanski M, Yaron M, Caspi D. Watermelon stomach following and preceding systemic sclerosis. *Semin Arthritis Rheum.* 2000;30:127–31.
2. Fuccio L, Mussetto A, Laterza L, Eusebi LH, Bazzoli F. Diagnosis and management of gastric antral vascular ectasia. *World J Gastrointest Endosc.* 2013;5:6–13.
3. Forbes A, Marie I. Gastrointestinal complications: the most frequent internal complications of systemic sclerosis. *Rheumatology (Oxford).* 2009;48 Suppl 3:iii36–9.
4. Kar P, Mitra S, Resnick JM, Torbey CF. Gastric antral vascular ectasia: case report and review of the literature. *Clin Med Res.* 2013;11:80–5.
5. Ghrenassia E, Avouac J, Khanna D, Derk CT, Distler O, Suliman YA, et al. Prevalence, correlates and outcomes of gastric antral vascular ectasia in systemic sclerosis: a EUSTAR case-control study. *J Rheumatol.* 2014;41:99–105.
6. Parrado RH, Lemus HN, Coral-Alvarado PX, Quintana López G. Gastric antral vascular ectasia in systemic sclerosis: current concepts. *Int J Rheumatol.* 2015;2015:762546.
7. Gostout CJ, Viggiano TR, Ahlquist DA, Wang KK, Larson MV, Balm R. The clinical and endoscopic spectrum of the watermelon stomach. *J Clin Gastroenterol.* 1992;15:256–63.
8. Selinger CP, Ang YS. Gastric antral vascular ectasia (GAVE): an update on clinical presentation, pathophysiology and treatment. *Digestion.* 2008;77:131–7.
9. Swanson E, Mahgoub A, MacDonald R, Shaikat A. Medical and endoscopic therapies for angiodysplasia and gastric antral vascular ectasia: a systematic review. *Clin Gastroenterol Hepatol.* 2014;12:571–82.
10. Zulli C, del Prete A, Romano M, Esposito F, Amato MR, Esposito P. Refractory gastric antral vascular ectasia: a new endoscopic approach. *Eur Rev Med Pharmacol Sci.* 2015;19:4119–22.