



Sociedad Española  
de Reumatología -  
Colegio Mexicano  
de Reumatología



## Images in Clinical Rheumatology

### Van Neck-Odelberg Disease: Another Cause of Limp in Childhood<sup>☆</sup>



### Enfermedad de Van Neck-Odelberg: una causa más de cojera en la infancia

Isla Morante Bolado,<sup>a,\*</sup> Marina Ortega Navaridas,<sup>b</sup> Daniel Clemente Garulo,<sup>c</sup>  
Juan Carlos López Robledillo<sup>c</sup>

<sup>a</sup> Servicio de Reumatología, Hospital Universitario Central de Asturias, Oviedo, Asturias, Spain

<sup>b</sup> Servicio de Pediatría, Hospital Infantil Universitario Niño Jesús, Madrid, Spain

<sup>c</sup> Servicio de Reumatología Pediátrica, Hospital Infantil Universitario Niño Jesús, Madrid, Spain

#### ARTICLE INFO

##### Article history:

Received 23 December 2015

Accepted 11 July 2016

Available online 13 July 2017

#### Introduction

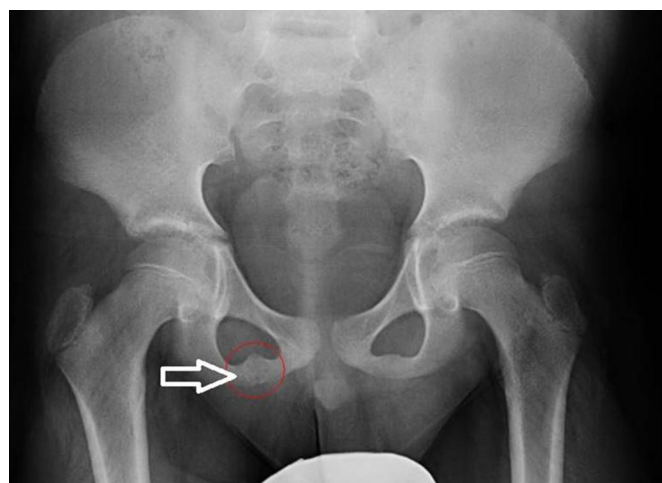
Ischiopubic synchondrosis (IPS) is a temporary joint that exists only in childhood, during bone maturation. On occasion it produces pain, whereas on others, it is an incidental finding revealed by plain radiography. Given its tumor-like aspect, it is necessary to perform magnetic resonance imaging (MRI) to differentiate it from pathological conditions.

#### Case Report

The patient was an 8-year-old boy with no significant medical history. He reported that, for the last year, he was having weekly episodes of intense pain in right lower limb that lasted at least an hour. The pain was located in anterior aspect of his thigh and gluteal region, and limited his mobility. He had no fever or constitutional symptoms. The clinical signs and symptoms remitted with rest and the usual analgesics.

Physical examination confirmed that the child was obese (body mass index = 24; >97th percentile). There was no evidence of inflammation, limitation of mobility or neurological deficits. Complete blood count, laboratory tests and acute-phase reactants were normal.

An anteroposterior radiograph of the pelvis (Fig. 1) revealed enlargement of right-sided IPS, with small irregularities of pseudotumoral aspect. Magnetic resolution produced (Fig. 2) an



**Fig. 1.** Anteroposterior radiograph of pelvis: swelling of right ischiopubic synchondrosis.

asymmetrical and irregular image, like a “fibrous bridge”, affecting right ischiopubic syndesmosis (T1) and a hyperintense signal with associated soft-tissue edema in T2-weighted and short tau inversion recovery (STIR) sequences. This is all compatible with a diagnosis of “Van Neck-Odelberg osteochondritis”.

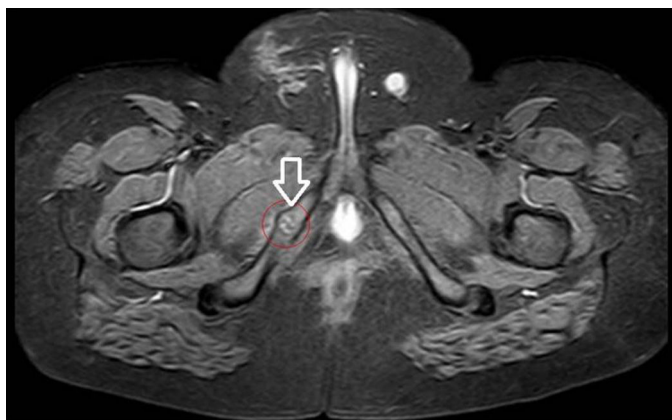
#### Discussion

Van Neck-Odelberg disease is a benign process that develops in children between the ages of 4 and 16 years. It is characterized by

<sup>☆</sup> Please cite this article as: Morante Bolado I, Ortega Navaridas M, Clemente Garulo D, López Robledillo JC. Enfermedad de Van Neck-Odelberg: una causa más de cojera en la infancia. Reumatol Clin. 2017;13:299–300.

\* Corresponding author.

E-mail address: [islamorantebolado@gmail.com](mailto:islamorantebolado@gmail.com) (I. Morante Bolado).



**Fig. 2.** Axial magnetic resonance imaging (short tau inversion recovery) of pelvis: swelling of right ischiopubic synchondrosis, with irregular margins. Signal alteration in bone marrow and edema of the surrounding soft tissue.

pain in the lower limb due to osteochondritis of the ischiopubic ramus.<sup>1,2</sup>

There is swelling of the IPS with no clinical manifestations, but it can be associated with pain in the thigh, groin region or buttock, with limitation of the mobility of the extremity and limping.<sup>3</sup>

Plain radiography usually shows an enlargement of the synchondrosis with radiolucent and osteolytic areas. The typical MRI findings include changes in bone marrow and perilesional soft-tissue edema.<sup>2–4</sup>

The tumor-like appearance in radiographs may lead to a diagnosis of stress fracture, an infectious process or tumor.<sup>1–5</sup> The absence of fever and normal results on laboratory tests facilitates the differential diagnosis.<sup>1</sup>

This condition usually has a favorable outcome after 2 or 3 weeks of anti-inflammatory therapy and rest.<sup>2,3,5,6</sup>

## Ethical Disclosures

**Protection of human and animal subjects.** The authors declare that no experiments were performed on humans or animals for this study.

**Confidentiality of data.** The authors declare that they have followed the protocols of their work center on the publication of patient data.

**Right to privacy and informed consent.** The authors declare that no patient data appear in this article.

## Conflicts of Interest

The authors declare they have no conflicts of interest.

## References

1. Wait A, Gaskill T, Sarwar Z, Busch M. Van Neck disease: osteochondrosis of the ischiopubic synchondrosis. *J Pediatr Orthop.* 2011;31:520–4.
2. Schwartzman P, Varela A, Alarcón V, Salgado D, Mondello E. Síndrome de sinchondrosis isquiopúbica. Enfermedad de Van Neck-Odelberg. *Rev Argent Radiol.* 2015;79:110–2.
3. Macarini L, Lallo T, Miliillo T, Muscarella S, Vinci R, Stoppino LP. Case report: multimodality imaging of van Neck-Odelberg disease. *Indian J Radiol Imaging.* 2011;1:107–10.
4. Ceroni D, Mousny M, Anooshiravani-Dumont M, Buerge-Edwards A, Kaelin A. MRI abnormalities of the ischiopubic synchondrosis in children: a case report. *Acta Orthop Belg.* 2004;70:283–6.
5. Herneth AM, Philipp MO, Pretterklieber ML, Balassy C, Winkelbauer FW, Beaulieu CF. Asymmetric closure of the ischiopubic synchondrosis in pediatric patients: correlation with foot dominance. *AJR Am J Roentgenol.* 2004;182:361–5.
6. Oliveira F. Differential diagnosis in painful ischiopubic synchondrosis (IPS): a case report. *Iowa Orthop J.* 2010;30:195–200.