

## Interstitial Granulomatous Dermatitis Associated With Lupus: A Case Report<sup>☆</sup>

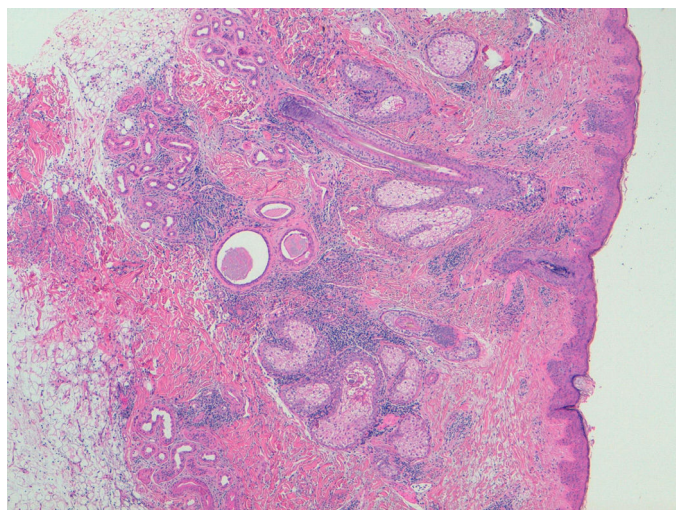


### *Dermatitis intersticial granulomatosa asociada al lupus: a propósito de un caso*

To the Editor,

Recently, we treated a patient with interstitial granulomatous dermatitis (IGD) associated with systemic lupus erythematosus (SLE). Given the refractoriness of the condition to standard therapy, treatment with belimumab was begun, and the response was satisfactory. In view of the absence of data in the literature on the efficacy of belimumab in IGD associated with SLE, the report of this case was considered to be interesting, as it would enable us to examine new therapeutic lines in refractory IGD.

The patient was a 40-year-old white man who had been diagnosed with SLE at the age of 35 on the basis of leukopenia, oral and nasal ulcers, arthritis of the hands, myositis and cutaneous involvement in the form of diffuse alopecia. He was also positive for immunological markers (antinuclear, anti-Smith, anti-Ro and anti-double-stranded DNA antibodies) and had decreased complement levels. Given the predominance of joint involvement, at first, he was treated with prednisone at 10 mg/day and hydroxychloroquine at 400 mg/day. There was a partial response in the joints, but none with respect to the skin. He had a substantial deterioration of the cutaneous manifestations, developing patches of alopecia areata, palpebral edema and nonpruritic, erythematous violaceous macular lesions on his face, torso and proximal portion of extremities, producing a serious physical and psychological distress for the patient. In addition, he had constitutional symptoms, with fever and an elevation of serum markers of lupus activity. A biopsy of the skin lesions revealed an interstitial lymphohistiocytic infiltrate in superficial and deep dermis, with the presence of mucin deposits arranged around collagen fibers, corresponding histopathologically to IGD (Fig. 1). It was decided to treat the patient



**Fig. 1.** Histological image of a skin biopsy. The interstitial lymphohistiocytic infiltrate can be observed in superficial and deep dermis, with the presence of mucin deposits surrounding the collagen fibers. Histopathological view of interstitial granulomatous dermatitis.

<sup>☆</sup> Please cite this article as: Arévalo M, Moreno M, Gratacós J. Dermatitis intersticial granulomatosa asociada al lupus: a propósito de un caso. Reumatol Clin. 2017;13:367–368.

with high-dose corticosteroids (1 mg/kg body weight [bw]/day of prednisone), to which he responded only partially. His response to the association of metronidazole (250 mg/8 h) and mycophenolate mofetil (1 g/12 h) was not satisfactory either, and he did not tolerate methotrexate. Given the high clinical activity and extension of the lesions, we decided to start treatment with intravenous belimumab (10 mg/kg bw each month), associated with hydroxychloroquine. The patient showed an evident satisfactory response after 1 month of treatment, with resolution of the skin lesions and alopecia, as well as clinical remission and normalization of the biological parameters. Four years after the start of this approach, he remains in remission.

Interstitial granulomatous dermatitis is an uncommon skin condition, that is occasionally associated with autoimmune diseases (rheumatoid arthritis, SLE, vasculitis, thyroiditis or diabetes), lymphoproliferative disorders and even certain drugs like anti-tumor necrosis factor agents.<sup>1,2</sup> The skin lesions usually develop in patients with SLE although, in some cases, they can also be the presenting sign of the disease.<sup>3</sup> Its treatment has not been well established. In the case of IGD associated with drugs, it seems to be necessary to discontinue the causative agent and assess introducing treatment with corticosteroids. In general lines, these are the primary therapeutic options for IGD. In cases of IGD associated with an autoimmune disease, it may be necessary to combine corticosteroids with the treatment of the underlying disease. For this, we utilize immunosuppressive drugs, like methotrexate, mycophenolate, hydroxychloroquine, dapsone and even metronidazole (the latter indicated in granulomatous diseases). Our patient did not tolerate methotrexate or respond to other treatments. With respect to biological therapy, there are reports of cases of IGD associated with arthritis in which there was a good cutaneous response to infliximab,<sup>4</sup> etanercept,<sup>5</sup> tocilizumab,<sup>6</sup> ustekinumab<sup>7</sup> and immunoglobulins,<sup>8</sup> treatments that were not indicated in our patient. Belimumab has been seen to be effective in individuals with SLE and with cutaneous and joint involvement that is refractory to standard immunosuppressive agents.<sup>9</sup> There is no evidence of its efficacy in IGD. It is a fully humanized monoclonal antibody against B lymphocyte stimulator (BlyS), the action of which focuses on the indirect depletion of B lymphocytes and plasma cells, thus reducing the production of antibodies. Given the elevated clinical and serum activity, considering the extension, severity and refractoriness of the skin lesions, we began treatment with belimumab, which achieved complete resolution of IGD. These results are surprising, considering that the mechanism of action of this drug does not appear to be related to the pathophysiology of the granulomatous lesion. The literature provides cases in which the development of IGD associated with autoimmune diseases was related to the presence of autoantibodies and immune complex deposition.<sup>10</sup> This suggests that the depletion of these elements would impede the perpetuation of the inflammatory cascade causing the granuloma.

In short, the development of IGD during the course of SLE is an uncommon cutaneous condition, with no established treatment, and it may be resistant to different therapeutic strategies. The case we report is the first in which belimumab was found to be effective in IGD associated with SLE.

## References

- Deng A, Harvey V, Sina B, Strobel D, Badros A, Junkins-Hopkins JM, et al. Interstitial granulomatous dermatitis associated with the use of tumor necrosis factor alpha inhibitors. *Arch Dermatol*. 2006;142:198–202.
- Guerin M, Haettich B, Bara C, Artru L, Prophette B, Céliérier P, et al. Lupus attributable to anti-TNF therapy and revealed by interstitial granulomatous dermatitis. *Rheumatol Int*. 2012;32:2937–40.

3. Jandali B, Uthman I, Abbas O. Interstitial granulomatous dermatitis associated with systemic lupus erythematosus: case report and review of the literature. *Lupus*. 2016;25:209–13.
4. Krauter A, Gambichler T, Altmeyer P. Infliximab therapy for interstitial granulomatous dermatitis. *J Eur Acad Dermatol Venereol*. 2007;21:251–2.
5. Ahmed ZS, Joad S, Singh M, Bandagi SS. Interstitial granulomatous dermatitis successfully treated with etanercept. *Am J Case Rep*. 2014;15:94–6.
6. Schanz S, Schmatzung M, Guenova E, Metzler G, Ulmar A, Kötter I, et al. Interstitial granulomatous dermatitis with arthritis responding to tocilizumab. *Arch Dermatol*. 2012;148:17–22150.
7. Leloup P, Aubert H, Causse S, LeGoff B, Barbarot S. Ustekinumab therapy for severe interstitial granulomatous dermatitis with arthritis. *JAMA Dermatol*. 2013;149:626–7.
8. Alghamdi R, Bejar C, Steff M, Deschamps L, Marinho E, Crickx B, et al. Intravenous immunoglobulins as a treatment of interstitial granulomatous dermatitis with arthritis. *Br J Dermatol*. 2012;167V:218–20.
9. Collins CE, Dall'Era M, Kan H, Macahilig C, Molta C, Koscielny V, et al. Response to belimumab among patients with systemic lupus erythematosus in clinical practice settings: 24-month results from the OBServe study in the USA. *Lupus Sci Med*. 2016;3:e000118.
10. Verneuil L, Domp Martin A, Comoz F, Pasquier CJ, Leroy D. Interstitial granulomatous dermatitis with cutaneous cords and arthritis: a disorder associated with autoantibodies. *J Am Acad Dermatol*. 2001;45:286–91.

Marta Arévalo,\* Mireia Moreno, Jordi Gratacós

*Servicio de Reumatología, Hospital Universitari Parc Taulí de Sabadell, Sabadell, Barcelona, Spain*

\* Corresponding author.

E-mail address: [marevalo@tauli.cat](mailto:marevalo@tauli.cat) (M. Arévalo).

2173-5743/

© 2016 Elsevier España, S.L.U. and Sociedad Española de Reumatología y Colegio Mexicano de Reumatología. All rights reserved.

### Safety of Joint Puncture in Patients Receiving Anticoagulant Therapy With Dabigatran<sup>☆</sup>



### Seguridad de la punción articular en pacientes en tratamiento anticoagulante con dabigatrán

To the Editor,

In a study that our research group published recently in this journal, we demonstrated the relative safety of intra-articular injection in patients anticoagulated with acenocoumarol.<sup>1</sup> These results agreed with those that had been previously reported for warfarin users.<sup>2,3</sup> In the last few years, other oral anticoagulants have been made available for the secondary prevention of stroke or primary prevention of thrombotic phenomena of any type in patients in whom the anticoagulation achieved with acenocoumarol was difficult to control.<sup>4</sup> After the experience in our registry of patients taking acenocoumarol, we reviewed our findings concerning complications following intra-articular injection of the knee and periarticular injection in shoulder in patients receiving dabigatran, a drug from a new generation of oral anticoagulants, with proven efficacy in the prevention of primary and secondary embolic events, which is especially indicated in patients in the geriatric population who have been diagnosed with atrial fibrillation.<sup>5</sup>

Between 2012 and 2016, patients in our center receiving dabigatran underwent 68 intra-articular injections in the knee and 49 periarticular injections in shoulder. The mean age of the patients at the time of the intervention was 71 years (standard deviation: 3) and the proportion of women was 47.8%. Dabigatran users were considered to be those being treated with the drug for at least 1 month. Of the 117 procedures, 78 (66.6%) were carried out by specialists in orthopedics, rheumatology or physical medicine and rehabilitation, and the rest by residents. Of the 68 intra-articular interventions performed in knees, 48 (70.5%) involved arthrocentesis of the synovial fluid as well as injection, whereas, in the remainder, the treatment consisted of the injection alone. In the 49 procedures involving the shoulder, fluid was collected from the bursa in 12 cases (24.4%) and the remainder of the procedures involved only the injection. Ultrasound guidance was utilized in 16 injections in the knee and 17 in the shoulder (23.5% and

34.6%, respectively). The follow-up of the course of the patients who underwent the interventions was done using the Horus<sup>®</sup> system, the follow-up chart of the rheumatological and musculoskeletal unit of the emergency department (RMSED) and/or the registry of visits to the emergency department of our hospital. Of all the patients who were treated with intra-articular injection of the knee, 11 (16.1%) consulted within the first 15 days in relation to the procedure they had undergone. Of these, 9 of them came because of the persistence of the major symptom or discomfort and 2 because of an increase in the pain. Both patients underwent ultrasound and 1 of them had a conservatively treated hemarthrosis. Of the 49 patients whose intervention involved the shoulder, 7 (14.2%) consulted during the first 15 days. The reason in every case was persistence of the symptom. None of the patients were hospitalized. None of the patients in whom ultrasound guidance had been employed consulted within the first 15 days. No patient consulted because of bleeding after the first 15 days. The performance of the treatment by a specialist or a resident did not significantly influence the results of the procedure; however, all of the ultrasound-guided procedures were carried out by a rheumatology specialist.

Judging by our latest results, intra-articular injection of the knee and periarticular injection of the shoulder in patients receiving anticoagulant therapy with dabigatran seems to be comparatively safe as compared to treatment with acenocoumarol. As is well known, the study of the synovial fluid is fundamental for making decisions in cases of acute monoarthritis, and delaying needle aspiration for any reason—such as a history of anticoagulation—contributes to an increase in the risk of irreversible or even fatal joint lesions when the suspected diagnosis is infectious arthritis.<sup>6,7</sup>

Our recent results, plus those previously obtained in patients taking acenocoumarol and others confirmed for warfarin, underline the fact that the condition of anticoagulation should not be an impediment or justification for delaying diagnostic or therapeutic intra-articular or periarticular injection.

### References

1. Guillen Astete C, Boteanu A, Medina Quiñones C, Garcia Montes N, Roldan Moll F, Carballo Carmano C, et al. Is it safe to perform joint infiltrations or aspirations in patients anticoagulated with acenocoumarol? *Reumatol Clin*. 2015;11:9–11.
2. Salvati G, Punzi L, Pianon M, Valvason C, Schiavon F, Noal N, et al. Frequency of the bleeding risk in patients receiving warfarin submitted to arthrocentesis of the knee. *Reumatismo*. 2003;55:159–63.

<sup>☆</sup> Please cite this article as: Guillén Astete CA, Terán Tinedo M, Quiñones Torres JR, Luque Alarcón M, Boteanu A. Seguridad de la punción articular en pacientes en tratamiento anticoagulante con dabigatrán. *Reumatol Clin*. 2017;13:368–369.