



Sociedad Española  
de Reumatología -  
Colegio Mexicano  
de Reumatología

# Reumatología Clínica

www.reumatologiaclinica.org



Images in Clinical Rheumatology

## Atypical Onset of Sciatica in a Patient With a *Filum Terminale* Hemangioblastoma<sup>☆</sup>



Ciatalgia de presentación atípica en paciente con hemangioblastoma de *filum terminale*

Tarek Carlos Salman-Monte,<sup>a,\*</sup> Francisco Castro-Dominguez,<sup>a</sup> Gloria Villalba,<sup>b</sup> Jaume Capellades,<sup>c</sup> Jordi Monfort<sup>a</sup>

<sup>a</sup> Servicio de Reumatología, Hospital del Mar, Parc de Salut Mar, IMIM, Barcelona, Spain

<sup>b</sup> Servicio de Neurocirugía, Hospital del Mar, Parc de Salut Mar, Barcelona, Spain

<sup>c</sup> Sección de Neurorradiología, Servicio de Radiología, Hospital del Mar, Parc de Salut Mar, Barcelona, Spain

### ARTICLE INFO

#### Article history:

Received 4 August 2016

Accepted 22 October 2016

Available online 22 September 2017

### Introduction

Hemangioblastomas are uncommon lesions that represent nearly 4% of the tumors of the spinal cord. Three fourths of them are sporadic, and the remainder are components of von Hippel Lindau (VHL) disease.<sup>1,2</sup> They are mostly found in the cerebellum, although they can develop in the brain stem or spinal cord; of the latter, they are only rarely located in the *filum terminale*.<sup>3</sup> The *filum terminale* is a delicate thread-like portion of fibrous tissue, a modification of the pia mater. It is about 20 cm long and originates at the vertex of the conus medullaris at the base of the coccyx, providing longitudinal support to the spinal cord.

### Case Report

We present the case of a woman who, at the time of the diagnosis, was 70 years of age and had a history of hemithyroidectomy for a thyroid nodule, as well as acromegaly due to a growth hormone and prolactin-producing pituitary adenoma. This lesion was removed using a transsphenoidal approach and her postoperative healing was satisfactory. She also had osteopenia and osteoarthritis of both knees, with total replacement of right knee.

She came to the rheumatology department for the first time after a history of several months of low back pain that was progressively more disabling, and was treated with radiation of

both lower limbs. Maneuvers to evaluate radicular pain were negative and there was no motor or sensory deficit; however, the patient experienced paresthesia.

The patient underwent magnetic resonance imaging (MRI) of the low back, which revealed an intradural space-occupying lesion in the conus medullaris. It was hypervascularized and receiving its supply of blood from a rosary-like vessel,<sup>4</sup> that extended from T10, occupying nearly the entire spinal canal to the level of L5. Spinal angiography confirmed the presence of a hypervascularized tumor irrigated by a medium-sized artery and a large, tortuous anterior spinal artery that was not amenable to embolization<sup>5,6</sup> (Figs. 1–3).

Given that the tumor could progress and result in subsequent clinical deterioration, we explained the therapeutic possibilities to the patient, and the decision was made to intervene surgically.<sup>7</sup>

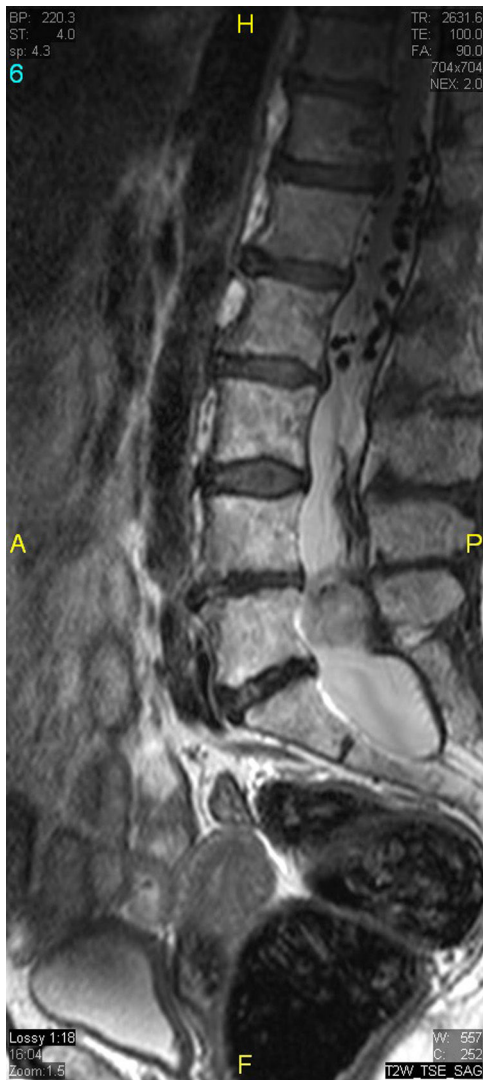
In the operating room, we observed a red mass totally adhered to the roots of the *filum terminale*. Clips were placed both on the artery and the vein. There was no marked modification in the size or the bleeding of the mass. Under intraoperative neurophysiological monitoring, the resection was highly complex because of the constant tendency of the mass to bleed<sup>8</sup> and its adherence to the nerve roots. We resected only 90% of the tumor because of the lability of the roots that were most closely in contact with the lesion. As a postoperative neurological sequela, the patient developed certain urinary incontinence, but the low back pain that radiated to her extremities had disappeared. Biopsy confirmed the diagnosis of hemangioblastoma; the study of the extension of the disease ruled out the existence of other hemangioblastomas.

The patient remained asymptomatic until the fourth year of follow-up, when she experienced a recurrence, with lumbosacral pain in her right leg, and lumbosacral MRI revealed tumor progression. Because of the neurological risk of further surgery, the

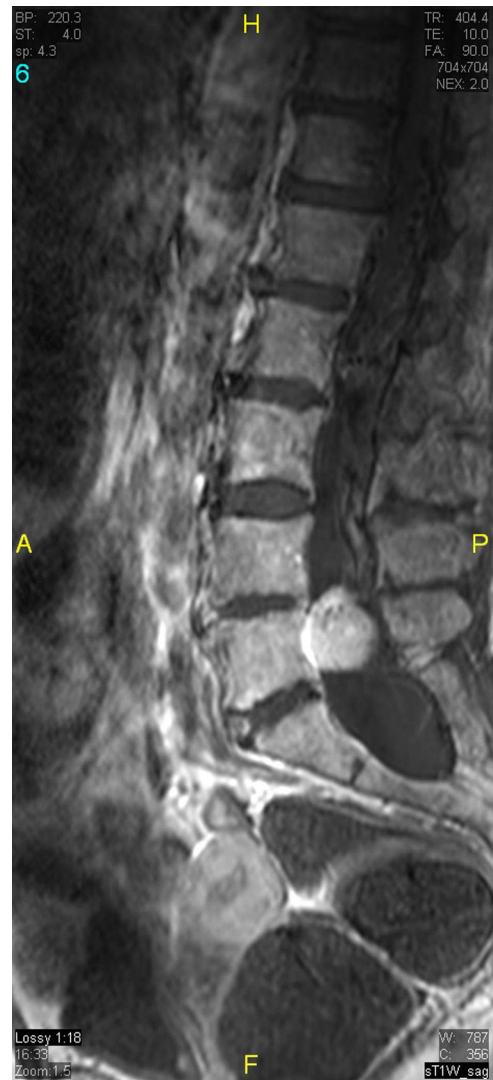<sup>☆</sup> Please cite this article as: Salman-Monte TC, Castro-Dominguez F, Villalba G, Capellades J, Monfort J. Ciatalgia de presentación atípica en paciente con hemangioblastoma de *filum terminale*. Reumatol Clin. 2018;14:115–118.

\* Corresponding author.

E-mail addresses: taret04@gmail.com, 98383@parcdesalutmar.cat (T.C. Salman-Monte).



**Fig. 1.** Sagittal T2-weighted turbo spin-echo image. Wide spinal canal with dilation of the dural sac termination that occupies the entire canal at the level of L5. Above that, note “flow voids” corresponding to dilated intradural vascular structures.



**Fig. 2.** Contrast-enhanced sagittal T1-weighted turbo spin-echo image. Intense enhancement of the intradural mass.

decision was made to embolize the lesion via right pedicle of L4, which resulted in its marked devascularization. After the procedure, the patient remained asymptomatic until the clinical signs reappeared 3 months later. Magnetic resonance imaging showed that the lesion continued to progress, and the decision was made to reoperate. This procedure achieved very limited resection due to adherence of the tumor and scar tissue to the L5 and S1 nerve roots, making it necessary to interrupt the intervention due to the risk of significant neurological sequelae.

After the failure of the surgical approach, it was decided to initiate focal radiotherapy<sup>9,10</sup> with 54 Gy over 27 sessions. The patient showed a good clinical response and there was a reduction in the size of the tumor.

To date, she continues to undergo clinical monitoring every 6 months and annual radiological evaluation, and is asymptomatic and the lesion has not grown (Figs. 4 and 5).

## Discussion

Hemangioblastomas are slow-growing tumors. Sporadic lesions are usually solitary and are often in regions associated with greater neurological compromise; they typically affect young men

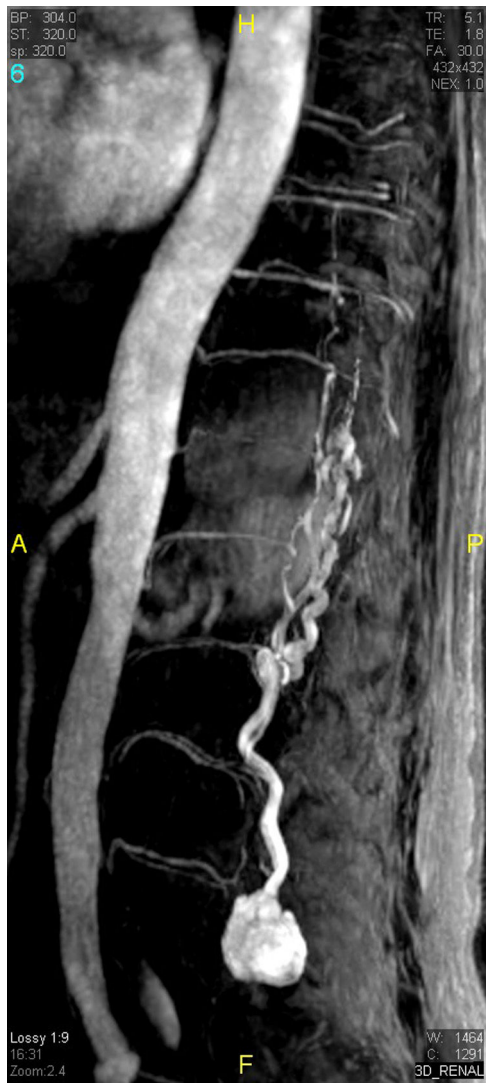(40 years) and are rare both in older persons and in children. In individuals with VHL disease, the usual age at the time of diagnosis is approximately 29 years.

The clinical manifestations are those derived from the location of the space-occupying lesion. The treatment of these patients should be chosen with this in mind due to the potential sequelae that can result from a surgical intervention at the site of the tumor; surgery should be an option reserved for those individuals who are symptomatic.

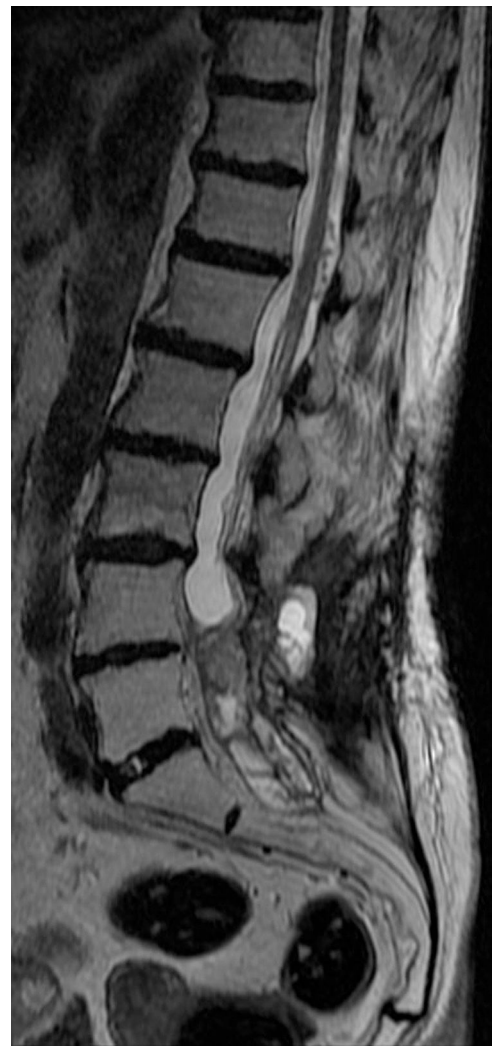Although it is true that the lesions can often be completely removed, it must be taken into account that the recurrence rate ranges between 16% and 30% and that of operative mortality from 8% to 15%, whereas the 5-year survival is 90%.

In this case, the sequelae of urinary incontinence had been discussed and was acceptable to the patient, who had scaled the entire analgesic ladder in the unsuccessful attempt to treat her severe low back pain.

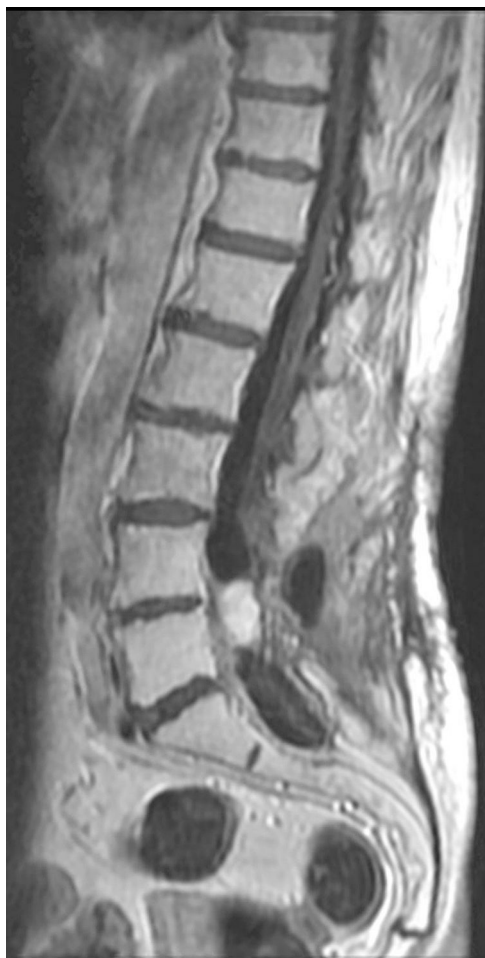Both surgical management and that based on radiation have a role, and must be selected in accordance with the characteristics of the lesion and the patient, although there are no randomized clinical trials that compare or determine the time demanded by the different therapeutic actions. There is increasing evidence that supports the role of stereotaxic surgery and radiotherapy in selected



**Fig. 3.** Contrast-enhanced magnetic resonance angiographic image. Sagittal plane with maximum intensity projection reconstruction. The image shows the mass, as well as the dilated vascular structures. Because of the static nature of the examination, the view does not show the origin of the blood supply.



**Fig. 4.** Sagittal T2-weighted turbo spin-echo magnetic resonance image. Reduction of the intradural mass and absence of the dilated vascular structures.



**Fig. 5.** Contrast-enhanced sagittal T1-weighted turbo spin-echo image. Reduction of the intradural mass and absence of the dilated vascular structures.

patients with multiple tumors and those of difficult surgical access and in postoperative recurrence.

#### Ethical Disclosures

**Protection of human and animal subjects.** The authors declare that no experiments were performed on humans or animals for this study.

**Confidentiality of data.** The authors declare that they have followed the protocols of their work center on the publication of patient data.

**Right to privacy and informed consent.** The authors declare that no patient data appear in this article.

#### Conflicts of Interest

The authors declare they have no conflicts of interest.

#### References

1. Neumann HP, Eggert HR, Weigel K, Friedburg H, Wiestler OD, Schollmeyer P. Hemangioblastomas of the central nervous system. A 10-year study with special reference to von Hippel-Lindau syndrome. *J Neurosurg.* 1989;70:24–30.
2. Conway JE, Chou D, Clatterbuck RE, Brem H, Long DM, Rigamonti D. Hemangioblastomas of the central nervous system in von Hippel-Lindau syndrome and sporadic disease. *Neurosurgery.* 2001;48:55–62.
3. Aldape KD, Plate KH, Vortmeyer AO, Zagzag D, Neumann HPH. Haemangioblastoma. In: Louis DN, Ohgaki H, Wiestler OD, Cavenee WK, editors. *WHO classification of tumours of the central nervous system.* Lyon: IARC; 2007. p. 184–6.
4. Capellades J, Rovira A, Alvarez Sabin J. Hemangioblastoma medular: diagnóstico por resonancia magnética. *Rev Neurol.* 1995;23:1320–9.
5. Chu BC, Terae S, Hida K, Furukawa M, Abe S, Miyasaka K. MR findings in spinal hemangioblastoma: correlation with symptoms and with angiographic and surgical findings. *Am J Neuroradiol.* 2001;22:206–17.
6. Eskridge JM, McAuliffe W, Harris B, Kim DK, Scott J, Winn HR. Preoperative endovascular embolization of craniospinal hemangioblastoma. *Am J Neuroradiol.* 1996;17:525–31.
7. Roonprapunt C, Silvera VM, Setton A, Freed D, Epstein FJ, Jallo GI. Surgical management of isolated hemangioblastomas of the spinal cord. *Neurosurgery.* 2001;49:321–7.
8. Yu JS, Short MP, Schumacher J, Chapman PH, Harsh GR 4th. Intramedullary hemorrhage in spinal cord hemangioblastoma. Report of two cases. *J Neurosurg.* 1994;81:937–40.
9. Helle TL, Conley FK, Britt RH. Effect of radiation therapy on hemangioblastomas: a case report and review of the literature. *Neurosurgery.* 1980;6:82–6.
10. Koh ES, Nichol A, Millar BA, Ménard C, Pond G, Laperriere NJ. Role of fractionated external beam radiotherapy in hemangioblastoma of the central nervous system. *Int J Radiat Oncol Biol Phys.* 2007;69:1521–6.