

Anahy M. Brandy-García,^{a,*} Iván Cabezas-Rodríguez,^a
Daniel Caravia-Durán,^b Luis Caminal-Montero^b

^a Servicio de Reumatología, Hospital Universitario Central de Asturias, Oviedo, Asturias, Spain

^b Unidad de Enfermedades Autoinmunes Sistémicas, Unidad de Gestión Clínica de Medicina Interna, Hospital Universitario Central de Asturias, Oviedo, Asturias, Spain

* Corresponding author.

E-mail address: anahymbg@gmail.com (A.M. Brandy-García).

2173-5743/

© 2017 Elsevier España, S.L.U. and Sociedad Española de Reumatología y Colegio Mexicano de Reumatología. All rights reserved.

Sarcoidosis-lymphoma Syndrome[☆]



Síndrome sarcoidosis-linfoma

To the Editor,

We found it very interesting to read the report on “Sarcoidosis-lymphoma Syndrome”, by Brandy-García et al., recently published in *Reumatología Clínica*,¹ in which the authors review the history of the first description and subsequent communications in Spain, and contribute to our knowledge of this condition. In their study, they point out the difficulty in distinguishing between the two diseases in the differential diagnosis, and particularly establish the complexity of the diagnosis of neurosarcoidosis, given the lack of specificity of the imaging studies, as well as the difficulty in accomplishing a pathological study.

The authors were able to summarize and analyze the most important and controversial aspects that the physicians responsible for these patients need to confront day after day; however, although we share their conclusions, we believe that some consideration should be given to the diagnostic tests. We wish to point out that when they mention normal lumbar puncture and cytometry in which a T lymphoid population was recognized, it is not clear which sample corresponded to the cytometric study.

Especially, in this case, it must be acknowledged that, given the absence of a histological study, it is evidently difficult to identify the definitive diagnosis on the basis only of the clinical signs and the imaging studies. However, the unavailability of a histological

diagnosis should not be a barrier that delays the diagnosis and treatment in these cases.

For this reason, we consider it relevant to point out the need for flow cytometry of the cerebrospinal fluid,^{2,3} whenever it is not contraindicated, in patients with a history of sarcoidosis and in whom the involvement of the central nervous system is suspected, to obtain confirmatory and more accurate data on the correct diagnosis.

We agree with the authors that there is a lack of scientific evidence on this subject. Therefore, we would like to thank them for publishing their notable contribution to help us to make progress in the diagnosis of this disorder.

References

1. Brandy-García AM, Caminal-Montero L, Fernández-García MS, Saiz Ayala A, Cabezas-Rodríguez I, Morante-Bolado I. Síndrome sarcoidosis-linfoma. *Reumatol Clin.* 2016;12:339–41.
2. Craig FE, Foon KA. Flow cytometric immunophenotyping for hematologic neoplasms. *Blood.* 2008;111:3941–67.
3. Pillai V, Dorfman DM. Flow cytometry of nonhematopoietic neoplasms. *Acta Cytol.* 2016;60:336–43.

María Mar Herráez-Albendea,^{a,*} María Castillo Jarilla-Fernández^b

^a Servicio de Hematología, Hospital de Santa Bárbara, Puertollano, Ciudad Real, Spain

^b Servicio de Hematología, Hospital General de Ciudad Real, Ciudad Real, Spain

* Corresponding author.

E-mail address: marherraez@gmail.com (M.M. Herráez-Albendea).

2173-5743/

© 2016 Elsevier España, S.L.U. and Sociedad Española de Reumatología y Colegio Mexicano de Reumatología. All rights reserved.

[☆] Please cite this article as: Herráez-Albendea MM, Jarilla-Fernández MC. Síndrome sarcoidosis-linfoma. *Reumatol Clin.* 2017;13:365.

Rhupus and Autoimmune Hepatitis: A Rare Association[☆]



Rupus y hepatitis autoinmune: una asociación infrecuente

To the Editor,

Overlap syndromes are uncommon conditions in which the diagnostic criteria of more than one systemic autoimmune disease are met in a single patient.¹ In contrast to mixed connective tissue diseases (MCTD), in which certain clinical or serological

characteristics are identified, they do not fulfill the diagnostic criteria in order to be categorized as a defined disease.^{1,2}

“Rhupus” is an entity in which there is an overlap of systemic lupus erythematosus (SLE) and rheumatoid arthritis (RA), and the incidence involves less than 1% of the SLE population.^{1,2} Autoimmune hepatitis (AIH) is a chronic progressive liver disease. Its prevalence is relatively low, as it affects around 16.9 individuals in population of 100,000.³

We report the case of a 30-year-old woman, with a history of RA, who came to the hospital with acute pyelonephritis. Therapy was begun with antibiotics and symptomatic treatment, and the patient responded favorably. Four days later, she presented with pain in hypogastrium and right hypochondriac region, nausea, vomiting, paleness, pain and stiffness in the metacarpophalangeal joint (with synovitis) and bilateral coxofemoral joint, red eye syndrome, malar erythema and photosensitivity.

[☆] Please cite this article as: Zavala-Flores E, Loja-Oropeza D. Rhupus y hepatitis autoinmune: una asociación infrecuente. *Reumatol Clin.* 2017;13:365–366.

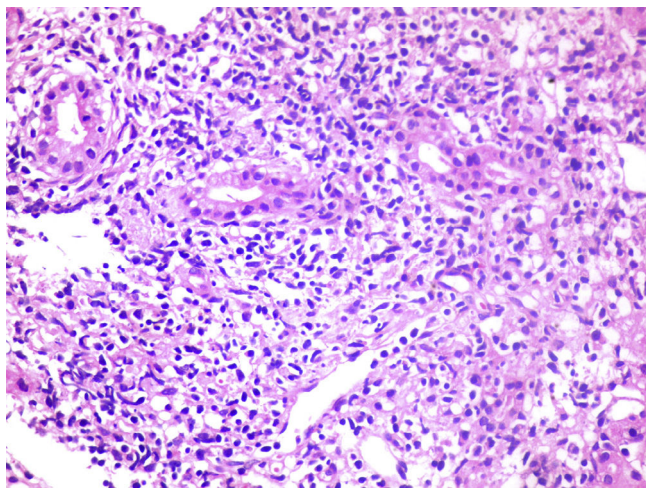


Fig. 1. Piecemeal necrosis with damage to the hepatocytes. Necroinflammatory lesion.

Ancillary tests: albumin: 4 g/dL; globulin: 4 g/dL; immunoglobulin (Ig) G: 1669.4 mg/dL; IgM: 473.0 mg/dL; antinuclear antibodies positive: 1/400, homogeneous pattern; native SS-A⁺⁺⁺; single-stranded DNA⁺⁺; RNP: positive; RNP A: negative; RNP C: negative; Scl 70: negative; PM-Scl: negative; Jo-1: negative; centromere protein B: negative; serum complement C3-C4 level: low; lupus anticoagulant (kaolin): 0.83 (–); IgG anticardiolipin: 12 (+); IgM anticardiolipin: 19 (+); and beta 2 glycoprotein I: not determined.

Total bilirubin: 1.5 mg/dL (0.4–1.2 mg/dL); direct bilirubin: 1 mg/dL (0–0.3 mg/dL); aspartate aminotransferase: 31 IU/L; alanine aminotransferase: 25 IU/L; gamma-glutamyltransferase: 61 IU/L; prothrombin time: 13.9 s; international normalized ratio (INR): 1.22; Australian antigen (HBsAg): negative; anti-hepatitis C virus: negative; anti-hepatitis A virus (HAV) IgM: negative; rheumatoid factor: 21 IU/mL; erythrocyte sedimentation rate: 66 mm/h; anti-smooth muscle antibodies (+); and anti-liver-kidney microsomal (LKM) antibody: negative.

Abdominal ultrasound: chronic diffuse liver disease and hepatomegaly, right diffuse renal disease and nephromegaly.

Soft tissue ultrasound: capsular distension with effusion, synovitis in proximal metacarpophalangeal joints compatible with RA.

Liver biopsy: changes in liver architecture, with portal spaces widened by the chronic mononuclear lymphocytic inflammatory process that damaged the limiting plate. Presence of piecemeal necrosis, or interface hepatitis, necroinflammatory foci, mild plasmacytosis, binucleated reactive hepatocytes, disarranged trabeculae (Fig. 1). The findings were consistent with chronic active liver disease.

Symptoms suggestive of SLE were manifest. Thus, we requested an immunological profile that subsequently would corroborate the diagnosis, together with the history of RA and evidence from the soft tissue ultrasound, pointed to the diagnosis of *rhupus*. Patients with *rhupus* often present with a diagnosis of RA and, later, develop secondary signs of SLE.⁴ The clinical symptoms and signs associated with SLE in *rhupus* are cutaneous photosensitivity,

malar rash, alopecia, and hematologic changes such as leukopenia and thrombocytopenia. Renal and neurological involvement are uncommon.^{5,6}

Diffuse liver disease, hypergammaglobulinemia and the presence of anti-smooth muscle antibodies were noteworthy and, given the suspicion of AIH, we requested a liver biopsy. The findings were consistent with interface hepatitis with mononuclear infiltrate, and the simplified criteria for AIH were evaluated⁷ and the result was positive, with a score of 7.

The presence of antiphospholipid (aPL) antibodies pointed to the suspicion of aPL syndrome. However, the absence of clinical manifestations or obstetric history ruled it out. Another study found that up to 3% of the patients with autoimmune liver disease had aPL, although this result was not significant.⁸

In conclusion, the overlap of *rhupus* and autoimmune hepatitis is an uncommon condition that requires suspicion on the part of the clinician and multidisciplinary management for appropriate treatment.

Authorship

EZF and DLO participated in the conception of the article, in its writing and in the critical review of the text. All of the authors approved the article for publication.

References

1. Amezcua-Gerra LM. Overlap between systemic lupus erythematosus and rheumatoid arthritis: is it real or just an illusion? *J Rheumatol*. 2009;36:4–6.
2. Carrillo-Náñez L, Huaranga-Marcelo J, Carrillo-García. *Rhupus en un paciente varón*. *Rev Soc Peru Med Int*. 2012;25:131.
3. Zubieta-Rodríguez R, Gómez-Correa J, Rodríguez-Amaya R. Cirrosis hepática por hepatitis autoinmune: serie de casos y revisión de la literatura. *Med Uis*. 2016;29:175–82.
4. Simon JA, Seeded J, Cabiedes J, Ruiz Morales J, Alcocer J. Clinical and immunogenetic characterization of Mexican patients with 'rhupus'. *Lupus*. 2002;11:287–92.
5. Suárez Pichilingue G, Gutierrez Campos J, Cieza Zevallos J. Características clínicas y hallazgos histopatológicos de glomerulonefritis lúpica en pacientes con *Rhupus* en el Hospital Nacional Arzobispo Loayza en los años 2003 al 2009. *Acta Med Per*. 2011;28:79–81.
6. García-Torres ML, Primo J, Ortuño JA, Martínez M, Antón MD, Zaragoza A, et al. Estudio clínico de la hepatitis autoinmune en el adulto en Valencia. *Rev Esp Enferm Dig*. 2008;100:400–4.
7. Hennes EM, Zeniya M, Czaja AJ, Pares A, Dalekos GN, Krawitt EL, et al. Simplified diagnostic criteria for autoimmune hepatitis. *Hepatology*. 2008;48:169–76.
8. de Larrañaga GF, Harris N, Pierangeli SS, Alonso BS, Schroder T, Fainboim H. Low prevalence of autoimmune antiphospholipid antibodies in hepatic diseases. *Medicina (B Aires)*. 2000;60:919–22.

Ernesto Zavala-Flores,^{a,*} David Loja-Oropeza^b

^a Universidad San Martín de Porres, Lima, Peru

^b Hospital Nacional Arzobispo Loayza, Lima, Peru

* Corresponding author.

E-mail address: ernestozav123@gmail.com (E. Zavala-Flores).

2173-5743/

© 2017 Elsevier España, S.L.U. and Sociedad Española de Reumatología y Colegio Mexicano de Reumatología. All rights reserved.