

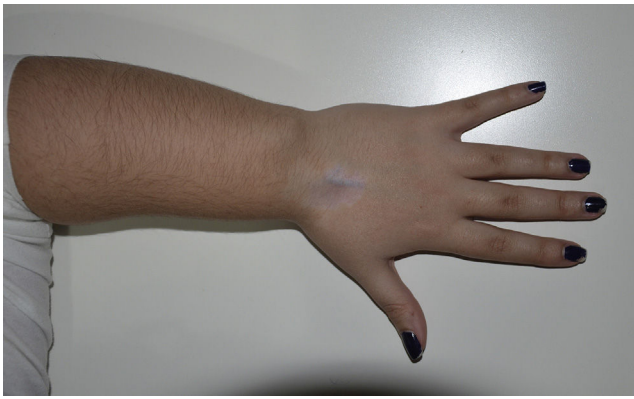

Fig. 3.

limitation (Figs. 1–3). There was no evidence of paresthesias or other neurological symptoms. Under sedation, the patient received the injection of 20 mg of triamcinolone in each carpi. In a check-up 1 month later, she reported a clear improvement, mentioning the nearly complete disappearance of the pain within 24–48 h after the injection, and an improvement in mobility.

We consider that, like the authors of the letter we comment here, local corticosteroid injection is a valid option in cases of carpal

pain secondary to Madelung's deformity during the pediatric age, even in the absence of symptoms of carpal tunnel syndrome. Moreover, as the skeleton of the child is still growing, it is necessary to postpone surgical treatment. Thus, in our opinion, local injection is an interesting conservative option given the potential relief of the symptoms, with a low probability of complications. Nevertheless, we have not found publications dealing with this therapeutic approach, nor of its medium- and long-term efficacy.

Reference

1. Ly-Pen D, Andreu JL. Madelung's deformity. *Reumatol Clin.* 2014;10:125–6.

Maria Amelia Muñoz Calonge,^{a,*} Sara M. Murias Loza,^a Nerea Itza^b

^a *Reumatología Pediátrica, Hospital La Paz, Madrid, Spain*

^b *Endocrinología Pediátrica, Hospital La Paz, Madrid, Spain*

* Corresponding author.

E-mail address: amemc88@gmail.com (M.A. Muñoz Calonge).

2173-5743/

© 2016 Elsevier España, S.L.U. and Sociedad Española de Reumatología y Colegio Mexicano de Reumatología. All rights reserved.

Diaphragmatic Paralysis in Eosinophilic Granulomatosis With Polyangiitis[☆]



Parálisis diafragmática en granulomatosis eosinofílica con poliangiitis

To the Editor,

Eosinophilic granulomatosis with polyangiitis is an autoimmune disease that affects the small vessels. Its cause is unknown and a delay in the diagnosis is associated with a worse prognosis. Patients can be present with some degree of respiratory insufficiency due to asthma, pneumonia, alveolar hemorrhage and thromboembolism, as well as cardiovascular or neuromuscular problems.¹ There have been occasional reports of cases of unilateral diaphragmatic paralysis, with a variable impact on respiratory function.^{2,3} We present the case of a woman with eosinophilic granulomatosis with polyangiitis who also had hypercapnic respiratory failure associated with a polyneuropathy manifested by diaphragmatic paralysis and brachial plexopathy.

The patient was a woman who gave her age as 49 years old. She had been diagnosed as having asthma 4 years earlier, and had been admitted to the hospital several times with severe exacerbations, despite high doses of inhaled glucocorticoids. The last time she had been admitted she had required mechanical ventilation to resolve her asthma episode. Supplemental oxygen was delivered by facemask. Arterial blood gas analysis recorded a pH of 7.31, arterial carbon dioxide partial pressure (PaCO₂) of 62 mmHg, arterial oxygen partial pressure (PaO₂) of 79 mmHg, bicarbonate (HCO₃⁻) of 21.1 mEq/L and oxygen (O₂) saturation of 88%. Physical exploration disclosed an urticaria-like rash on her extremities and, particularly,

her left hand showed the sign of the “preacher's hand” (Fig. 1A). Complete blood count revealed severe eosinophilia with a level of 6000 cells/μL. Treatment included high doses of systemic glucocorticoids, aminophylline and nebulizers. Fortunately, the mechanical ventilator was withdrawn a few days later and she was finally extubated. However, radiological monitoring showed elevation of her left diaphragm. A fluoroscopic-guided study confirmed paralysis of that portion of the diaphragm (Fig. 1B and C). Computed tomography of the cervical spine and thorax ruled out myelopathy and nerve root compression. Electromyography of the left arm was consistent with brachial plexopathy and severe axonal injury of the proximal and distal ulnar nerve. A specimen obtained in a skin biopsy of the erythematous lesions revealed the presence of extravascular eosinophils. Nevertheless, perinuclear and cytoplasmic antineutrophil cytoplasmic antibodies (ANCA) were negative. A few weeks after hospital discharge, she recovered diaphragmatic mobility. However, there was no improvement in the ulnar neuropathy, but there was a notable decrease in the recurrence of exacerbations of the asthma.

Whereas the possible mechanisms that can produce respiratory insufficiency in a patient with eosinophilic granulomatosis with polyangiitis are well known, diaphragmatic paralysis has not been considered among them, even as a contributing factor. In the literature, we found a total of 5 cases of unilateral diaphragmatic paralysis in patients with this vasculitis. The mechanism underlying its production is similar to that described for other neuropathies secondary to autoimmune inflammation that involves the *vasa nervorum* resulting in axonal ischemia in the phrenic nerve.^{2,3} Moreover, involvement of the phrenic nerve has also been reported in other vasculitides.^{4,5} Idiopathic brachial plexopathy or Parsonage–Turner syndrome is a rare condition described in certain clinical situations, including giant cell arteritis and polyarteritis nodosa, in which the phrenic nerve can also be affected.⁶ Nevertheless, it is a painful syndrome that can be accompanied by important sensory abnormalities, a complication that was not observed in our patient.

[☆] Please cite this article as: Flores-Franco RA, Castillo-Soltero J, Pacheco-Tena CF. Parálisis diafragmática en granulomatosis eosinofílica con poliangiitis. *Reumatol Clin.* 2018;14:61–62.

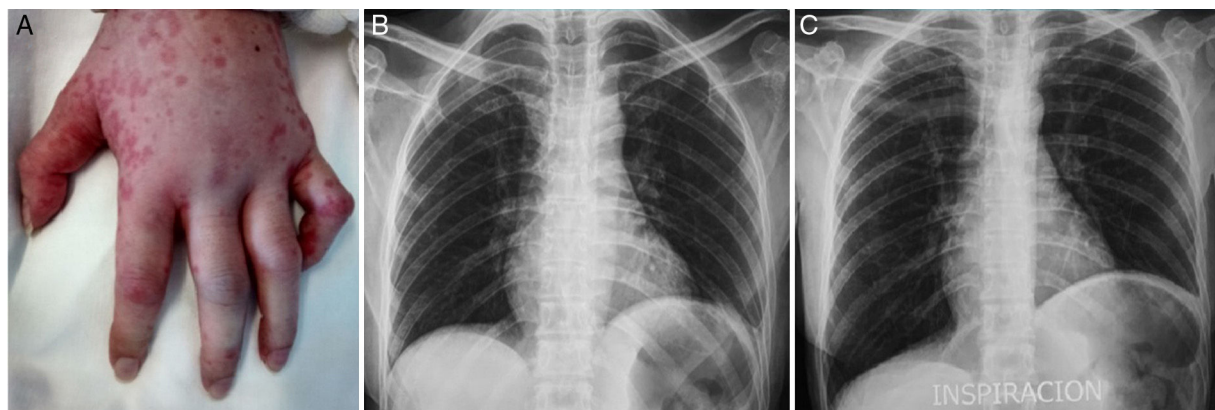


Fig. 1. (A) Edema and urticaria in the patient's left hand and flexion of the fifth finger produced by involvement of the ulnar nerve. (B) Chest radiograph during exhalation. (C) Chest radiograph during inhalation showing hemiplegia affecting left hemidiaphragm.

Although unilateral diaphragmatic paralysis is not intrinsically lethal, it decreases breathing capacity by more than a third.⁷ In our patient, the resulting reduction in lung distensibility, as well as the increase in the dead space observed in the obstruction of the airways associated with asthma, led to a decrease in alveolar ventilation and, as a consequence, a rise in the carbon dioxide in arterial circulation and the subsequent development of hypercapnic respiratory failure. On the basis of the latter, in the management of hypercapnic respiratory failure in a patient with this disease, we consider it important to take into account not only the obstruction of the airway as a causal mechanism, but also the possible role of neuromuscular participation in aggravating the situation.

Reference

- Martín N, Ríos J. Afectación pulmonar de las vasculitis. *Arch Bronconeumol*. 2012;48:410–8.
- Gandino I, Muñoz S, Poblete G, Carrillo J. Parálisis diafragmática y de cuerda vocal en un paciente con síndrome de Churg-Strauss: reporte de un caso. *Rev Chil Reumatol*. 2012;38:95–8.
- Sharma A, Bamberg P, Shamanna SB, Wanchu A, Singh S. Phrenic nerve palsy in a patient of Churg Strauss syndrome and mononeuritis multiple. *Clin Rheumatol*. 2008;27:137–9.
- Feiz H, Oberstein E, Lyubynska N, Kulkarni S, Ban F. Phrenic nerve paralysis as the initial presentation of granulomatosis with polyangiitis. *Autoimmune Dis Ther Approach*. 2015;2:112.
- Colaci M, Cassone G, Manfredi A, Sebastiani M, Giuggioli D, Ferri C. Neurologic complications associated with Sjögren's disease: case reports and modern pathogenic dilemma. *Case Rep Neurol Med*. 2014;2014:590292.
- Feinberg JH, Radecki J. Parsonage–Turner syndrome. *HSS J*. 2010;6:199–205.
- Eleftheriades J, Singh M, Tang P, Siegel MD, Kenney B, Pandey A, et al. Unilateral diaphragm paralysis: etiology, impact, and natural history. *J Cardiovasc Surg*. 2008;49:289–95.

René Agustín Flores-Franco,^{a,*} Jesús Castillo-Soltero,^a
Cesar Francisco Pacheco-Tena^b

^a *Departamento de Medicina Interna, Hospital General Regional «Dr. Salvador Zubirán Anchondo», Chihuahua, Mexico*

^b *Facultad de Medicina, Universidad Autónoma de Chihuahua, Circuito Universitario Campus II, Chihuahua, Mexico*

* Corresponding author.

E-mail address: rflores99@prontomail.com (R.A. Flores-Franco).

2173-5743/

© 2017 Elsevier España, S.L.U. and Sociedad Española de Reumatología y Colegio Mexicano de Reumatología. All rights reserved.