



Sociedad Española
de Reumatología -
Colegio Mexicano
de Reumatología

Reumatología Clínica

www.reumatologiaclinica.org



Original Article

The Value of Power Doppler Ultrasound in Patients With Rheumatoid Arthritis in Clinical Remission: Reclassifying Disease Activity?☆



Facundo Vergara, Santiago Ruta, Javier Rosa,* Josefina Marín, Ricardo García-Mónaco, Enrique R. Soriano

Sección de Reumatología, Servicio de Clínica Médica, Hospital Italiano de Buenos Aires, Buenos Aires, Argentina

ARTICLE INFO

Article history:

Received 24 September 2016

Accepted 18 January 2017

Available online 14 June 2018

Keywords:

Rheumatoid arthritis

Clinical remission

Ultrasound

Doppler

ABSTRACT

Objectives: The aim of the present study was to describe the ultrasound (US) findings in patients with rheumatoid arthritis (RA) in clinical remission, and to evaluate the ability of power Doppler (PD) US to reclassify disease activity in these patients.

Material and methods: We included consecutive patients with RA according to 2010 American College of Rheumatology/European League Against Rheumatism criteria, who were in clinical remission by the Disease Activity Score (DAS28 < 2.6). Twenty joints of both hands were assessed by US. PD signal was evaluated on a semi-quantitative scale from 0 to 3. Three different US-modified DAS28 (US-DAS28) were constructed, replacing the clinical swollen joint count by the PD US joint count using PD score ≥ 1 , ≥ 2 or ≥ 3 , respectively.

Results: Eighty-six patients were included. Twenty-three (26.7%) patients had at least one joint with abnormal US-positive PD signal. Thirteen percent of patients were reclassified to low disease activity by applying the US-DAS28 when joints were considered active with a PD signal ≥ 1 ; 12%, when a PD signal ≥ 2 was considered, and 2% of the patients were reclassified when a PD score of 3 was considered. No patients were reclassified to a level of moderate or high activity applying US-DAS28.

Conclusions: Although around a quarter of patients with RA in clinical remission showed PD US features indicating residual activity, only a small percentage were reclassified to a state of low activity and none to a level of moderate or high activity, applying the proposed US-DAS28.

© 2017 Elsevier España, S.L.U. and Sociedad Española de Reumatología y Colegio Mexicano de Reumatología. All rights reserved.

Valor de la ecografía con Doppler de poder en pacientes con artritis reumatoide en remisión clínica: ¿reclasificación de la actividad de la enfermedad?

RESUMEN

Objetivos: Describir los hallazgos ecográficos en pacientes con artritis reumatoide (AR) en remisión clínica y evaluar la capacidad de la ecografía con Doppler de poder (DP) para reclasificar la actividad de la enfermedad en este grupo de pacientes.

Material y métodos: Se incluyeron pacientes consecutivos con diagnóstico de AR (criterios ACR/EULAR 2010) en remisión clínica por DAS28 (< 2,6). Se evaluaron mediante ecografía 20 articulaciones de ambas manos. La señal DP fue evaluada mediante una escala semicuantitativa de 0 a 3. Se construyeron 3 índices clínico-ecográficos que denominamos ECO-DAS28 1, 2 y 3, donde el recuento de articulaciones tumefactas evaluadas clínicamente fue reemplazado por el recuento de articulaciones con señal DP positiva grado ≥ 1 , ≥ 2 o 3, respectivamente.

Palabras clave:

Artritis reumatoide

Remisión clínica

Ecografía

Doppler

☆ Please cite this article as: Vergara F, Ruta S, Rosa J, Marín J, García-Mónaco R, Soriano ER. Valor de la ecografía con Doppler de poder en pacientes con artritis reumatoide en remisión clínica: ¿reclasificación de la actividad de la enfermedad? Reumatol Clin. 2018;14:202–206.

* Corresponding author.

E-mail address: javier.rosa@hospitalitaliano.org.ar (J. Rosa).

Resultados: Se incluyeron 86 pacientes, de los cuales 23 (26,7%) tuvieron al menos una articulación con señal DP positiva. Un 13% de los pacientes fueron reclasificados hacia baja actividad de la enfermedad aplicando el ECO-DAS28 cuando se consideraron activas las articulaciones con señal DP grado ≥ 1 , el 12% cuando se consideró actividad una señal DP ≥ 2 y el 2% de los pacientes cuando se consideró la señal DP igual a 3. Ningún paciente se reclasificó a un nivel de moderada o alta actividad.

Conclusiones: A pesar de encontrar actividad inflamatoria residual por ecografía en aproximadamente un cuarto de los pacientes con AR en remisión clínica, solo un bajo porcentaje fue reclasificado a un estado de baja actividad de la enfermedad y ninguno a un nivel de moderada o alta, aplicando los ECO-DAS28 propuestos.

© 2017 Elsevier España, S.L.U.

y Sociedad Española de Reumatología y Colegio Mexicano de Reumatología. Todos los derechos reservados.

Introduction

In recent decades, musculoskeletal ultrasound has become a highly useful tool in the evaluation and management of patients with distinct rheumatic diseases, especially those with a diagnosis of rheumatoid arthritis (RA).^{1,2}

Ultrasound constitutes an ancillary tool in physical examination and, as this method is highly sensitive in the detection of inflammatory processes, it provides greater information on the degree of joint involvement,^{3–5} even in patients in clinical remission. Synovitis detected by ultrasound, rather than by a clinical test or in asymptomatic patients with a diagnosis of RA, regardless of the disease activity score, is referred to as “subclinical synovitis”. Ultrasound has been shown to be useful in the detection of subclinical inflammatory changes in the joints.^{3,6–9} However, it is not yet clear whether these findings should lead to a modification of the therapeutic management.^{10–12}

A number of studies have demonstrated the importance of ultrasound as an independent predictor of radiographic progression and the development of bone erosions affecting joints.^{7,9,13–15} The presence of the power Doppler (PD) signal would always have a role in the prediction of relapse in RA patients who are in clinical remission.^{14,16–18}

In the near future, the “treat-to-target” strategy guided by ultrasound could be a valid alternative for improving the treatment and prognosis of patients with RA.^{19–22}

The purpose of the present study was to describe the ultrasound findings in RA patients in clinical remission and evaluate the capability of PD ultrasound for reclassifying the level of the activity of RA measured by the Disease Activity Score in 28 joints (DAS28) in this group of patients.

Material and Methods

Patients

We included 86 consecutive patients from the outpatient clinical practice of the rheumatology department of Hospital Italiano de Buenos Aires, Argentina, who met the 2010 American College of Rheumatology/European League Against Rheumatism (ACR/EULAR) criteria²³ for the diagnosis of RA and who were in clinical remission in accordance with the criteria of their treating physicians and had a DAS28 < 2.6.²⁴

During the first visit to the rheumatology department, the clinical and demographic data of the patients were recorded, after which they underwent an ultrasound evaluation of both hands.

Clinical Examination

This was carried out in every case by experienced rheumatologists. The tender and swollen joint counts were determined,²⁸ and the visual analog scale (VAS) was employed to establish

the disease activity as assessed by the patient. The DAS28 was calculated utilizing the erythrocyte sedimentation rate.²⁴

Ultrasound Evaluation

This was performed in every case by the same rheumatologist, who had extensive experience in the technique—and who was blinded to the clinical data of the patient—on the same day as the clinical evaluation. This was carried out with a MyLab[®] 70 ultrasound system (Esaote) equipped with a 6–18 MHz multifrequency linear transducer. The ultrasound technique was done in accordance with the EULAR recommendations.²⁵ Bilateral evaluation was performed in the following joints of the hands and carpi (a total of 20): carpus, first to fifth metacarpophalangeal joints and second to fifth proximal interphalangeal joints. The carpus and metacarpophalangeal joints were evaluated using a dorsal approach and the proximal interphalangeal joints employing a palmar approach. The carpus was considered to be a single unit, which could affect the radiocarpal and/or intercarpal recess. We evaluated the presence of joint capsular distension (JCD) on gray-scale images, either due to the presence of fluid and/or synovial hypertrophy, in accordance with the definitions of the OMERACT group.²⁶

The degree of abnormal intra-articular vascularization was determined by means of the PD technique, utilizing a semiquantitative scale from 0 to 3 (score of 0: absence of PD signal; score of 1: presence of a single signal; score of 2: presence of 1 or more confluent signals that occupy less than 50% of the intra-articular area; score of 3: signal occupying more than 50% of the intra-articular area). The configuration of PD parameters agreed with the recommendation of experts.^{4,27}

We constructed 3 indices of clinical-ultrasonographic activity that we refer to as ECO-DAS28 (DAS28 modified by ultrasound: ECO-DAS28₁, ECO-DAS28₂, ECO-DAS28₃). In the original formula of DAS28, we replaced the clinical swollen joint count with the ultrasound results of the intra-articular PD signal. In ECO-DAS28₁, we considered to be swollen any joint with a PD signal ≥ 1 , in ECO-DAS28₂, any joint with a PD signal ≥ 2 and in ECO-DAS28₃, any joint with a PD signal grade 3. In the case of the 8 joints not assessed by ultrasound that are included in the DAS28 (shoulders, elbows, interphalangeal joints of the thumbs and knees), we took into account the data from the clinical evaluation.

The study was performed in accordance with the guidelines of the Declaration of Helsinki and the protocol was approved by the institutional ethics committee of research protocols for application. All of the patients gave their informed consent prior to inclusion in the study.

Statistical Analysis

We utilized the mean and standard deviation (SD) to express the continuous variables, and number (*n*) and percentage for the categorical variables. The calculation of the ECO-DAS28 was done

Table 1
Clinical and Demographic Characteristics of the Patients.

Characteristics	n = 86
Women, n (%)	65 (75)
Age, mean (SD)	58 (14)
Disease duration, mean (SD)	7 (7.9)
Treatment with DMARD, n (%)	71 (82.5)
Treatment with biological therapy, n (%)	25 (29)
Positive RF, n (%)	55 (67)
Patients with at least 1 SJ, n (%)	7 (8)
Patients with at least 1 TJ, n (%)	10 (9)
DAS28, mean (SD)	2.08 (0.39)
Patients in whom PD signal was detected, n (%)	23 (26.7)
ECO-DAS28 ₁ , mean (SD)	2.15 (0.45)
ECO-DAS28 ₂ , mean (SD)	2.13 (0.45)
ECO-DAS28 ₃ , mean (SD)	2.07 (0.39)

DAS28, Disease Activity Score in 28 joints; DMARD, disease-modifying antirheumatic drug; ECO-DAS28, DAS28 modified by ultrasound; n, number; PD, power Doppler; RF, rheumatoid factor; SD, standard deviation; SJ, swollen joints; TJ, tender joints.

with the same mathematical formula employed for DAS28.²⁴ For the correlations between the clinical and ultrasonographic activity indices, we utilized the Spearman test.

Results

We included a total of 86 patients, 65 (75%) of whom were women; the mean age (SD) was 58 years¹⁴ and the mean disease duration (SD) was 7 (7.9) years. The demographic and clinical characteristics of the patients are shown in Table 1.

In the clinical evaluation, only 7 patients had swollen joints: 6 of them with involvement of only 1 joint and the remaining patient had 2 inflamed joints. The mean (SD) of DAS28 was 2.08 (0.39).

Twenty-three patients (26.7%) had at least 1 joint with a positive PD signal. Of a total of 1720 joints evaluated by ultrasound, 36 (2%) showed an abnormal increase in vascularization in studies done using PD. The PD signal most frequently found in these patients was grade 1, occurring in 70% of the cases (25 joints) (Fig. 1).

Applying ECO-DAS28₁, with respect to the level of disease activity, we reclassified 11/86 (13%) of the patients, in addition to 10/86 (12%) with ECO-DAS28₂ and 2/86 (2%) with ECO-DAS28₃, respectively. In every case, the patients were reclassified toward a level of low disease activity and none of them toward moderate or high activity, in accordance with the new DAS28 value modified by ultrasound (ECO-DAS28) (Fig. 2).

We found an excellent correlation between DAS28 and the diverse ECO-DAS28 proposed (Spearman's rho for ECO-DAS28₁:

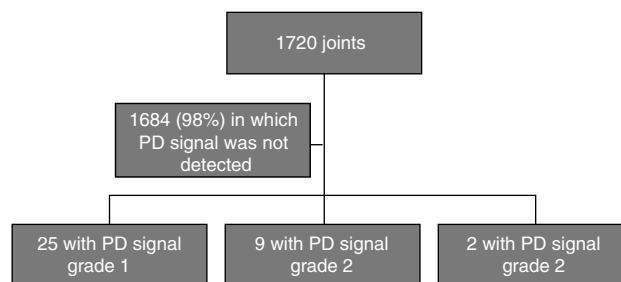


Fig. 1. Ultrasonographic findings in the evaluated joints. PD, power Doppler.

0.90; for ECO-DAS28₂: 0.91 and for ECO-DAS28₃: 0.95, respectively; $P < .001$) (Fig. 3).

Discussion

The present study proposes a combined clinical-ultrasonographic index for the evaluation of disease activity by DAS28 in patients with RA. Our objective was to evaluate the disease activity by DAS28, replacing the clinical evaluation of swollen joints with their ultrasound evaluation. In this study, we randomly selected only the joints of the hands and carpi, for the purpose of reducing the time and costs of the ultrasound examination.

The percentage of patients (26.7%) in whom we detected residual inflammatory activity, confirmed by the presence of a PD signal in the joint, was somewhat lower than that reported in earlier works. A meta-analysis by Nguyen et al. demonstrated the presence of subclinical synovitis with a positive PD signal in 44% of RA patients in clinical remission.¹⁷ Brown et al. showed, irrespective of the clinical criteria applied to define remission, that active inflammation was present by imaging techniques.³ In all, 73% of the patients in clinical remission had synovial hypertrophy in gray-scale images, and 43% had an increased intra-articular PD signal. The patients included in our study had few joints with positive PD signal and, in the great majority, they were grade 1. Our prevalence of nearly 30% is slightly lower than that reported in those articles, and this could be due to differences in the selection of the patients to be studied, to the different proficiency in the clinical evaluation for the detection of synovitis in distinct joints and to differences in the number and selection of the joints included in these studies.

Reclassification of the disease activity, utilizing the ECO-DAS28 indices, was observed in a small percentage of patients and, in every case, it was from a state of clinical remission toward a level of low

	Low activity	Moderate activity	High activity
ECO-DAS28 ¹	11/86 (13%)	0	0
ECO-DAS28 ²	10/86 (12%)	0	0
ECO-DAS28 ³	2/86 (2%)	0	0

Remission according to DAS28 (n = 86)

Fig. 2. Reclassification of the disease activity after application of the ECO-DAS28. DAS28, Disease Activity Score in 28 joints; ECO-DAS28, DAS28 modified by ultrasound.

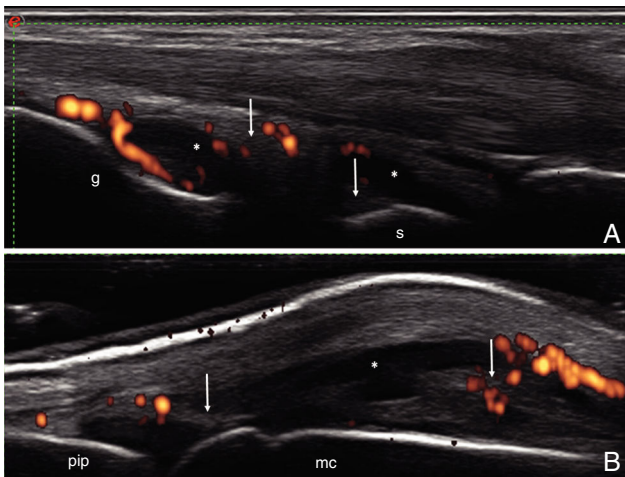


Fig. 3. (A) Carpus. Dorsal longitudinal plane. Capsular distension in the radiocarpal and intercarpal joints recesses, both with synovial fluid (*) and areas of synovial proliferation (arrow), with increased vascularization by power Doppler (grade 2). (B) Metacarpophalangeal joint. Dorsal longitudinal plane. Joint capsular distension with areas of synovial fluid (*) and areas of synovial proliferation (arrow), with increased vascularization by power Doppler (grade 2). l, large; mc, metacarpophalangeal joint; pip, proximal interphalangeal joint; r, radiocarpal; s, semilunar.

disease activity and in no instance toward a level of moderate or high activity.

The present work has certain limitations that should be mentioned. In the first place, not all of the 28 joints included in the DAS28 underwent ultrasound evaluation. Thus, the presence of subclinical activity may have been omitted in certain joints. However, several ultrasound scoring systems involving a reduced number of joints have been found to have an excellent correlation with others that include a larger number of joints. Most of those scoring systems include the carpus and the small joints of both hands, which were examined in our study.^{28–30} These simplified systems have been validated in patients with active RA for the monitoring of their therapeutic response, although they have not been utilized in routine practice in patients in clinical remission. Naredo et al. compared different reduced ultrasound scoring systems in patients with RA in clinical remission.⁷ On evaluating a 44-joint count, they detected the presence of synovial hypertrophy in 87.8% of the patients with a DAS28 < 2.6 and in 81.8% with the Simplified Disease Activity Index (SDAI) < 3.3. The PD signal was detected in 46.3% of the patients with a DAS28 < 2.6 and in 36.4% with the SDAI < 3.3. These authors demonstrated that ultrasound evaluation in the carpus, second to fifth metacarpophalangeal joints, ankle, and second to fifth metatarsophalangeal joints was highly sensitive for detecting synovitis by gray-scale and by PD signal, compared with the ultrasound evaluation of 44 joints. Secondly, the cross-sectional design of the present study does not enable us to establish whether this reclassification of the patients, even with low frequency and toward a state of low disease activity, could be associated with future relapses or progression of the radiographic damage.^{13,14,16,31} Finally, although the ultrasound examination was carried out by a rheumatologist with extensive experience in the technique, the lack of an evaluation of intra- and interobserver agreement concerning the ultrasound findings could reduce the internal validity of the study.

Our study demonstrated that the joint inflammatory process, assessed by PD ultrasound in hands and carpi, was not useful for reclassifying patients in remission to a state of higher activity. The great majority of the patients remained in the same level of activity, indicating that, in these patients, ultrasound did not change the parameter most widely used in real-world practice for making

therapeutic decisions, according to the treat-to-target recommendations.

In conclusion, the present report demonstrated residual activity detected by PD ultrasound in approximately a fourth of the patients with RA in clinical remission. This enabled the reclassification of the disease activity in a low percentage of these individuals, in every case toward a state of low disease activity. We consider that it would be very useful in this group of patients, to perform a prospective comparison of the utility of a multimodal index based on clinical-ultrasonographic monitoring with findings from an approach that focused on clinical monitoring. This may help to determine whether there are advantages to the use of ultrasound in the follow-up of patients with RA in clinical remission.

Ethical Disclosures

Protection of human and animal subjects. The authors declare that no experiments were performed on humans or animals for this study.

Confidentiality of data. The authors declare that they have followed the protocols of their work center on the publication of patient data.

Right to privacy and informed consent. The authors have obtained the written informed consent of the patients or subjects mentioned in the article. The corresponding author is in possession of this document.

Funding

The present report was financed by the Rheumatology Section of the Medical Clinic Department and Radiology Department of Hospital Italiano de Buenos Aires, Argentina.

Conflicts of Interest

The authors declare they have no conflicts of interest with respect to the present study.

References

- Naredo E, Iagnocco A. One year in review: ultrasound in arthritis. *Clin Exp Rheumatol*. 2016;34:1–10.
- Bruyn GA, Naredo E, Iagnocco A, Balint PV, Backhaus M, Gandjbakhch F, et al. The OMERACT ultrasound working group 10 years on: update at OMERACT 12. *J Rheumatol*. 2015;42:2172–6.
- Brown AK, Quinn MA, Karim Z, Conaghan PG, Peterfy CG, Hensor E, et al. Presence of significant synovitis in rheumatoid arthritis patients with disease-modifying antirheumatic drug-induced clinical remission: evidence from an imaging study may explain structural progression. *Arthritis Rheum*. 2006;54:3761–73.
- Naredo E, Bonilla G, Gamero F, Uson J, Carmona L, Laffon A. Assessment of inflammatory activity in rheumatoid arthritis: a comparative study of clinical evaluation with grey scale and power Doppler ultrasonography. *Ann Rheum Dis*. 2005;64:375–81.
- Citera G, Arriola MS, Maldonado-Cocco JA, Rosemffet MG, Sánchez MM, Goñi MA, et al. Validation and crosscultural adaptation of an Argentine Spanish version of the health assessment questionnaire disability index. *J Clin Rheumatol*. 2004;10:110–5.
- Gärtner M, Alasti F, Supp G, Mandl P, Smolen JS, Aletaha D. Persistence of subclinical sonographic joint activity in rheumatoid arthritis in sustained clinical remission. *Ann Rheum Dis*. 2015;74:1–4.
- Naredo E, Valor L, de la Torre I, Martínez-Barrio J, Hinojosa M, Aramburu F, et al. Ultrasound joint inflammation in rheumatoid arthritis in clinical remission: how many and which joints should be assessed? *Arthritis Care Res (Hoboken)*. 2013;65:512–7.
- Wakefield RJ, Green MJ, Marzo-Ortega H, Conaghan PG, Gibbon WW, McGonagle D, et al. Should oligoarthritis be reclassified? Ultrasound reveals a high prevalence of subclinical disease. *Ann Rheum Dis*. 2004;63:382–5.
- Kawashiri SY, Suzuki T, Nakashima Y, Horai Y, Okada A, Iwamoto N, et al. Ultrasonographic examination of rheumatoid arthritis patients who are free of physical synovitis: power Doppler subclinical synovitis is associated with bone erosion. *Rheumatology (Oxford)*. 2014;53:562–9.

10. Antonietta MD, Terslev L, Wakefield R, Østergaard M, Balint P, to Professor Paul Emery C. Novel algorithms for the pragmatic use of ultrasound in the management of patients with rheumatoid arthritis: from diagnosis to remission. *Ann Rheum Dis.* 2016;75:1–7.
11. Haavardsholm EA, Aga AB, Olsen IC, Lillegraven S, Hammer HB, Uhlig T, et al. Ultrasound in management of rheumatoid arthritis: ARCTIC randomised controlled strategy trial. *BMJ.* 2016;354:i4205.
12. Dale J, Stirling A, Zhang R, Purves D, Foley J, Sambrook M, et al. Targeting ultrasound remission in early rheumatoid arthritis: the results of the TaSER study, a randomised clinical trial. *Ann Rheum Dis.* 2016;75:1043–50.
13. Brown AK, Conaghan PG, Karim Z, Quinn MA, Ikeda K, Peterfy CG, et al. An explanation for the apparent dissociation between clinical remission and continued structural deterioration in rheumatoid arthritis. *Arthritis Rheum.* 2008;58:2958–67.
14. Foltz V, Gandjbakhch F, Etchepare F, Rosenberg C, Tanguy ML, Rozenberg S, et al. Power doppler ultrasound, but not low-field magnetic resonance imaging, predicts relapse and radiographic disease progression in rheumatoid arthritis patients with low levels of disease activity. *Arthritis Rheum.* 2012;64:67–76.
15. Dougados M, Deveuchelle-Pensec V, Ferlet JF, Jousse-Joulin S, D'Agostino MA, Backhaus M, et al. The ability of synovitis to predict structural damage in rheumatoid arthritis: a comparative study between clinical examination and ultrasound. *Ann Rheum Dis.* 2013;72:665–71.
16. Peluso G, Michelutti A, Bosello S, Gremese E, Tolusso B, Ferraccioli G. Clinical and ultrasonographic remission determines different chances of relapse in early and long standing rheumatoid arthritis. *Ann Rheum Dis.* 2011;70:172–5.
17. Nguyen H, Ruyssen-Witrand A, Gandjbakhch F, Constantin A, Foltz V, Cantagrel A. Prevalence of ultrasound-detected residual synovitis and risk of relapse and structural progression in rheumatoid arthritis patients in clinical remission: a systematic review and meta-analysis. *Rheumatology (Oxford).* 2014;53:2110–8.
18. Iwamoto T, Ikeda K, Hosokawa J, Yamagata M, Tanaka S, Norimoto A, et al. Prediction of relapse after discontinuation of biologic agents by ultrasonographic assessment in patients with rheumatoid arthritis in clinical remission: high predictive values of total gray-scale and power doppler scores that represent residual synovial. *Arthritis Care Res (Hoboken).* 2014;66:1576–81.
19. Zufferey P, Brulhart L, Tamborini G, Finckh A, Scherer A, Moller B, et al. Ultrasound evaluation of synovitis in RA: correlation with clinical disease activity and sensitivity to change in an observational cohort study. *Joint Bone Spine.* 2013;81:6–11.
20. Geng Y, Han J, Deng X, Zhang Z. Deep clinical remission: an optimised target in the management of rheumatoid arthritis? Experience from an ultrasonography study. *Clin Exp Rheumatol.* 2016;34:581–6.
21. Horton SC, Tan AL, Freeston JE, Wakefield RJ, Buch MH, Emery P. Discordance between the predictors of clinical and imaging remission in patients with early rheumatoid arthritis in clinical practice: implications for the use of ultrasound within a treatment-to-target strategy. *Rheumatology (Oxford).* 2016;55:1177–87.
22. Saleem B, Brown AK, Keen H, Nizam S, Freeston J, Wakefield R, et al. Should imaging be a component of rheumatoid arthritis remission criteria? A comparison between traditional and modified composite remission scores and imaging assessments. *Ann Rheum Dis.* 2011;70:792–8.
23. Aletaha D, Neogi T, Silman AJ, Funovits J, Felson DT, Bingham CO, et al. 2010 Rheumatoid arthritis classification criteria: an American College of Rheumatology/European League Against Rheumatism collaborative initiative. *Arthritis Rheum.* 2010;62:2569–81.
24. Prevoo ML, van't Hof MA, Kuper HH, van Leeuwen MA, van de Putte LB, van Riel PL. Modified disease activity scores that include twenty-eight-joint counts. Development and validation in a prospective longitudinal study of patients with rheumatoid arthritis. *Arthritis Rheum.* 1995;38:44–8.
25. Backhaus M, Burmester GR, Gerber T, Grassi W, Machold KP, Swen WA, et al. Guidelines for musculoskeletal ultrasound in rheumatology. *Ann Rheum Dis.* 2001;60:641–9.
26. Wakefield RJ, Balint PV, Szkudlarek M, Filippucci E, Backhaus M, D'Agostino M-A, et al. Musculoskeletal ultrasound including definitions for ultrasonographic pathology. *J Rheumatol.* 2005;32:2485–7.
27. Gutierrez M, Filippucci E, Salaffi F, di Geso L, Grassi W. Differential diagnosis between rheumatoid arthritis and psoriatic arthritis: the value of ultrasound findings at metacarpophalangeal joints level. *Ann Rheum Dis.* 2011;70:1111–4.
28. Naredo E, Rodríguez M, Campos C, Rodríguez-Heredia JM, Medina JA, Giner E, et al. Validity, reproducibility, and responsiveness of a twelve-joint simplified power Doppler ultrasonographic assessment of joint inflammation in rheumatoid arthritis. *Arthritis Care Res (Hoboken).* 2008;59:515–22.
29. Naredo E, Gamero F, Bonilla G, Uson J, Carmona L, Laffon A. Ultrasonographic assessment of inflammatory activity in rheumatoid arthritis: comparison of extended versus reduced joint evaluation. *Clin Exp Rheumatol.* 2005;23:881–4.
30. Rosa J, Ruta S, Saucedo C, Navarta DA, Catoggio LJ, García-Mónaco R, et al. Does a simplified 6-joint ultrasound index correlate well enough with the 28-Joint Disease Activity Score to be used in clinical practice? *J Clin Rheumatol.* 2016;22:179–83.
31. Scire CA, Montecucco C, Codullo V, Epis O, Todoerti M, Caporali R. Ultrasonographic evaluation of joint involvement in early rheumatoid arthritis in clinical remission: power Doppler signal predicts short-term relapse. *Rheumatology (Oxford).* 2009;48:1092–7.