



Sociedad Española  
de Reumatología -  
Colegio Mexicano  
de Reumatología

# Reumatología Clínica

www.reumatologiaclinica.org



## Case Report

### Extranodal marginal zone B cell lymphoma: An unexpected complication in children with Sjögren's syndrome



Paz Collado<sup>a,\*</sup>, Aml Kelada<sup>b,◇</sup>, Maria Cámara<sup>c</sup>, Andrew Zeft<sup>d</sup>, Aron Flagg<sup>b</sup>

<sup>a</sup> Department of Rheumatology/Paediatric Rheumatology Unit, Hospital Universitario Severo Ochoa, Madrid, Spain

<sup>b</sup> Department of Pediatric Hematology/Oncology and Blood & Marrow Transplant, Cleveland Clinic, OH, USA

<sup>c</sup> Pathologic Anatomy Department, Hospital Universitario Severo Ochoa, Madrid, Spain

<sup>d</sup> Center for Pediatric Rheumatology and Immunology Cleveland Clinic, OH, USA

#### ARTICLE INFO

##### Article history:

Received 9 November 2016

Accepted 26 January 2017

##### Keywords:

Sjögren's syndrome

Child

B-cell lymphoma

##### Palabras clave:

Síndrome de Sjögren

Niño

Linfoma de células B

#### ABSTRACT

Sjögren's syndrome (SS) is a systemic autoimmune disease characterized by the infiltration of lymphocytes into exocrine glands, resulting in the typical sicca symptoms. Unlike adults, primary SS is a very rare condition in childhood, and the risk of malignancy in juvenile SS (JSS) has not been defined.

We report the detection of extranodal marginal zone B-cell lymphoma (EMZL) occurring in two children with SS. Fine needle aspiration of the salivary glands (SG) showed nonspecific findings that led to delayed diagnosis of SS. The diagnosis of B-cell lymphoma associated with JSS was based on morphologic and immunohistochemical staining done during the biopsy.

To highlight awareness of EMZL as a timely and appropriate update of an unusual complication in children with SS.

© 2017 Elsevier España, S.L.U. and Sociedad Española de Reumatología y Colegio Mexicano de Reumatología. All rights reserved.

### Linfoma no Hodgkin de linfocitos B de la zona marginal, extranodal: una complicación inesperada en niños con síndrome de Sjögren

#### RESUMEN

El síndrome de Sjögren (SS) es una enfermedad sistémica autoinmune caracterizada por la infiltración de linfocitos en glándulas exocrinas, provocando el típico síndrome seco. A diferencia de los adultos, el SS es una afección rara en niños, y el riesgo de malignización no ha sido descrito.

Describimos la detección de linfoma B de la zona marginal extranodal de tejido linfoide asociado a mucosa (linfoma MALT) en 2 niños con SS. La aspiración con aguja fina de las glándulas salivares (SG) mostró hallazgos inespecíficos que retrasaron el diagnóstico de SS. El diagnóstico de linfoma B asociado a SS juvenil se realizó con base en los hallazgos morfológicos e inmunohistoquímicos detectados en biopsia.

Hay que tomar conciencia de que un linfoma B puede acontecer en el curso de un SS como una complicación inesperada en niños, principalmente para realizar una derivación correcta a oncología.

© 2017 Elsevier España, S.L.U. y Sociedad Española de Reumatología y Colegio Mexicano de Reumatología. Todos los derechos reservados.

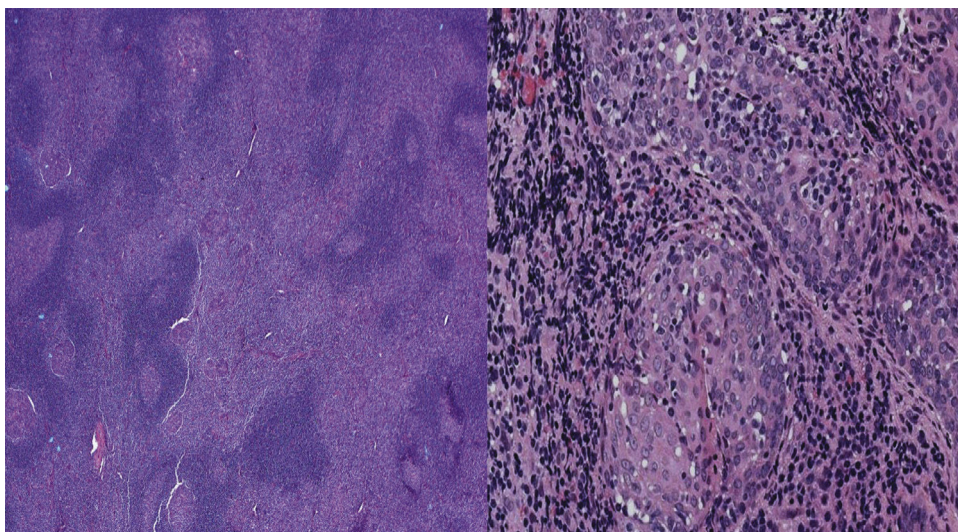
#### Introduction

Sjögren's syndrome (SS) is a systemic autoimmune disease characterized by the infiltration of lymphocytes in exocrine glands.<sup>1</sup> SS is a rare condition in childhood and ocular and oral symptoms are uncommon.<sup>2,3</sup> The risk of lymphoma development during the course of SS has been described in adults, but it is extremely rare

\* Corresponding author.

E-mail address: paxko10@gmail.com (P. Collado).

◇ These authors contributed equally to this work.



**Fig. 1.** Biopsy of extranodal marginal zone lymphoma of mucosa-associated lymphoid tissue of the parotid gland in case 2. Left image shows Hematoxylin & Eosin (H&E) stain in low-power view. Right image shows H&E stain in high-power view.

in childhood.<sup>1</sup> We report the association of lymphoma to SS in two children, as an unexpected complication.

## Case reports

### Case 1

A teenager followed since the age of 14 years for intermittent swelling of the knee with negative image and laboratory investigations. She developed SS at the age of 18 year showing intermittent swelling of parotid glands, positive RF, antinuclear antibodies (ANA) and anti-SSA antibodies, elevated erythrocyte sedimentation rate (ESR, 25 mm/1 h), but normal serum level of cryoglobulins, IgG4 and complement. The Schirmer test and serologic testing for virus were negative. The minor SG biopsy showed focal lymphocytic sialadenitis but the histopathologic diagnosis did not meet SS-criteria. Her follow-up showed the detection of a nodule on the hard palate with the diagnosis of B-cell lymphoma based on morphologic and immunohistochemical staining (CD20+ B cells) from nodule biopsy. Gastrointestinal endoscopy showed chronic gastritis (*Helicobacter pylori* negative). The computerized tomography (CT) of neck, chest, abdomen, and pelvis, showed no additional evidence of disease. Recently a new episode of right parotitis along with a biopsied cervical lymph node confirmed persistent lymphoma after 6 months of rituximab.

### Case 2

A 16-year-old boy presented with intermittent painless cervical lymphadenopathy and bilateral parotid swelling for more than 5 years. Neck CT demonstrated enlargement of the parotids. A fine needle aspiration showed a benign lymphoid tissue with no evidence of malignancy. Laboratory data showed an increased ESR (122 mm/h). Histopathology analysis showed infiltration of the salivary gland by a lymphocytic proliferation forming confluent nodular masses and follicular hyperplasia of the attached lymph nodes, indicative of a lymphoid malignancy (Fig. 1). Immunohistochemical stains demonstrated sheets of CD20+ B cells that were negative for CD5, CD43, and cyclin-D1, confirming B-cell clonal proliferation (Fig. 2). CD10 and BCL-6 stains highlighted germinal centers which were negative for BCL-2. A Ki-67 stain showed numerous positive cells within and between germinal centers (20–30% cells). Parotidectomy and radiotherapy was performed.



**Fig. 2.** Biopsy of low grade B-cell lymphoma of MALT type of the parotid gland. CD 20 stain showing sheets of B cells in case 2.

Serologic testing revealed only a remote infection by CMV and EBV. Immunological tests showed positive RF, ANA, anti-SSA and anti-SSB antibodies. Despite only vague sicca symptoms, ophthalmology exam revealed corneal and conjunctival erosions, and the diagnosis of SS was made. Hydroxychloroquine and rituximab were started. There was no evidence of tumor recurrence after >14 months follow-up.

## Discussion

In childhood, recurrent parotid swelling is the most common hallmark of SS, usually proceeding to sicca symptoms as in our patients.<sup>2</sup> Diagnostic criteria are similar to those proposed in adults<sup>3</sup>; however, it showed low sensitivity and histological findings of the minor SG criteria (>1 focus of 50 lymphocytes/4 mm<sup>2</sup>) are often negative in children.<sup>4</sup> It explains delayed diagnosis in the case 1, despite exclusion of infectious diseases at onset. The sensitivity increases by using a lesser score in childhood.<sup>5</sup>

The occurrence of lymphoma in SS is extremely rare in childhood. EMZL is a low-grade lymphoma that usually occurs in the setting of a benign myoepithelial sialadenitis (MESA) and biopsy confirms the diagnosis. Clonal expansion to EMZL is believed to

be triggered by chronic immune stimulation in the context of a preexisting inflammatory response from autoimmune diseases or chronic infections, amyloidosis, some translocations and common variable immunodeficiency.<sup>6–9</sup> Differences in Rituximab response might be a higher pretreatment number of CD20+ B cells/mm<sup>2</sup> parotid gland parenchyma.<sup>10</sup>

## Conclusion

SS requires child-specific criteria to rule out lymphoma as unusual complication in children, particularly for timely and appropriate referral.

## Ethical disclosures

**Protection of human and animal subjects.** The authors declare that the procedures followed were in accordance with the regulations of the relevant clinical research ethics committee and with those of the Code of Ethics of the World Medical Association (Declaration of Helsinki).

**Confidentiality of data.** The authors declare that they have followed the protocols of their work centre on the publication of patient data.

**Right to privacy and informed consent.** The authors have obtained the written informed consent of the patients or subjects mentioned in the article. The corresponding author is in possession of this document.

## Conflict of interest

None.

## References

1. Goules AV, Tzioufas AG. Primary Sjogren's syndrome: clinical phenotypes, outcome and the development of biomarkers. *Autoimmun Rev*. 2016;15:695–703.
2. Cimaz R, Casadei A, Rose C, Bartunkova J, Sediva A, Falcini F, et al. Primary Sjogren syndrome in the paediatric age: a multicentre survey. *Eur J Pediatr*. 2003;162:661–5.
3. Shiboski SC, Shiboski CH, Criswell L, Baer A, Challacombe S, Lanfranchi H, et al. American College of Rheumatology classification criteria for Sjogren's syndrome: a data-driven, expert consensus approach in the Sjogren's international Collaborative Clinical Alliance cohort. *Arthritis Care Res (Hoboken)*. 2012;64:475–87.
4. Houghton K, Malleson P, Cabral D, Petty R, Tucker L. Primary Sjogren's syndrome in children and adolescents: are proposed diagnostic criteria applicable. *J Rheumatol*. 2005;32:2225–32.
5. Lieberman SM. Childhood Sjogren syndrome: insights from adults and animal models. *Curr Opin Rheumatol*. 2013;25:651–7.
6. Stiller M, Golder W, Döring E, Biederman T. Primary and secondary Sjogren's syndrome in children—a comparative study. *Clin Oral Invest*. 2000;4:176–82.
7. Gabali A, Ross CW, Edwards PC, Schnitzer B, Danciu TE. Pediatric extranodal marginal zone b-cell lymphoma presenting as amyloidosis in minor salivary glands: a case report and review of the literature. *J Pediatr Hematol Oncol*. 2013;35:e130–3.
8. Piquer Gilbert M, Alsina L, Muñoz G, Cruz Martinez O, Ruiz Echevarria K, Dominguez O, et al. Non-Hodgkin lymphoma in pediatric patients with common variable immunodeficiency. *Eur J Pediatr*. 2015;174:1069–76.
9. Diss TC, Wotherspoon AC, Speight P. B-cell monoclonality, Epstein Barr virus, and t(14;18) in myoepithelial sialadenitis and low-grade B-cell MALT lymphoma of the parotid gland. *Am J Surg Pathol*. 1995;19:531–6.
10. Delli K, Haacke EA, Kroese FGM, Pollard RP, Ihrler S, van der Vegt B, et al. Towards personalised treatment in primary Sjogren's syndrome: baseline parotid histopathology predicts responsiveness to rituximab treatment. *Ann Rheum Dis*. 2016, <http://dx.doi.org/10.1136/annrheumdis-2015-208304>