



Sociedad Española
de Reumatología -
Colegio Mexicano
de Reumatología

Reumatología Clínica

www.reumatologiaclinica.org



Case Report

Rituximab Therapy in Necrotizing Autoimmune Myopathy Associated With Anti-SRP Antibody: A Clinical Case Review[☆]



Francisco Javier Nóvoa Medina,^{a,*} José Gutiérrez Martínez,^b Yeray González González,^c Beatriz Romero Díaz,^c Sergio Machín García,^a Antonio Rosas Romero^a

^a Servicio de Reumatología, Complejo Hospitalario Universitario Insular Materno-Infantil, Las Palmas de Gran Canaria, Las Palmas, Spain

^b Servicio de Neurología, Complejo Hospitalario Universitario Insular Materno-Infantil, Las Palmas de Gran Canaria, Las Palmas, Spain

^c Servicio de Radiodiagnóstico, Complejo Hospitalario Universitario Insular Materno-Infantil, Las Palmas de Gran Canaria, Las Palmas, Spain

ARTICLE INFO

Article history:

Received 10 September 2016

Accepted 24 February 2017

Available online 7 September 2018

Keywords:

Necrotizing autoimmune myopathy

Anti-signal recognition particle

Rituximab

ABSTRACT

Necrotizing autoimmune myopathy (NAM) is a rare and emerging entity of idiopathic inflammatory myopathy (IIM).

They have been associated with connective tissue disorders, viral infections, malignancy, anti-signal recognition particle (SRP) and anti-3-hydroxy-3-methylglutaryl-coenzyme A reductase protein (with or without the use of statins).

Anti-SRP-associated NAM has different clinical and histological characteristics that differentiate them from other IIMs, resulting in a poor prognosis. Very few cases treated with rituximab have been published, with varying clinical response.

Here we describe a case of anti-SRP-associated NAM refractory to conventional immunosuppressants and its successful long-term management with the combination of rituximab, corticosteroids and methotrexate.

© 2017 Elsevier España, S.L.U. and Sociedad Española de Reumatología y Colegio Mexicano de Reumatología. All rights reserved.

Tratamiento con rituximab para las miopatías necrosantes autoinmunes asociadas al anti-SRP: caso clínico y revisión de la evidencia

RESUMEN

Las miopatías necrosantes autoinmunes (NAM) son unas entidades raras y emergentes de las miopatías inflamatorias idiopáticas (MII).

Su presencia se ha asociado a conectivopatías, infecciones virales, neoplasias, anticuerpos frente a la partícula de reconocimiento de la señal (anti-SRP) y a anticuerpos frente a la proteína 3-hidroxi-3-metilglutaril-coenzima A reductasa (HMG-CR) (asociada al empleo o no de estatinas).

Las NAM asociadas al anti-SRP presentan unas características clínicas y anatomopatológicas que las diferencian del resto de las MII, resultando en un peor pronóstico. Hasta el momento han sido muy pocos los casos publicados tratados con rituximab y con diferente respuesta clínica.

Presentamos el caso de una mujer de 30 años con NAM asociada al anti-SRP refractaria a tratamiento convencional inmunosupresor y que ha sido controlada a largo plazo con la combinación de rituximab, metotrexato y corticoides.

© 2017 Elsevier España, S.L.U. y Sociedad Española de Reumatología y Colegio Mexicano de Reumatología. Todos los derechos reservados.

Palabras clave:

Miopatías necrosantes autoinmunes

Partícula de reconocimiento de la señal

Rituximab

[☆] Please cite this article as: Nóvoa Medina FJ, Gutiérrez Martínez J, González González Y, Romero Díaz B, Machín García S, Rosas Romero A. Tratamiento con rituximab para las miopatías necrosantes autoinmunes asociadas al anti-SRP: caso clínico y revisión de la evidencia. Reumatol Clin. 2018;14:379–381.

* Corresponding author.

E-mail address: fnovmed@hotmail.es (F.J. Nóvoa Medina).

Introduction

Necrotizing autoimmune myopathies (NAMs) usually present as a myopathy with marked elevation of creatine kinase (CK), characteristic histopathological findings (presence of necrotic and regenerative muscular fibres, near absence of inflammatory cell infiltrate) and poor response to standard treatment.

Anti-signal recognition particle (anti-SRP) antibodies were described for the first time in 1986¹ and later were described in patients diagnosed with inflammatory myopathies (IMs) with a more severe disease course. The anti-SRP antibodies are directed against a sub-unit of 54 kDa of several ribonucleoproteins with GTPase activated involved in the transport of new proteins to the endoplasmic reticulum.^{2–4}

Rituximab is a chimeric monoclonal antibody targeted at CD20, the use of which is standard in other connective tissue disorders.⁵ A series of published cases of NAM exist which were treated with rituximab, with varying clinical responses.^{6–10}

Clinical Case

A female aged 30 was diagnosed with NAM as a result of the presence of proximal myopathy, dysphagia to liquids and dysphonia of 2-month onset, elevation of muscular enzymes (CK 5.922 U/l, aldolase 84 U/l), electromyography with myopathic pattern, signs of intramuscular oedema on the magnetic resonance in shoulder and pelvic girdles (Fig. 1a) and anatomical–pathological findings

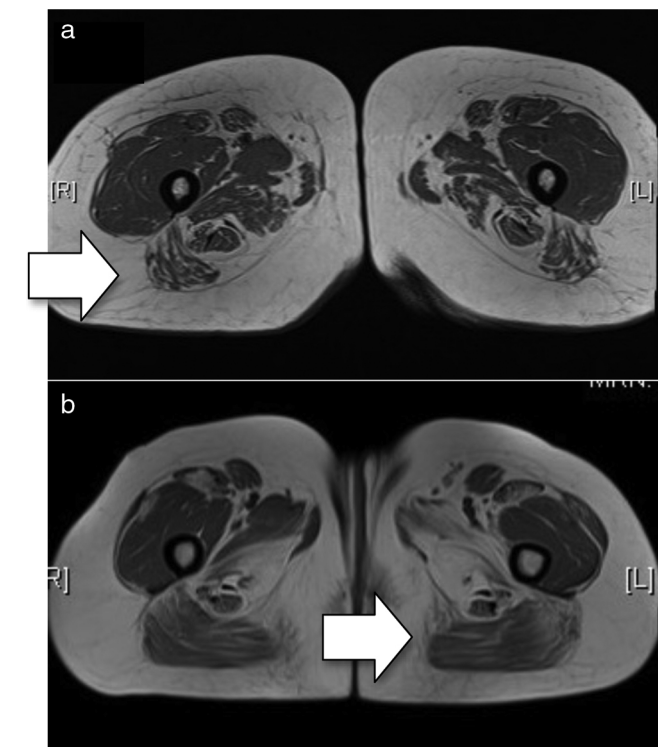


Figure 1. (a) Baseline MRI (T1 sequence). There is minimal oedema in the distal end of both the sartorius and gracilis muscles. Compromise of both compartments, with the lateral mass more affected in the anterior compartment and the middle masses more affected in the posterior compartment. In general, there is greater posterior compromise (arrow). (b) MRI after treatment with rituximab (T1 sequence). Bilateral and symmetrical compromise is noted of both compartments with muscular atrophy observed with diffuse fatty deposits. The lateral and middle masses are more affected in the anterior compartment and the hamstring muscles are more affected in the posterior compartment, with predominance of compromise in the posterior compartment (arrow).

of necrotic myopathy which had defied standard treatment (corticoids, immunoglobulins, azathioprine).

As a result of histological findings, anti-SRP antibodies were requested which resulted positive (IFI 1:1.280 technique). Treatment was initiated with methotrexate (up to 30 mg per week). Clinical symptoms improved after 3 months with the exception of the iliacus-psoas musculature (4/5). Progressive reduction of corticoids resulted in clinical and analytical deterioration. Concomitant treatment was subsequently started with rituximab (two 1-g doses). Five months later, the patient's condition was improved. After 6 months, a new cycle of rituximab was begun to maintain therapy response.

Magnetic resonance of the muscles after 2 years showed an absence of any signs of inflammatory activity (Fig. 1b).

As methotrexate was lowered below 22.5 mg per week, the patient again began to be clinically and analytically compromised, and the dose was therefore increased to regain clinical control in the last year (with the exception of iliacus-psoas musculature weakness).

Discussion

To our knowledge, less than 30 cases of anti-SRP NAMs treated with rituximab have been published.^{6–10} Pinal-Fernandez et al.⁷ describe 17 patients treated with rituximab, which was apparently effective in 13 of them. The duration of the biological effect of the rituximab was variable (from 6 to 9 months to over more than 2 years). In our patient, it has not been administered on more occasions since mid-2012.

Two refractory cases were also published which improved with the combination of corticoids, plasmapheresis and rituximab,⁸ as well as another two cases treated with rituximab with favourable outcomes.⁹

However, a British series¹⁰ of two patients treated with rituximab presented a poor clinical response.

In our case, two cycles of rituximab were administered, leading to an exacerbation on reduction of the dose of methotrexate, with favourable subsequent control when the dose was increased. The CK values of the patient were lower than that published in other series and this may be one of the reasons why a good therapeutic outcome was achieved. The imaging findings were also of note, where greater compromise of the posterior thigh compartment was noted when there were no apparent clinical signs of this.

Conclusion

NAMs should be suspected in patients with atypical findings, of MII, both histopathologically (presence of necrotic muscular fibres, near absence of inflammatory cell infiltrate) and clinically (poor response to immunosuppressants).

Rituximab could be a good therapeutic option for those cases where standard treatment has failed.

Ethical Liabilities

Protection of people and animals. The authors declare that no experiments using human beings or animals have been carried out for this research study.

Data confidentiality. The authors declare that no patient data appear in this article.

Right to privacy and informed consent. The authors declare that no patient data appear in this article.

Conflicts of Interest

The authors have no conflicts of interest to declare.

References

1. Reeves WH, Nigam SK, Blobel G. Human autoantibodies reactive with the signal recognition particle. *Proc Natl Acad Sci USA.* 1986;83:9507–11.
2. Romisch K, Miller FW, Dobberstein B, High S. Human autoantibodies against the 54 kDa protein of the signal recognition particle block function at multiple stages. *Arthritis Res Ther.* 2006;8:R39.
3. Utz PJ, Hottel M, Le TM, Kim SJ, Geiger ME, van Venrooij WJ, et al. The 72-kDa component of signal recognition particle is cleaved during apoptosis. *J Biol Chem.* 1998;273:35362–70.
4. Arana-Argáez VE, Delgado-Rizo V, Pizano-Martínez OE, Martínez-García EA, Martín-Márquez BT, Muñoz-Gómez A, et al. Inhibitors of MAPK pathway ERK1/2 or p38 prevent the IL-1 β -induced Up-regulation of SRP72 autoantigen in Jurkat cells. *J Biol Chem.* 2010;285:32824–33.
5. Randall KL. Rituximab in autoimmune diseases. *Aust Prescr.* 2016;39:131–4.
6. Valiyil R, Casciola-Rosen L, Hong G, Mammen A, Christopher-Stiner L. Rituximab therapy for myopathy associated with anti-signal recognition particle antibodies: a case series. *Arthritis Care Res (Hoboken).* 2010;62:1328–34.
7. Pinal-Fernandez I, Parks C, Werner JL, Akbayda J, Paik J, Danoff SK, et al. Longitudinal course of disease in a large cohort of myositis patients with autoantibodies recognizing the signal recognition particle. *Arthritis Care Res (Hoboken).* 2017;69:263–70.
8. Arlet JB, Dimitri D, Pagnoux C, Boyer O, Maisonobe T, Authier FJ, et al. Marked efficacy of a therapeutic strategy associating prednisone and plasma exchange followed by rituximab in two patients with refractory myopathy associated with antibodies to the signal recognition particle (SRP). *Neuromuscul Disord.* 2006;16:334–6.
9. Deligny C, Goeb V, Dueymes M, Kahn V, Dehlinger V, Jean Baptiste G, et al. Rituximab therapy for myopathy associated with anti-signal recognition particle antibodies: a case series. *Arthritis Care Res (Hoboken).* 2011;63:460.
10. Whelan BR, Isenberg DA. Poor response of anti-SRP-positive idiopathic immune myositis to B-cell depletion. *Rheumatology (Oxford).* 2009;48:594–5.