




Sociedad Española
de Reumatología -
Colegio Mexicano
de Reumatología

Reumatología Clínica

www.reumatologiaclinica.org



Images in Clinical Rheumatology

Imaging in Myositis Ossificans: Bone Scintigraphy and 18F-fluorodeoxyglucose Positron Emission Tomography/computed Tomography[☆]



Miositis osificante: gammagrafía ósea y tomografía por emisión de positrones/tomografía computarizada con 18F-desoxiglucosa

Marta Sánchez Aguilar,^{*} Rosario García Jiménez, Isabel Borrego Dorado

Servicio de Medicina Nuclear, Hospital Universitario Virgen del Rocío, Sevilla, Spain

ARTICLE INFO

Article history:

Received 2 July 2016

Accepted 26 January 2017

Available online 24 August 2018

Myositis ossificans is a heterotopic calcification consisting of the transformation of primitive mesenchymal cells, present in the muscle connective tissue, into osteogenic cells. This disorder can be hereditary, and can affect up to 2 children per million or, to a larger extent, be acquired secondarily to orthopedic and traumatic injuries,^{1,2} with greater incidence during the second and third decades of life. It is associated with skeletal anomalies, erythema, reduction of joint mobility and can mimic the clinical presentation of cellulitis, osteomyelitis or thrombophlebitis.

We report the case of a 66-year-old man, with a history of hematoma involving fibrous tissue. He underwent an intervention in left thigh, while in orthopedic follow-up. We performed bone scintigraphy after the administration of 815 MBq of ^{99m}Tc-hydroxymethylene-diphosphonate. We observed an abnormal increase in the osteoblastic activity in soft tissues of the middle and proximal third of left thigh up to left hip, with uptake of the tracer in the region of adjacent soft tissues and changes in normal bone morphology (Fig. 1A) compatible with myositis ossificans. After a course of several years, and in the clinical context of a lesion suggestive of a lung neoplasm, we performed positron emission tomography-computed tomography (PET/CT)

after administration of 370 mBq of 18-fluorodeoxyglucose (18F-FDG). We observed several accumulations of the radiotracer that were distributed by the posteroinferior planes of the left buttock up to the middle third of the ipsilateral thigh (Fig. 1B), with a maximum standardized uptake value (SUVmax) of 9.1 in relation to a lesion with a highly heterogeneous morphology, with areas that were calcified, hypodense and formed by soft tissues. These findings would correspond to myositis ossificans located exactly beneath the tip of the greater trochanter.³ Unlike metastatic calcifications, that are associated with a change in the calcium phosphate metabolism, myositis ossificans can appear as a complication of muscle injury with hematoma secondary to inflammation of the fascia following a neurological lesion, surgery, traumatic injury or a burn.⁴

Although it is not a frequent finding in PET/CT studies, some investigations provide evidence of its use as a suitable tool in the evaluation of biological activity in soft tissues.^{5,6}

Treatment depends on the degree of functional involvement, based on approaches involving radiotherapy, nonsteroidal anti-inflammatory drugs or diphosphonates⁷ with preventive intention, or surgical resection and rehabilitation in established cases.^{2,8}

[☆] Please cite this article as: Sánchez Aguilar M, García Jiménez R, Borrego Dorado I. Miositis osificante: gammagrafía ósea y tomografía por emisión de positrones/tomografía computarizada con 18F-desoxiglucosa. Reumatol Clin. 2018;14:309–310.

^{*} Corresponding author.

E-mail address: marta231087@hotmail.com (M. Sánchez Aguilar).

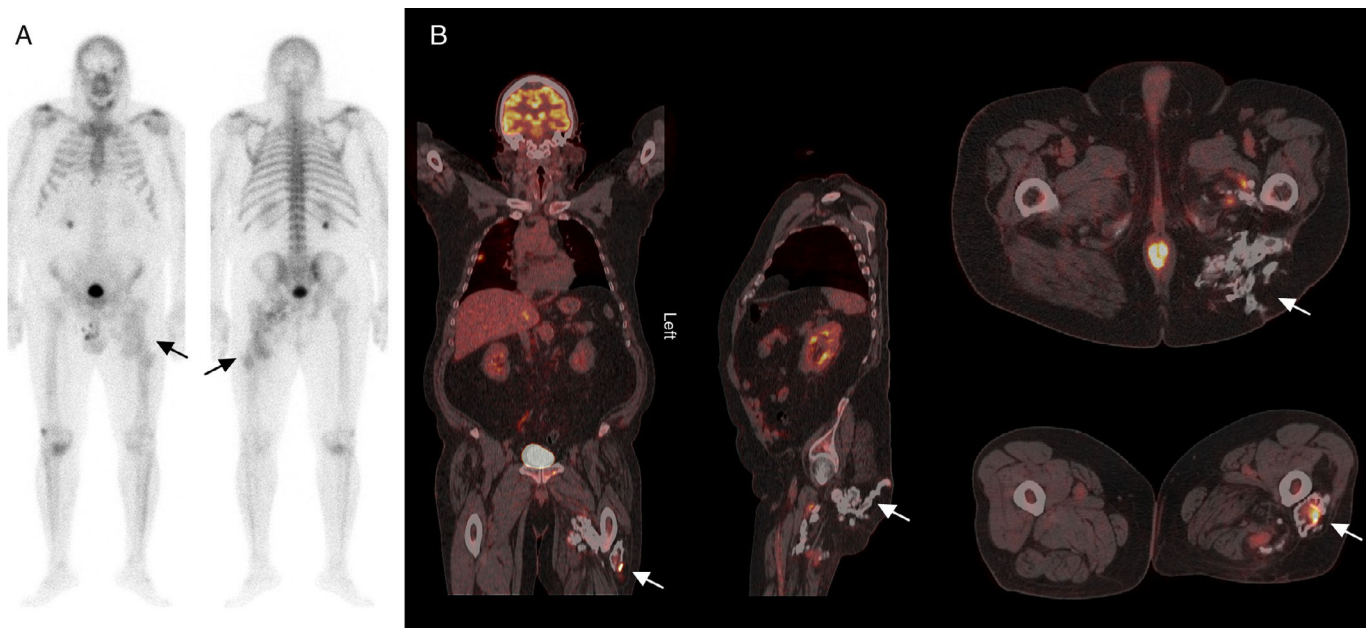


Fig. 1. (A) Whole body bone scan with ^{99m}Tc -hydroxymethylene-diphosphonate in anterior and posterior projections that show a pathological and irregular increase in osteoblastic activity in the middle and proximal thirds of left thigh, with tracer uptake in adjacent soft tissues and a change in the normal bone morphology (arrows). (B) Coronal, sagittal and axial images of the ^{18}F -fluorodeoxyglucose positron emission tomography/computed tomography study showing multiple abnormal accumulations of the radiotracer that are distributed from posteroinferior planes of the left buttock up to the middle third of the ipsilateral thigh (arrows).

Ethical Disclosures

Protection of human and animal subjects. The authors declare that no experiments were performed on humans or animals for this study.

Confidentiality of data. The authors declare that they have followed the protocols of their work center on the publication of patient data.

Right to privacy and informed consent. The authors declare that no patient data appear in this article.

Conflicts of Interest

The authors declare they have no conflicts of interest.

References

1. Lima MC, Passarelli MC, Dario V, Lebani BR, Monteiro PHS, Ramos CD. Use of SPECT/CT in the evaluation of heterotopic ossification in para/tetraplegics.

Acta Ortop Bras [online]. 2014;22:12–6. Available from: <http://www.scielo.br/aob> [accessed December 2016].

2. Shehab D, Elgazzar AH, Collier D. Heterotopic ossification. *J Nucl Med.* 2002;43:346–53.
3. Schmidt J, Hackenbroch MH. A new classification for heterotopic ossification in total hip arthroplasty considering the surgical approach. *Arch Orthop Trauma Surg.* 1996;115:339–43.
4. Azriel Mira S, Martínez Díaz-Guerra G, Jodar Gimeno E, Hawkins Carranza F. Calcificaciones y osificaciones ectópicas. *Rev Esp Enferm Metab Oseas.* 2001;10:168–72.
5. Schulte M, Brecht-Krauss D, Heymer B, Guhlmann A, Hartwig E, Sarkar MR, et al. Fluorodeoxyglucose positron emission tomography of soft tissue tumours: is a non-invasive determination of biological activity possible? *Eur J Nucl Med.* 1999;2:599–605.
6. Clarençon F, Larousserie F, Babinet A, Zylbersztein C, Talbot JN, Kerrou K. FDG PET/CT findings in a case of myositis ossificans circumscripta of the forearm. *Clin Nucl Med.* 2011;36:40–2.
7. Garland DE. A clinical perspective on common forms of acquired heterotopic ossification. *Clin Orthop.* 1991;263:13–29.
8. Tanaka T, Rossier AB, Hussey RW, Ahnberg DS, Treves S. Quantitative assessment of para-osteo-arthropathy and its maturation on serial radionuclide bone images. *Radiology.* 1977;123:217–21.