



Sociedad Española
de Reumatología -
Colegio Mexicano
de Reumatología



Images in Clinical Rheumatology

Single-photon Emission Computed Tomography in the Diagnosis of a Case of Forestier's Disease[☆]

Single-photon emission computed tomography en el diagnóstico de un caso de enfermedad de Forestier

María Isabel Morales Lozano,^{a,*} Enrique Ornilla,^b Lidia Sancho,^a Edgar Fernando Guillén^a

^a Servicio de Reumatología, Clínica Universidad de Navarra, Pamplona, Navarra, Spain

^b Servicio de Medicina Nuclear, Clínica Universidad de Navarra, Pamplona, Navarra, Spain

ARTICLE INFO

Article history:

Received 27 January 2017

Accepted 24 March 2017

Available online 19 September 2018

A 62 year old male presented with long-term back pain, which was inflammatory/mixed in rhythm and had been progressively worsening. He also presented with pain in his hips, knees, and feet, with no other signs or symptoms of osteoarthritis.

Physical examination of the patient revealed that his movement was limited in all axes and Schöber's test was 3 cm.

Our hospital performed X-rays of the cervical, dorsal, lumbar and pelvic spine which showed a calcification of the anterior common vertebral ligament with preservation of the disc spaces (Figs. 1 and 2).

In view of these findings the patient was referred to the nuclear medical unit for a bone scan to rule out several causes of osteoarthritis, Forestier's disease among them.

Forestier's disease is related to abnormal bone growth.¹⁻³ The main disease symptoms is calcification of the longitudinal ligaments of the spine, involving at least 4 contiguous vertebrae. Other criteria are the preservation of intervertebral disc spaces and the absence of inflammatory changes in intrapophyseal or sacroiliac joints.⁴⁻⁶

In the bone scan images there was no sign of articular pathological uptake (Fig. 3). Multimodality SPECT/CT tomographic images were then acquired (Figs. 4 and 5), which were used both for qualitative visual analysis of the sacroiliac joint, and for quantitative analysis which permitted the obtainment of indicators

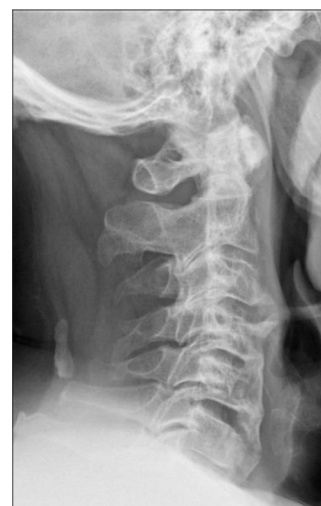

Fig. 1. Cervical spine X-ray: the height of the vertebral bodies are preserved. Calcification projected onto the soft tissues in the dorsal section in the occipito-vertebral ligament.

of the sacroiliac-promontory. In visual analysis calcification of the anterior common vertebral ligament was detected, together with absence of sacroiliac uptake. With this information and inferior promontory-sacroiliac indicators below the established cut-off level for diagnosis of sacroiliitis, diagnosis of ankylosing spondylitis was excluded, with support for the diagnosis of Forestier's disease.

[☆] Please cite this article as: Morales Lozano MI, Ornilla E, Sancho L, Guillén EF. *Single-photon emission computed tomography* en el diagnóstico de un caso de enfermedad de Forestier. *Reumatol Clin.* 2019;15:307–308.

* Corresponding author.

E-mail address: mmlozano@unav.es (M.I. Morales Lozano).

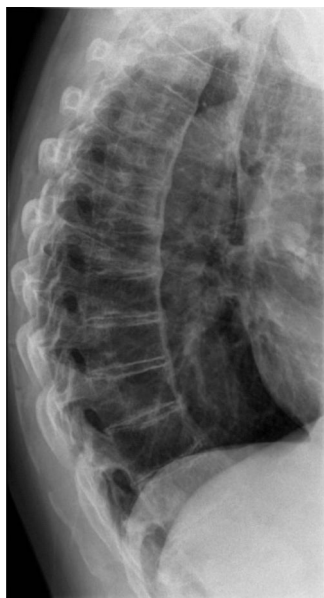

Fig. 2. Dorsal spine X-ray: calcification of the common anterior vertebral ligament.

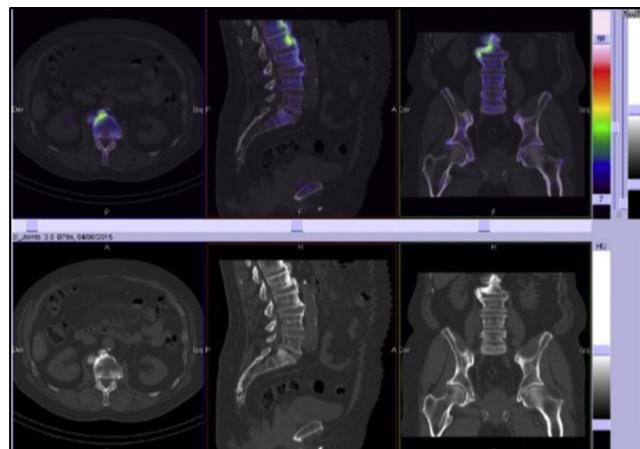


Fig. 5. SPECT/CT: calcification of common anterior vertebral ligament and preservation of intervertebral disc spaces.

Ethical Responsibilities

Protection of people and animals. The authors declare that this research has not been carried out experiments on humans or animals.

Data confidentiality. The authors declare that they have adhered to the protocols of their centre of work on the publication of patient data.

Right to privacy and informed consent. The authors declare that no patient data appear in this article.

Conflict of interests

The authors have no conflict of interests to declare.

References

- Hannallah D, White AP, Goldberg G, Albert TJ. Diffuse idiopathic skeletal hyperostosis. *Oper Tech Orthop.* 2007;17:174–7.
- Jensen J, ur Rehman H. Diffuse idiopathic skeletal hyperostosis. *J Gen Intern Med.* 2013;8:31–2.
- Nascimento F, Maranhã L, Oliver R, Mello H, Demartini Z, Koppe G, et al. Diffuse idiopathic skeletal hyperostosis: a review. *Surg Neurol Int.* 2014;5 Suppl. 3:S122–5.
- Resnick D, Niwayama G. Radiographic and pathologic features of spinal involvement in diffuse idiopathic skeletal hyperostosis (DISH). *Radiology.* 1976;119:559–68.
- Utsinger PD. Diffuse idiopathic skeletal hyperostosis. *Clin Rheum Dis.* 1985;11:325–51.
- Forestier J, Rotes-Querol J. Senile ankylosing hyperostosis of the spine. *Ann Rheum Dis.* 1950;9:321–30.
- Rodriguez LS, Ornilla E, Prieto E, Ribelles M, Garcia-Velloso M, Richter J. Quantitative bone SPECT/CT versus MRI in the early diagnosis of axial spondyloarthritis. *JNM.* 2013;54 Suppl. 2:1974.
- Sancho L, Ornilla E, Prieto E, Ribelles M, Garcia-Velloso M, Caicedo C, et al. Diagnostic value of quantitative SPECT/CT versus MRI for the assessment of sacroiliitis in early axial spondyloarthritis. *Eur J Nucl Med Mol Imag.* 2013;40 Suppl. 2:S242–3.

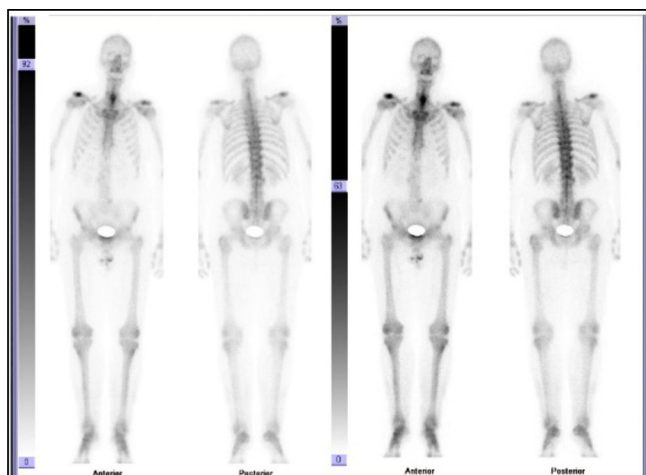


Fig. 3. Bone scan with normal pattern of uptake on the cervico dorsal skeleton and discrete uptake on the right-hand side of the lumbar rachis.

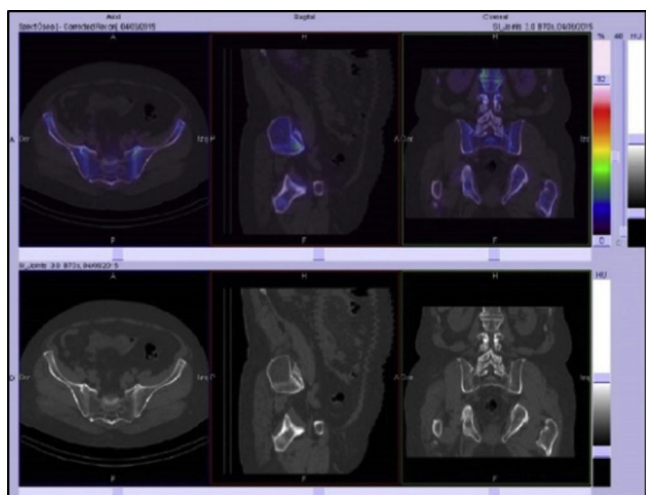


Fig. 4. SPECT/CT slice images in axial, sagittal and coronal planes with low uptake of the radiopharmaceutical in sacroiliac joints. Sacroiliac/promontory values below cut-off level established for diagnosis of sacroiliitis.^{7,8}