



Sociedad Española  
de Reumatología -  
Colegio Mexicano  
de Reumatología

# Reumatología Clínica

www.reumatologiaclinica.org



Images in Clinical Rheumatology

## Ultrasonography as a Diagnostic and Monitoring Tool for the Tendon Xanthomas in Familial Hypercholesterolemia<sup>☆</sup>

Ecografía en el diagnóstico y manejo de los xantomas tendinosos en la hipercolesterolemia familiar

Delia Reina,<sup>a,\*</sup> Carlos Jericó,<sup>b</sup> Paula Estrada,<sup>a</sup> Vanesa Navarro,<sup>a</sup> Vicenç Torrente,<sup>a</sup> Pedro Armario,<sup>b</sup> Hèctor Corominas<sup>a</sup>

<sup>a</sup> Servei de Reumatologia, Hospital Moisès Broggi/Hospital General de L'Hospitalet, Consorci Sanitari Integral (CSI), Sant Joan Despí/L'Hospitalet, Barcelona, Spain

<sup>b</sup> Servei de Medicina Interna, Àrea d'Atenció Integrada de Risc Vascular, Hospital Moisès Broggi/Hospital General de L'Hospitalet, Consorci Sanitari Integral (CSI), Sant Joan Despí/L'Hospitalet, Barcelona, Spain

### ARTICLE INFO

#### Article history:

Received 5 January 2017

Accepted 30 March 2017

Available online 20 September 2018

### Introduction

Hyperlipidaemia can present accompanied by tendon xanthomatosis. Xanthomas are clusters of collagen and cholesterol-filled macrophages. The Achilles tendon, extensor tendons of the hand, and the elbow tendons are principally affected. Joint ultrasound can be a very useful tool for diagnosing and monitoring the course of tendon xanthomas. Clinicians usually request screening for xanthoma in patients with suspected family hypercholesterolemia (FH), since the presence of xanthomas forms part of the diagnostic criteria of the disease.

### Presentation of the Clinical Case

A 59-year-old male, ex smoker, hypertensive with long-term hypercholesterolemia treated with statins, although with poor adherence. Ischaemic heart disease that started as a myocardial infarction with no ST segment elevation Killip class II a year previously, with 3-vessel coronary disease that required surgical revascularisation with quadruple bypass. Several of his first-degree family members had premature ischaemic heart disease and hypercholesterolemia. Physical examination revealed no corneal arcus

or xanthelasma, but did find thickening of the Achilles tendons, and the presence of tendon xanthomas on the knuckles of both hands (Figs. 1A and 2A). The patient had no heart or carotid murmurs. Trunk obesity (height 1.78 m, weight 97.5 kg, BMI 30.8 kg/m<sup>2</sup>, waist circumference 108 cm), BP: 120/65 mmHg, no visceromegaly. Palpable and symmetrical distal pulses.

Laboratory tests showed, without lipid-lowering treatment, a total cholesterol of 424 mg/dl, cHDL 45 mg/dl and cLDL 352 mg/dl, triglycerides 136 mg/dl and glycaemia, glomerular filtration rate, transaminases and thyroid function within the normal range.

With a certain diagnosis of heterozygous FH according to the clinical criteria,<sup>1</sup> and in a patient at very high risk due to established cardiovascular disease, aggressive lipid-lowering treatment was started with a high dose statin (atorvastatin 80 mg) combined with ezetimibe 10 mg.

Ultrasound was requested to assess the xanthomas, which revealed thickening of the Achilles tendons (D>1)<sup>2</sup> with loss of their homogeneous fibrillar structure, with a hypoechoic area in the inner middle third, compatible with xanthomas at this level.<sup>3,4</sup> The same ultrasound image was also observed in various extensor tendons of the hands (Figs. 1B and 2B).

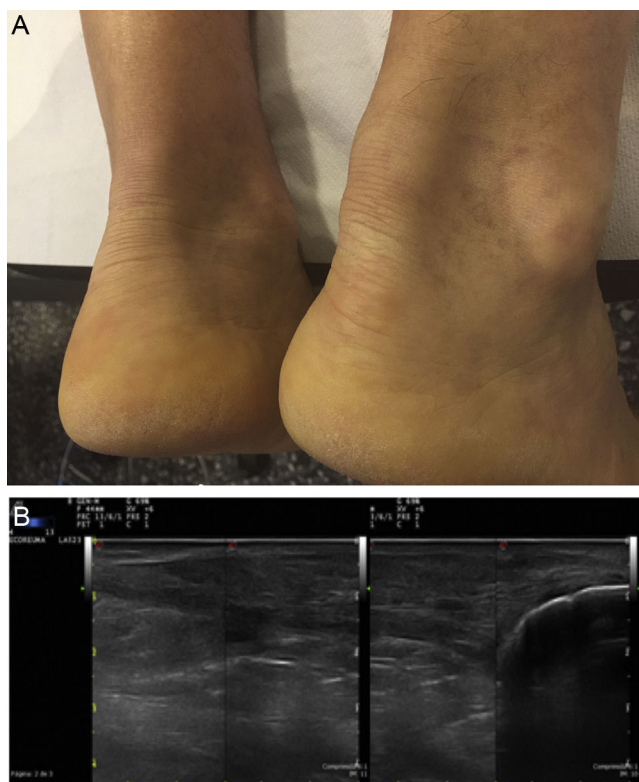
### Comments/discussion

Tendon xanthomas are characterised by a proliferation of foam cells, and deposition of unesterified cholesterol in the extracellular space of the extensor tendons of the hands, elbows, feet and Achilles tendons.<sup>5</sup> These xanthomas are normally associated with hyperlipidaemia, FH is the most frequently associated disease, and

<sup>☆</sup> Please cite this article as: Reina D, Jericó C, Estrada P, Navarro V, Torrente V, Armario P, et al. Ecografía en el diagnóstico y manejo de los xantomas tendinosos en la hipercolesterolemia familiar. Reumatol Clin. 2019;15:305–306.

\* Corresponding author.

E-mail address: [Deliareinasanz@gmail.com](mailto:Deliareinasanz@gmail.com) (D. Reina).



**Fig. 1.** A. Tendon xanthomas on Achilles tendons. B. Ultrasound of the same patient, of the Achilles tendon: a thickened tendon can be seen on a longitudinal slice, of heterogeneous echotexture.

there is a correlation between the thickness of the xanthoma and the degree of hypercholesterolaemia.<sup>6,7</sup>

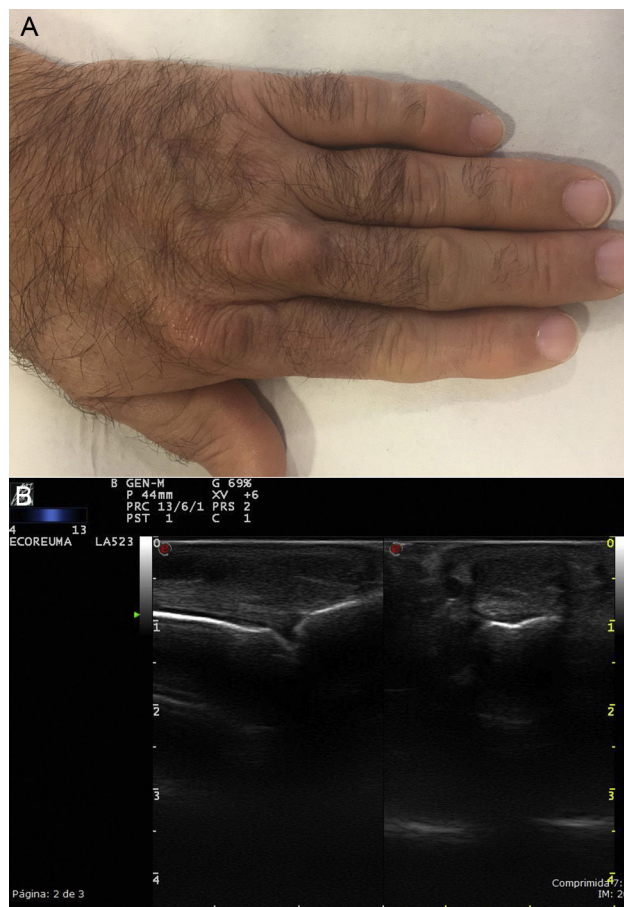Although it is true that ultrasound findings of xanthomas are not pathognomonic, and that these findings must be contextualised, the systemic use of ultrasound in patients with FH allows tendon xanthomas to be identified and measured in any of their possible sites, even those that are not detectable on physical examination. Ultrasound can help in the diagnosis of FH, and to monitor the effect of lipid-lowering therapy on xanthomas.

#### Ethical Responsibilities

**Protection of people and animals.** The authors declare that neither human nor animal testing has been carried out under this research.

**Data confidentiality.** The authors declare that they have complied with their work centre protocols for the publication of patient data.

**Privacy rights and informed consent.** The authors declare that no patients' data appear in this article



**Fig. 2.** A. Tendon xanthomas on the extensor tendons of the fingers. B. Ultrasound of the same patient, extensor tendon of the third finger: a thickened tendon can be seen on a transversal and longitudinal slice, of heterogeneous echotexture.

#### Conflict of Interests

The authors have no conflict of interests to declare.

#### References

- Nordestgaard BG, Chapman MJ, Humphries SE, Ginsberg HN, Masana L, Descamps OS, et al. European Atherosclerosis Society Consensus Panel. Familial hypercholesterolaemia is underdiagnosed and undertreated in the general population: guidance for clinicians to prevent coronary heart disease consensus statement of the European Atherosclerosis Society. *Eur Heart J.* 2013;34:3478–90.
- Wakefield RJ, Balint PV, Szkudlarek M, Filippucci E, Backaus M, D'Agostino MA, et al. Musculoskeletal ultrasound including definitions for ultrasonographic pathology. *J Rheumatol.* 2005;32:2485–7.
- Sanclemente C, García JM, Vilaró J, Ribé J. Xantomas tendinosos aquíleos. *Clin Invest Arterioscl.* 2006;18:68.
- Junyent M, Ros E. Ecografía del tendón de Aquiles en el diagnóstico de hipercolesterolemia familiar. *Clin Invest Arterioscl.* 2006;18:69.
- Lahoz C, Mostaza JM. Anatomía del depósito de lípidos. *Med Clin (Barc).* 1998;111:56–7.
- Vinson RP, Harrington AC. Clinical significance and treatment of xanthomas. *Am Fam Phys.* 1991;44:1206–10.
- Garcés C, Rodríguez Artalejo F, Serrano A, González Bonillo J, Almagro F, Garrido JA, et al. Manifestaciones clínicas de la hipercolesterolemia familiar heterocigótica. Estudio de 301 casos de la zona centro y norte. *Med Clin (Barc).* 2000;114:50–1.