



Sociedad Española  
de Reumatología -  
Colegio Mexicano  
de Reumatología

# Reumatología Clínica

www.reumatologiaclinica.org



## Case Report

### Tjalma Syndrome (Pseudo-pseudo Meigs') as Initial Manifestation of Juvenile-onset Systemic Lupus Erythematosus<sup>☆</sup>

Alfonso Ragnar Torres Jiménez,<sup>a,\*</sup> Eunice Solís-Vallejo,<sup>a</sup> Adriana Ivonne Céspedes-Cruz,<sup>a</sup> Maritza Zeferino Cruz,<sup>a</sup> Edna Zoraida Rojas-Curiel,<sup>b</sup> Berenice Sánchez-Jara<sup>c</sup>

<sup>a</sup> Reumatología Pediátrica, Hospital General, Centro Médico Nacional La Raza, IMSS, Mexico City, Mexico

<sup>b</sup> Cirugía Oncológica Pediátrica, Hospital General, Centro Médico Nacional La Raza, IMSS, Mexico City, Mexico

<sup>c</sup> Hematología Pediátrica, Hospital General, Centro Médico Nacional La Raza, IMSS, Mexico City, Mexico

#### ARTICLE INFO

##### Article history:

Received 3 November 2016

Accepted 5 April 2017

Available online 4 October 2018

##### Keywords:

Tjalma syndrome

Pseudo-pseudo Meigs'

Systemic lupus erythematosus

CA-125

#### ABSTRACT

Tjalma syndrome or pseudo-pseudo Meigs' syndrome is a clinical condition characterized by pleural effusion, ascites and elevated CA-125 with no associated benign or malignant ovarian tumor in a patient with systemic lupus erythematosus (SLE). Tjalma described the first case of a patient with SLE, pleural effusion, ascites and elevated CA-125. We report the first case in a 14-year old patient who presented with ascites and pleural effusion refractory to treatment and elevated CA-125, in the absence of an ovarian tumor, that warranted aggressive management.

© 2017 Elsevier España, S.L.U. and Sociedad Española de Reumatología y Colegio Mexicano de Reumatología. All rights reserved.

### Síndrome de Tjalma (pseudo-pseudo Meigs) como manifestación inicial de lupus eritematoso sistémico de inicio juvenil

#### RESUMEN

El síndrome de Tjalma o pseudo-pseudo Meigs es una entidad clínica que se presenta con derrame pleural, ascitis y elevación de CA-125 sin asociación a tumor ovárico benigno o maligno en un paciente con lupus eritematoso sistémico (LES). Tjalma describió el primer caso de un paciente con LES, ascitis, derrame pleural y elevación de CA-125. Presentamos el primer caso en una paciente pediátrica de 14 años, que se presentó con ascitis y derrame pleural refractarios a tratamiento con elevación de CA-125, sin encontrar tumor ovárico, que ameritó manejo agresivo.

© 2017 Elsevier España, S.L.U. y Sociedad Española de Reumatología y Colegio Mexicano de Reumatología. Todos los derechos reservados.

##### Palabras clave:

Síndrome de Tjalma

Pseudo-pseudo Meigs

Lupus eritematoso sistémico

CA-125

## Introduction

The presence of ovarian tumor (primary fibroma, thecoma, Brenner tumor), pleural effusion and ascites is referred to as Meigs' syndrome. When it is associated with tumors other than those mentioned above, it is known as pseudo-Meigs' syndrome. Tjalma

described pseudo-pseudo-Meigs' syndrome as a clinical condition that is accompanied by pleural effusion, ascites and elevated cancer antigen (CA) 125, with no associated benign or malignant ovarian tumor, in patients with systemic lupus erythematosus (SLE).<sup>1–4</sup> We present the case of a 14-year-old girl with Tjalma syndrome, to date the only report of this condition in a pediatric patient.

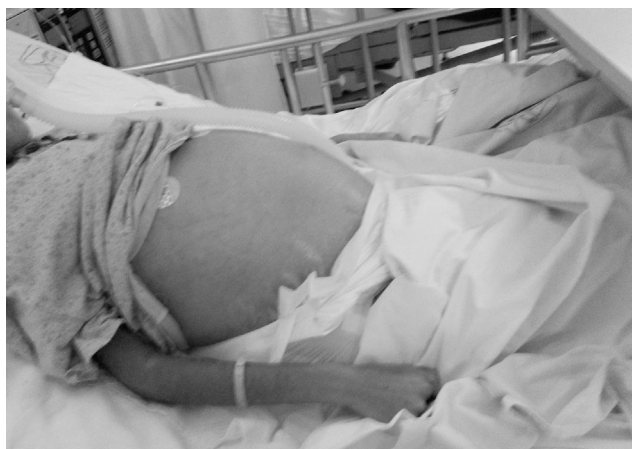## Case Report

The patient was a 14-year-old girl who had a history of 2 weeks of edema in her lower limbs, photosensitivity, oral ulcers, cyanosis, weight loss and fever, with a diagnosis of pyelonephritis. The symptoms persisted and she came to our hospital. We found that she had

<sup>☆</sup> Please cite this article as: Torres Jiménez AR, Solís-Vallejo E, Céspedes-Cruz AI, Zeferino Cruz M, Rojas-Curiel EZ, Sánchez-Jara B. Síndrome de Tjalma (pseudo-pseudo Meigs) como manifestación inicial de lupus eritematoso sistémico de inicio juvenil. Reumatol Clin. 2019;15:e41–e43.

\* Corresponding author.

E-mail address: [dr-poncho@hotmail.com](mailto:dr-poncho@hotmail.com) (A.R. Torres Jiménez).

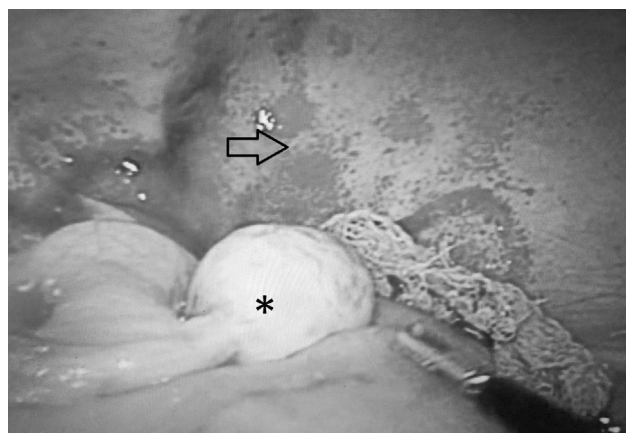


**Fig. 1.** Massive ascites in our patient.

arthritis, ascites, pallor and anemia of chronic disease. Her platelet count was 340,000/ $\mu$ L, the lymphocyte count was 870/ $\mu$ L, creatinine was 1.66 mg/dL, urea was 164 mg/dL, blood urea nitrogen was 76 mg/dL, albumin was 2.14 g/dL, C3 was 53 mg/dL, C4 was 3.9 mg/dL, antinuclear antibodies (homogeneous pattern) 1:160, anti-DNA > 240, urinalysis showed red blood cells in the urine and casts; SLE was diagnosed with a Systemic Lupus Erythematosus Disease Activity Index (SLEDAI) of 26. Treatment was initiated with methylprednisolone pulses (5 doses of 30 mg/kg body weight [bw]/day), and she developed respiratory distress and left pleural effusion. She continued to have fever, anemia, acute kidney injury, thrombocytopenia, hypertension, neuropsychiatric disorders, peripheral blood smear with schistocytes, left diaphragmatic hypomotility according to thoracic ultrasound (US) and pulmonary function tests revealed a severe restrictive pattern, with a diagnosis of shrinking lung syndrome and thrombotic thrombocytopenic purpura (TTP). The treatment was plasma infusion at 30 mL/kg bw/day, subcutaneous cyclophosphamide (1 g/m<sup>2</sup>/month) and rituximab (total dose of 1.5 g, divided into 2 doses at an interval of 14 days). Despite treatment, ascites persisted and the patient underwent paracentesis. She had acute pulmonary edema, with passage to phase III of ventilation, and cardiorespiratory arrest and acute kidney injury managed with hemodialysis. She was extubated a week later; acute kidney injury, ascites and TTP persisted. She had 5 sessions of plasmapheresis, and TTP remitted. Given refractory ascites (Fig. 1), persistent pleural effusion and US showing an increase in volume of the structures that support left ovary, we suspected Meigs' syndrome, with a result of CA-125 elevated by 59 IU/mL. Ovarian tumor was ruled out by laparotomy (Fig. 2), and we concluded that the diagnosis was Tjalma syndrome. To treat the refractory ascites, we decided to utilize an intraperitoneal steroid (dexamethasone with 2 monthly doses of 12 mg). Hemodialysis was discontinued 3 months later. The patient completed the treatment with 12 monthly cycles of cyclophosphamide and gradual tapering of the steroid. She is currently taking 2 g/day of mycophenolate mofetil and 5 mg/day of prednisone. In the latest determination of CA-125 the level was 23 IU/mL (normal value: 0–35 IU/mL).

## Discussion

Tumor markers are utilized to detect recurrences, for the evaluation of the response to treatment or for diagnosis. CA-125 is a glycoprotein initially described by Bast in 1981. It reacted with epithelial tumor cells of ovarian cancer. Its use as a diagnostic tool is limited, since it is also expressed on the surface of cells derived



**Fig. 2.** Exploratory laparotomy showing left ovary with normal characteristics (\*), and no macroscopic features indicative of tumor, edematous intestinal loops and peritoneum with capillary fragility (arrow).

from coelomic epithelium (Fallopian tubes, endometrium, endocervix, ovary, pleura, peritoneum and pericardium), lung, breast, prostate and conjunctiva, and the levels of certain cytokines like vascular endothelial growth factor (VEGF) and fibroblast growth factor increase on interacting with mesothelial cells. Their elevation is associated with other conditions, like early pregnancy, ascites, menstruation, nephrotic syndrome, endometriosis, leiomyomas, congestive heart failure, cirrhosis, SLE, rheumatoid arthritis and tuberculosis.<sup>2,5–7</sup>

Elevated CA-125 levels in SLE are probably secondary to the activation of mesothelial cells. Cytokines like interleukin (IL) 1 and interferon (IFN)  $\gamma$  increase the expression of CA-125 in human peritoneal mesothelial cells.<sup>2,4</sup> The VEGF levels are elevated in patients with nephrotic syndrome, a fact that may explain the increase in CA-125.<sup>1,8</sup> Table 1 shows the features of reported cases of Tjalma syndrome. Moncayo et al. measured the levels of CA-125 in 37 SLE patients and found elevated levels in patients with active disease.<sup>6</sup> Szekanecz observed CA-125 elevation with disease activity, but there was no renal involvement.<sup>6</sup> This contrasts with the findings of Miret et al.,<sup>6</sup> who evaluated serum CA-125 levels in 59 patients with SLE and their relationship with activity. They found an elevation in 3 of them, 2 with disease activity and 1 with inactive disease, but no correlation with activity, although there was a link to nephrotic syndrome. Yang et al.<sup>6</sup> conducted a study involving 156 SLE patients, and observed an elevation of CA-125 in 48. Compared to patients with a normal CA-125 level, those in which it was elevated were more likely to have serositis (37.5% vs 1.9%);  $P < .001$ , pulmonary involvement (37.5% vs 12%;  $P < .001$ ) and a high SLEDAI score  $P < .007$ . They generated a receiver operating characteristic ROC curve, and determined the area under the curve to assess the strength of CA-125 elevation in the diagnosis of serositis due to SLE. We identified a cutoff value of 38 IU/mL (sensitivity of 85%, specificity of 75%). The determination was repeated in 15 patients when the serositis resolved, and the level was normal in 14 and remained high in 1.<sup>6</sup> Our patient had an SLEDAI score of 26, as well as uncommon and severe complications, that warranted aggressive therapy with cyclophosphamide, rituximab and plasmapheresis. For refractory peritonitis, we utilized an intraperitoneal steroid (dexamethasone at 12 mg monthly in 2 doses), as reported by Yemil Atisha (Mexican Rheumatology Congress, 2015). In our case, we attributed CA-125 elevation to the presence of high disease activity, refractory serositis, congestive heart failure and nephrotic syndrome.

**Table 1**  
Characteristics of Tjalma Syndrome Patients.

Reference	Age (years)	Ascites/pleural effusion	Manifestations of lupus	CA-125	Ovarian tumor	Treatment
Bes et al. <sup>1</sup>	42	+/+	Thrombocytopenia ANA + anti-DNA + decreased C3 and C4	91 IU/mL	No	3 pulses of methylprednisolone 1/mg/kg bw/day Monthly cyclophosphamide pulses for 6 months Oral steroids Hydroxychloroquine
Bes y Soy <sup>8</sup>	47	+/+	Arthritis Pericardial effusion Leukopenia, lymphopenia ANA + anti-DNA + complement consumption	233 IU/mL	No	Steroid pulses Hydroxychloroquine
Lee et al. <sup>2</sup>	29	+/+	Pancytopenia Cutaneous ANA + anti-DNA + complement consumption	345 IU/mL	No	Steroid pulses Hydroxychloroquine
Lee et al. <sup>2</sup>	54	+/+	Pericardial effusion ANA+, anti-DNA + nephritis Arthritis Thrombocytopenia Complement consumption	344 IU/mL	No	Methylprednisolone Cyclophosphamide
Ural et al. <sup>5</sup>	38	+/+	Cutaneous Anti-DNA + anti-Ro + C3 consumption	1229 IU/mL	No	Steroids Hydroxychloroquine
Tjalma <sup>3</sup>	38	+/+	Thrombocytopenia Sjögren's syndrome Antiphospholipid antibodies++ CVD	887 IU/mL	No	Steroids Azathioprine
Dalvi et al. <sup>4</sup>	56	+/+	ANA + anti-DNA + leukopenia arthritis Complement consumption Pericardial effusion	70 IU/mL	No	Prednisone 1 mg/kg bw/day Mycophenolate mofetil
Our patient	14	+/+	ANA + anti-DNA + thrombotic thrombocytopenic purpura Shrinking lung syndrome Nephritis Arthritis Complement consumption Pericardial effusion	59 IU/mL	No	Steroid pulses Oral prednisone 1 mg/kg bw/day Cyclophosphamide Rituximab Plasmapheresis Intraperitoneal steroid

ANA, antinuclear antibodies; bw, body weight; CA, cancer antigen; CVD, cerebrovascular disease; DNA, deoxyribonucleic acid.

Tjalma syndrome is a rare association that had not been reported until now in the pediatric age group. Although CA-125 elevation requires ruling out cancer, it is also necessary to assess other causes of the elevation of CA-125 like those mentioned above.

### Ethical Disclosures

**Protection of human and animal subjects.** The authors declare that the procedures followed were in accordance with the regulations of the relevant clinical research ethics committee and with those of the Code of Ethics of the World Medical Association (Declaration of Helsinki).

**Confidentiality of data.** The authors declare that they have followed the protocols of their work center on the publication of patient data.

**Right to privacy and informed consent.** The authors have obtained the written informed consent of the patients or subjects mentioned in the article. The corresponding author is in possession of this document.

### Conflicts of Interest

The authors declare they have no conflicts of interest.

### References

- Bes C, Dağlı Ü, Memedoğlu P, Soy M. A rare form of SLE: pseudo-pseudo Meigs syndrome and hydrocephalus. *Rheumatol Int.* 2013;33:2175–6.
- Lee SY, Lee SW, Chung WT. Severe inflammation may be caused by hyperferritinemia of pseudo-pseudo Meigs' syndrome in lupus patients: two cases reports and a literature review. *Clin Rheumatol.* 2013;32:1823–6.
- Tjalma WA. Ascites, pleural effusion, and CA 125 elevation in an SLE patient, either a Tjalma syndrome or, due to the migrated Filshie clips, a pseudo-Meigs syndrome. *Gynecol Oncol.* 2005;97:288–91.
- Dalvi SR, Yildirim R, Santoriello D, Belmont HM. Pseudo-pseudo Meigs' syndrome in a patient with systemic lupus erythematosus. *Lupus.* 2012;21:1463–6.
- Ural UM, Kiliç A, Güngör T, Ozdal B, Mollamahmutoğlu L. Tjalma's or pseudo-pseudo Meigs syndrome: a case report. *Clin Exp Dermatol.* 2008;33:363–4.
- Yang Z, Liang Y, Li C, Zhong R. Serum CA125 elevation is independently associated with serositis in SLE patients. *Clin Exp Rheumatol.* 2012;30:93–8.
- Basaran A, Zafer Tuncer S. Ascites is the primary cause of cancer antigen-125 (CA-125) elevation in systemic lupus erythematosus (SLE) patients with nephrotic syndrome. *Med Hypotheses.* 2007;68:197–201.
- Bes C, Soy M. Pseudo-pseudo Meigs syndrome developed under the leflunomide therapy. *Rheumatol Int.* 2011;31:521–3.